

# Complications In Intramedullary Nailing Of The Humerus; A Beginner's Review

N Muzaffar, N Bashir, M Moosa, S Singh, S Rawa, N Ahmad, A Ahmad, A Ahmad, I Latoo, A Hafeez

## Citation

N Muzaffar, N Bashir, M Moosa, S Singh, S Rawa, N Ahmad, A Ahmad, A Ahmad, I Latoo, A Hafeez. *Complications In Intramedullary Nailing Of The Humerus; A Beginner's Review*. The Internet Journal of Orthopedic Surgery. 2009 Volume 18 Number 1.

## Abstract

**Aim:** The aim of this study was to investigate the complications of humeral locked nailing when done for the first time in a third world setting. **Methods:** Between 2005 and 2007, 25 humeral shaft fractures treated with antegrade humeral locked nails were followed up for an average of 25.4 months. There were 20 men and 5 women, with an average age of 34.4 years. **Results:** In total, 13 patients had significant complications. In the intraoperative period, one patient had operative comminution, two had failed closed reduction, two had failed distal locking and in one, protrusion of the proximal nail end occurred. Fracture gap due to distraction at the fracture site was associated with subsequent nonunion in one patient. Removal of the protruded screws was performed in two cases. Other complications included shoulder stiffness in four cases. One patient had a varus malalignment of 15 degrees. No elbow impairment, malunion or post nailing radial nerve palsy was observed in any patient. **Conclusion :** Many complications of humeral locked nailing can be prevented by improving the implant design or surgical techniques. In this study, the complications of locked nailing were examined in 25 humeral fractures. The causes of these complications and the means to prevent or treat them were investigated.

## INTRODUCTION

Unreamed interlocking intramedullary nailing represents a new technical approach to the surgical management of humeral shaft fractures. Although dynamic compression plating has traditionally been considered the "gold standard" in humeral surgery, intramedullary fixation has certain advantages like being closer to the normal mechanical axis of the bone and acting as a load sharing device. Bending forces and consequent fatigue failure are less. Since the fracture is not exposed directly and soft tissue dissection is much less, the fixation is more biological and with less stress shielding and chances of iatrogenic nerve injury are also reduced. However, the procedure is not without its pitfalls. Failed closed reduction, failed locking, iatrogenic fractures and nerve injuries in the intraoperative period and adhesive capsulitis, non union, nail protrusion and impingement have been reported. These complications are amplified when intramedullary nailing is attempted for the first time in an institution. The endeavour of this work is to present the complications encountered in this procedure during the initial period of the learning curve, the possible causes and remedial measures that can be employed to minimise the

morbidity.

## MATERIALS AND METHODS

This study was conducted prospectively between 2002 and 2005 in 25 humeral shaft fractures treated with antegrade humeral locked nails followed up for an average of 25.4 months. There were 20 males and 5 females with an average age of 34.4 years. No open fractures or pathological fractures or polytrauma cases were taken. The modified Gross-Kempf solid nail was used with an unreamed technique. The entry portal was made just medial to the tip of the greater tuberosity posterior to the bicipital groove. Closed reduction was performed and guide wire passed into the distal fragment followed by removal of the wire and nail insertion. Passive ROM exercises were started on the 3rd postoperative day. The patients were followed up every 4 weeks for 6 months.

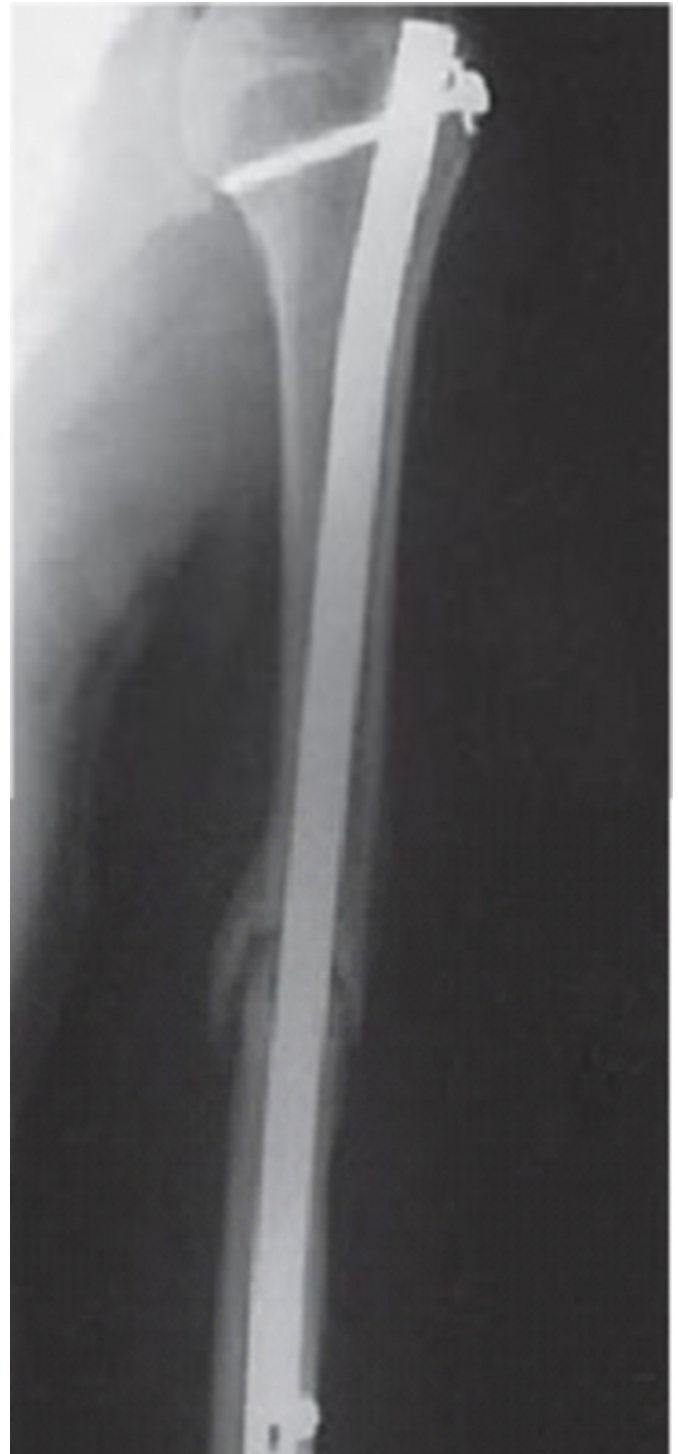## RESULTS

We had 14 patients (56 %) with significant complications. In the intraoperative period, one patient had iatrogenic comminution of the fracture, two had failed closed reduction

which necessitated open reduction of the fracture, two had failed distal locking in whom an above elbow POP back slab was applied for 6 weeks and in one, protrusion of the proximal nail end occurred which was managed by nail removal at 12 weeks once the fracture united. Fracture gap due to distraction at the fracture site occurred in one case due to improper assessment of nail length (too long) and was associated with subsequent nonunion in the patient which was managed by autogenous bone grafting. Removal of the protruding screws was performed in two cases. Other long term complications included shoulder stiffness in four cases, impingement in one and one patient had a varus malalignment of 15 degrees. No elbow impairment, malunion or post nailing radial nerve palsy was observed in any patient. The average duration of the surgery was 82.6 minutes with two cases extending to 110-150 min.

**Figure 1**

Fig 1: Non union of humerus after intramedullary nailing at 6 months.



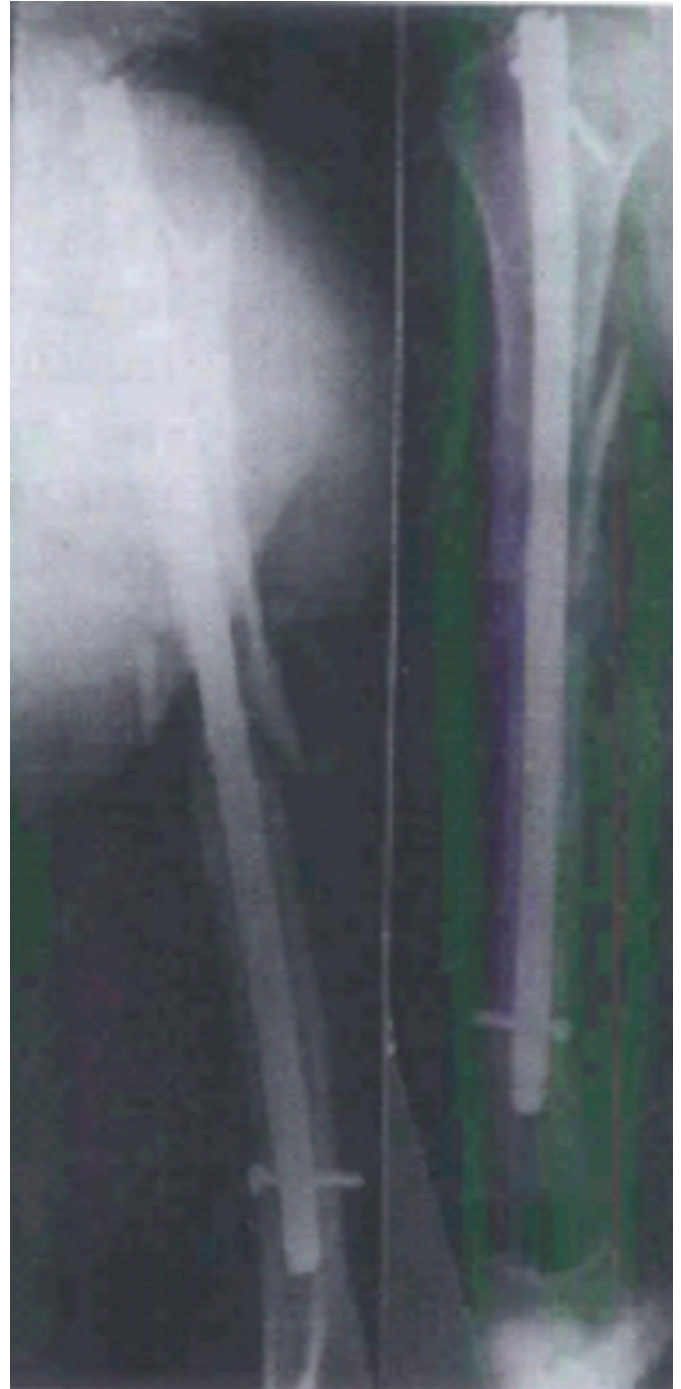
**Figure 2**

Fig 2: Intra-operative fracture comminution.



**Figure 3**

Fig 3: Proximal nail protrusion.



## **DISCUSSION**

Conservative management of humeral shaft fractures, although giving high rates of union[1,2] is losing popularity due to the need for prolonged immobilization to achieve solid union followed by vigorous rehabilitation to restore joint function and muscle strength. Plate osteosynthesis, considered as the “gold standard” by its advocates [3,4,5], has yielded good results but at the cost of infection, nerve

palsies and need for additional surgeries to salvage failures or for removal of the implant. Interlocking intramedullary nailing has yielded varying and often contrasting results [5,6] with infection rates from 1-7%, non unions from 0-9% and radial nerve palsy from 3-14%. Shoulder stiffness and impingement are also observed in many patients.

In our series, we encountered significant problems while doing this procedure for the first time in this institute. Iatrogenic comminution of the fracture site occurred in one case (4%) because the solid Gross-Kempf nail was of a larger diameter than the unreamed medullary cavity and the brute force used to push the nail resulted in its abutment against the cortex at the fracture site which subsequently fractured. We henceforth kept all diameter nails available and did not hesitate to employ a smaller nail if the passage was difficult. Failed reduction in two cases (8%) was encountered initially but with improvement in the learning curve, that was obviated. Distal locking in two cases (8%) could not be done since multiple attempts at locking ended in multiple holes, none of which were properly located and to avoid iatrogenic fracture at the site, the locking was abandoned. Protruding proximal nail causing impingement was observed in one case (4%) due to improper countersinking of the nail end into the humeral head. This case was managed by early nail removal at 12 weeks. In two cases (8%), prominent protruding screws due to backout following vigorous physiotherapy were removed at 8 weeks with no adverse effects. One patient (4%) had a varus malalignment of 15 ° due to medial comminution. We did not employ the Poller blocking screw technique at the time because we were unaware of it. Shoulder stiffness was the commonest complication with 4 patients (16%) suffering from adhesive capsulitis which responded to physiotherapy and analgesics. We believe that the entry portal can be modified to the superolateral surface of the greater tuberosity below the supraspinatus insertion which minimises the risk of rotator cuff injury and adhesive capsulitis.

We achieved union rates of 96% and ASES functional result shoulder score of >45 in 68% cases. All patients had full ROM at the elbow and >80% had full ROM at the shoulder on final follow up. There were no cases of nerve injury, infection or malunion. The exclusion of open, pathological and old fractures and polytrauma patients maybe a causative factor for this. However, the presence of significant complications in > 50% of the cases does make a point to ponder.

When we look at the union rates, the reported recovery of

shoulder function after antegrade nailing varies. In studies using Russell-Taylor nails, Ikpeme reported 22 (88%) patients with excellent or satisfactory recovery of shoulder function according to their Neer score [7]. Postoperative shoulder pain was caused mostly by proximal locking screws. Crates and Whittle reported 66 of 73 (90%) patients had full recovery of shoulder function [8]. Three patients had impingement: two caused by the proximal locking screw and one by a prominent nail. In contrast, Hems and Bhullar reported only 11 of 15 (73.3%) patients had excellent or satisfactory Neer scores [9]. They attributed these less than satisfactory results to intra-operative rotator cuff injury. However, their follow-up time (range, 1-42 months) was insufficient in terms of recovery of shoulder function. In a series of 30 acute humeral fractures treated with antegrade Russell-Taylor nails, Ikpeme reported that six (20%) patients had shoulder pain and decreased shoulder abduction because of impingement of the proximal locking screws [7]. Removal of the proximal screws in five of these patients resulted in complete resolution of symptoms. Two other patients had proximal nail migration because of proximal interlocking through an area of comminution.

We believe that humeral locked intramedullary nailing should be initiated after significant experience on the femoral and tibial fractures has been achieved. Also, the importance of proper preoperative planning and using the proper sized implant cannot be over emphasised. Shoulder stiffness seems inimical to antegrade nailing and this maybe obviated by accurate portal entry, countersinking the nail tip in the humeral head and wad capping the proximal hollow of the nail and ultimately, using the retrograde technique which however is also associated with fracture propagation at the distal hole and axillary nerve damage with proximal locking employing the retrograde technique.

### References

1. Mast JW, Spiegel PG, Harvey JP, Harrison C. Fractures of the humeral shaft. Clin. Orthop. 1975; 12:254-62.
2. Sarmiento A, Kinman P, Galvin E. Functional bracing of fractures of the shaft of the humerus. JBJS (Am) 1977; 59-A:596-601.
3. Bell MJ, Beauchamp CG, Kellam JK, McMurty RY. The results of plating humeral shaft fractures in patients with multiple injuries; the Sunnybrook experience. JBJS (Br) 1985; 67-B: 293-6.
4. Dabezies EJ, Banta CJ, Murphy CP, d'Ambrosia Rd. Plate fixation of the humeral shaft for acute injuries with and without radial nerve injuries. J Orthop Trauma. 1992; 6:10-3
5. RG McCormack, D. Brien, RE Buckley, MD McKee, J Powell, EH Schemitsch. Fixation of fractures of the shaft of the humerus by dynamic compression plate or intramedullary nail. A prospective randomised trial. JBJS (Br) 2000; 82-B: 336-9

6. Crolla RMPH, de Vries LS, Clevers GJ. Locked intramedullary nailing of humeral fractures. *Injury* 1993; 24:403-55

7. Ikpeme JO. Intramedullary interlocking nailing for humeral fractures: Experiences with the Russell-Taylor humeral nail. *Injury* 1994; 25:447-55

8. Crates J, Whittle AP. Antegrade interlocking nailing of acute humeral shaft fractures. *Clin Orthop Relat Res* 1998; 350:40-50.

9. Hems TE, Bhullar TP. Interlocking nailing of humeral shaft fractures: The Oxford experience 1991 to 1994. *Injury* 1996; 27:485-9

**Author Information**

**Nasir Muzaffar**

Registrar Orthopaedics, Department of Orthopaedics, Hospital for Bone and Joint Surgery

**Naveed Bashir**

Registrar Orthopaedics, Department of Orthopaedics, Hospital for Bone and Joint Surgery

**Mohammad Moosa**

Registrar Orthopaedics, Department of Orthopaedics, Hospital for Bone and Joint Surgery

**Sukhjeet Singh**

Registrar Orthopaedics, Department of Orthopaedics, Hospital for Bone and Joint Surgery

**Shabir Rawa**

Registrar Orthopaedics, Department of Orthopaedics, Hospital for Bone and Joint Surgery

**Nawaz Ahmad**

Postgraduate Scholar Orthopaedics, Department of Orthopaedics, Hospital for Bone and Joint Surgery

**Azad Ahmad**

Postgraduate Scholar Orthopaedics, Department of Orthopaedics, Hospital for Bone and Joint Surgery

**Aijaz Ahmad**

Postgraduate Scholar Orthopaedics, Department of Orthopaedics, Hospital for Bone and Joint Surgery

**Irfan Latoo**

Postgraduate Scholar Orthopaedics, Department of Orthopaedics, Hospital for Bone and Joint Surgery

**Arifa Hafeez**

Department of Orthopaedics, Hospital for Bone and Joint Surgery