

A Rare Case Of Subcutaneous Hydatid Cyst Of The Neck

C Amine, M safaa, A Hassan, O abdelatif, E Nouredine

Citation

C Amine, M safaa, A Hassan, O abdelatif, E Nouredine. *A Rare Case Of Subcutaneous Hydatid Cyst Of The Neck*. The Internet Journal of Otorhinolaryngology. 2008 Volume 11 Number 1.

Abstract

Hydatid cyst in the head and neck is very rare even in countries where echinococcus infestation is endemic. In this paper, we report an unusual case of a patient who had a solitary hydatid cyst in the subcutaneous anterior region of the neck. The clinical presentation was non-specific. The diagnosis was suspected by peroperative findings, and confirmed by histopathology. Characteristics of this rare disease, its diagnostic difficulties, and treatment are discussed.

INTRODUCTION

Hydatid disease is an infestation caused by the parasite *Echinococcus granulosus*, and is still common in the countries of the temperate zones, including the Mediterranean countries and the Middle East (1). The liver is the most frequently involved organ (75%), followed by the lung (15%) (2).

The neck localisation is extremely rare what makes this case of an isolated hydatid cyst of the neck without any pulmonary or hepatic involvement interesting to be reported.

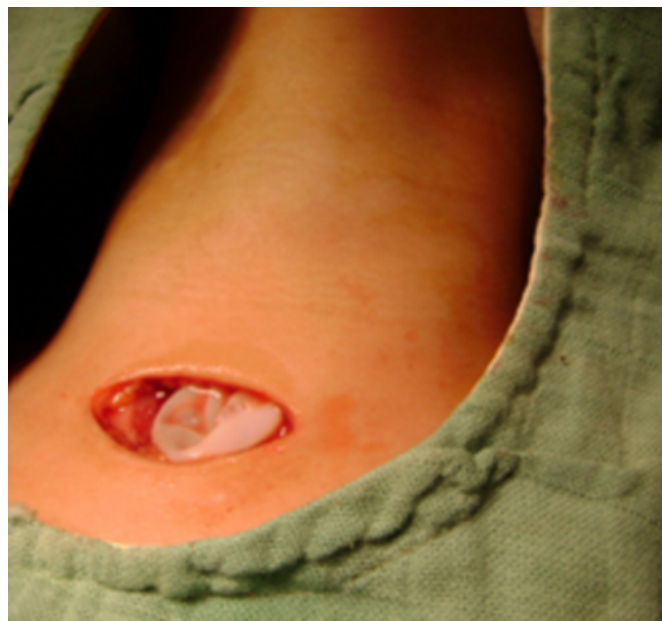
CASE REPORT

A 16-year-old girl presented with a cystic mass in the middle anterior triangle of the neck. On physical examination, a 3 cm x 3 cm mass was palpated 2 cm exactly superior to the sternum; it was cystic, fluctuant, mobile, and painless. The overlying skin was normal. Ultrasound showed a rounded cystic mass well limited in the inferoanterior triangle of the neck, measuring 38 mm. The preoperative examinations (chest radiograph, complete blood count, urine analysis, and blood biochemistry) revealed no abnormality.

Upon surgical exploration, the mass was found to be attached to the subcutaneous tissue but was not associated with any major structure in the neck (Fig 1).

Figure 1

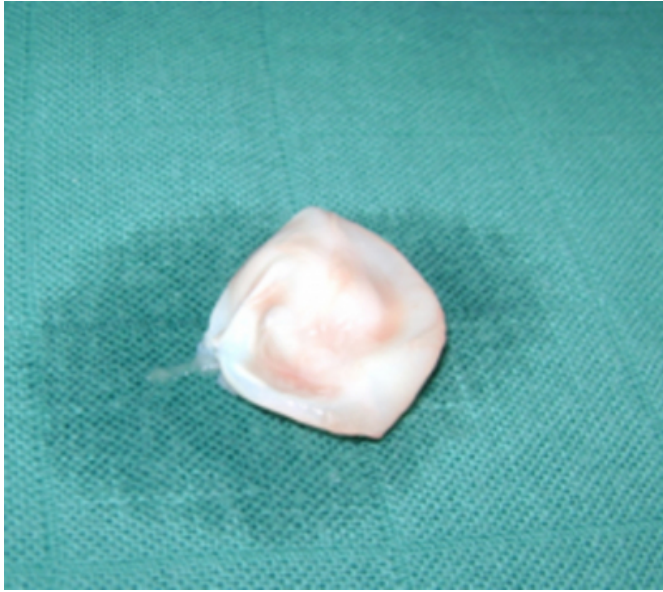
Fig 1: Per-operative view of the hydatid cyst



The macroscopic appearance suggested a hydatid cyst; perforation was avoided by means of meticulous dissection (Fig.2).

Figure 2

Fig 2: Hydatid cyst after its surgical debulking.



Because the preoperative diagnosis had not been hydatid disease, investigations for other organ involvement especially liver and lungs was performed postoperatively and no other focus was found. Histopathologic examination of the specimen revealed a hydatid cyst. The patient has been followed for 2 years and no recurrence of hydatidosis has been detected.

DISCUSSION

Hydatid disease is a parasitic infestation caused by the *Ecchinococcus granulosus*. Although most cysts are caught in the hepatic sinusoids, which are carried out by the portal vein, making the liver the most frequently involved organ, a few ova may pass through the liver, heart, and pulmonary capillaries and reach the general circulation to lodge in such sites for example orbit, bones, and other internal organs(3).

In a large series from Greece, the frequency of extrahepatic and extrapulmonary hydatidosis was 9% (4). Hydatid cysts located in the head and neck region are extremely rare, even in geographic areas in which echinococcal infestation is frequent (5). In a different series, the frequency of subcutaneous tissue involvement was approximately 2% (6). The particularity of our case is the absence of disease in the liver and lungs. It is strongly possible that systemic dissemination via the lymphatic route accounts for cases with solitary cysts in uncommon sites (7).

The clinical course depends on the site of involvement, the size, and pressure caused by the enlarged cysts (8).

The ultrasonographic examination can show the membranes, septations, and daughter cysts within the cystic cavity (7). CT and MRI have recently become the most sensitive of diagnostic modalities. The CT examination shows detachment of the laminated membrane as linear areas of increased attenuation within the cyst, known as “water lilly sign”. CT scanning provides also a precise assessment of the relation between the cysts and osseous structures, the extension into the soft tissues, and the calcifications of the peripheral rim of the cyst (9). The MRI detects the anatomic location of the cyst and involvement of the neural structures more precisely than the other methods but seems to be less helpful than CT for showing osteolytic changes (10).

The serologic tests including direct, hemmagglutination, latex agglutination, immunoelectrophoresis, skin tests and enzyme-linked immunosorbent assay are widely used to confirm diagnosis, although they are associated with false-negative and false-positive results (11).

Treatment options for the uncomplicated hydatid cyst are various and include needle aspiration under ultrasound guidance, laparoscopic approach, direct surgical intervention like our case, or medical treatment with the use of Albendazole.

CONCLUSION

The most important issue in cases with cysts in uncommon sites is whether hydatidosis will develop in the primary sites. These patients should be followed, paying close attention to this possibility.

References

1. Akhan O, Dincer A, Gokoz A, et al. Percutaneous treatment of abdominal hydatid cysts with hypertonic saline and alcohol: an experimental study in sheep. *Invest Radiol* 1993;28:121-7.
2. Hilmani S, Bertal A, Sami A, Ouboukhlik A, El-Kamar A, El-Azhari A. Primary hydatid cyst of the neck. *J Neuroradiol*. 2008 ; 35(3):188-9.
3. Eroglu A, Atabekoglu S, Kocaoglu H. Primary hydatid cyst of the neck. *Eur Arch Otorhinolaryngol* 1999;256:202-4.
4. Prousalidis J, Tzardinoglou K, Sgouradis L, Katsohis C, Aletras H, Uncommon sites of hydatid disease. 1998 *World J Surg* 22: 17–22.
5. Tekin M, Osma U, Yaldiz M, et al. Preauricular hydatid cyst: an unusual location for echinococcosis. *Eur Arch Otorhinolaryngol* 2004;261:87-9.
6. Chevalier X, Rhamouni A, Bretagne S, Martigny J, Larget-Piet B, 1994. Hydatid cyst of the subcutaneous tissue without other involvement: MR imaging features. *AJR* 163: 645–6.
7. Erdogan E.O, Sozuer M. *Am. J. Trop. Med. Hyg.*, 2000. 62(5): 583–4.

8. Gangopadhyay K, Abuzeid MO, Kfoury H. Hydatid cyst of the pterygopalatine-infratemporal fossa J Laryngol Otol 1996;110:978-980.
9. Tsitouridis I, Dimitriadis AS CT and MRI in vertebral hydatid disease. Eur Radiol 1997;7:1207-10.
10. EL Kohen A, Benjelloun A, El Quessar, A, et al. Multiple hydatid cysts of the neck, the nasopharynx and the skull base revealing cervical vertebral hydatid disease. Int J Pediatr Otorhinolaryngol 2003; 67:655-62.
11. Senyuz OF, Celayir AC, Kilic N, et al. Hydatid disease of the liver in childhood. Pediatr Surg Int 1999;15:217-20.

Author Information

Cherkaoui Amine

Senior resident, Department of Otolaryngology-Head and Neck Surgery, Hassan II, University Hospital

Mekki safaa

Resident, Department of Otolaryngology-Head and Neck Surgery, Hassan II, University Hospital

Abassi Hassan

Resident, Department of Otolaryngology-Head and Neck Surgery, Hassan II, University Hospital

Oudidi abdelatif

Professor, Department of Otolaryngology-Head and Neck Surgery, Hassan II, University Hospital

El alami Nouredine

Professor, Department of Otolaryngology-Head and Neck Surgery, Hassan II, University Hospital