

# Endoscopic removal of Naso- Oropharyngeal Rhinosporidiosis: A Report

A Nair, B Manjula, A Balasubramanya, R Nayar

## Citation

A Nair, B Manjula, A Balasubramanya, R Nayar. *Endoscopic removal of Naso- Oropharyngeal Rhinosporidiosis: A Report*. The Internet Journal of Otorhinolaryngology. 2008 Volume 9 Number 2.

## Abstract

Rhinosporidiosis is a chronic non contagious sporadic disease caused by the fungus *Rhinosporidium seeberi*, which predominantly affects the mucus membranes of the nose and nasopharynx. It is a difficult granulomatous disease of the nose and is notorious for its high rate of recurrence and vascularity. Most cases of rhinosporidiosis are limited to the nose, oropharynx and upper airway but unusual presentations have been reported. The diagnosis is established by histopathology and the treatment involves excision followed by anti- mycotic and anti protozoal drugs. We present a case of nasal rhinosporidiosis with oropharyngeal extension with unilateral tonsillar involvement.

## INTRODUCTION

Rhinosporidiosis is a chronic infection commonly affecting the mucous membrane of nose and nasopharynx. The first reference to this condition was made by Malbran in 1812 from Argentina. Although it is endemic in India and Srilanka it occurs sporadically in other parts of the world. A review of literature showed that there are cases reported from United States, South America, South Africa and in Europe <sup>1</sup>. In this age of wide spread travel this emerging infective disease has to be kept in mind. The nature of the organism is controversial; it is an infective, but not an infectious, contagious or toxic disease <sup>2</sup>. Several anti protozoal and anti fungal drugs has been tried in the past with conflicting results. At present surgical excision, cold steel with cautery or laser, followed by a course of oral Dapsone seems to yield convincing results <sup>3</sup>. We present a case of Naso – oropharyngeal rhinosporidiosis managed in our institution.

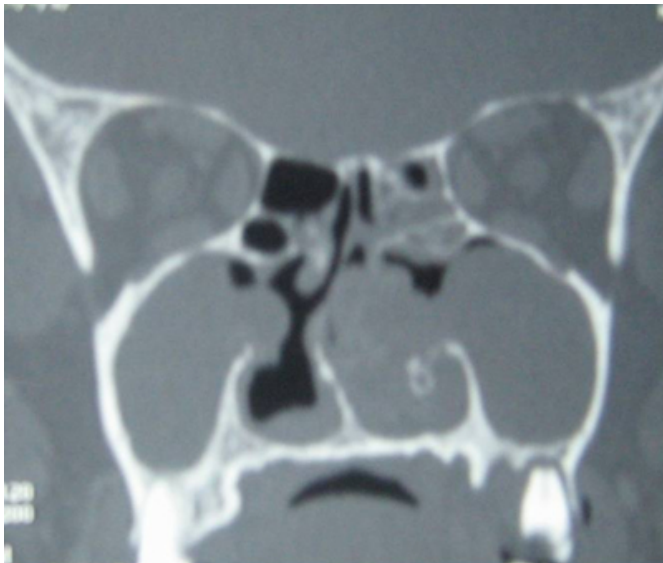## CASE REPORT

A 60 year old male patient with presented with history of nasal obstruction, epistaxis from the left nasal cavity since 3 years to our outpatient department of ENT & Head and Neck Surgery at St John's Medical College Hospital, Bangalore, a tertiary referral hospital. There was history of left sided nasal obstruction, rhinorrhoea and epistaxis on and off since last 3 years. The patient had undergone surgery for the similar complaints three times in the past and was histopathology proved to be Rhinosporidiosis. Nasal endoscopy showed a polypoidal mass on the left side nasal cavity filling upto the

vestibule and extending into the oropharynx on the left side. A separate mass was seen arising from the tonsil on the left side. CT scan of the para nasal sinus showed mass arising in the nasal cavity extending into the oropharynx. Under endoscopic guidance, bipolar cauterization was done to separate the attachments of the mass and the mass was removed enbloc and delivered per orally without any significant bleeding. The tonsillar mass was removed after cauterizing the base. The nose was packed with merocel which was removed on post op day two. Histopathology confirmed the diagnosis of rhinosporidiosis. No sign of recurrence has been observed with a follow up of one year.

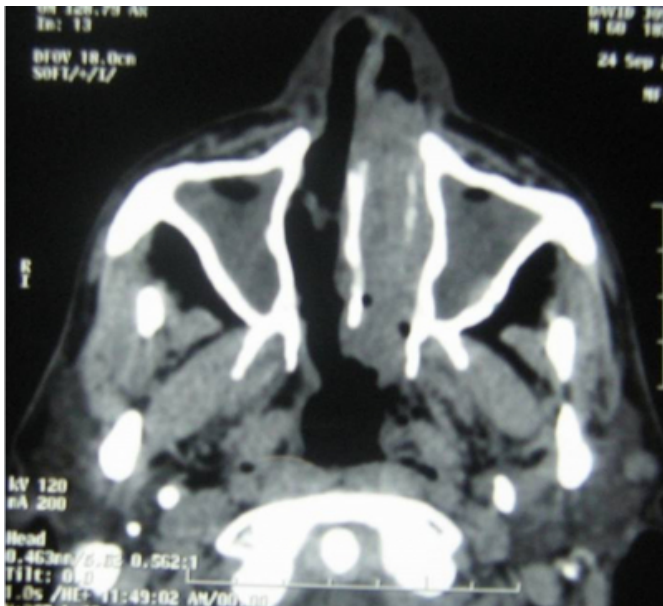
**Figure 1**

Figure 1: CT scan coronal section



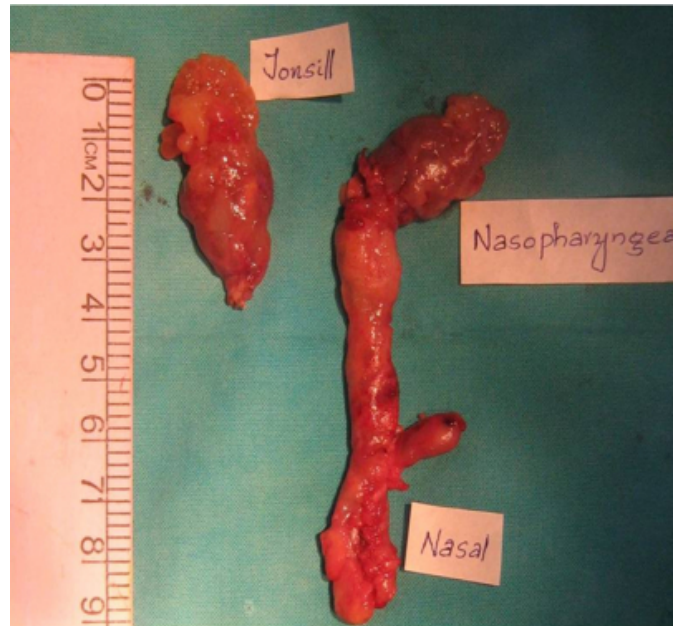
**Figure 2**

Figure 2: CT Scan Axial view



**Figure 3**

Figure 3: Specimen



## DISCUSSION

Rhinosporidiosis is caused by *Rhinosporidium seeberi*. The exact taxonomy of the organism is controversial, *Rhinosporidium* is not a fungus or bacterium, but a peculiar form of aquatic parasite that infects fish and amphibians<sup>34</sup>. Taxonomically, it is now included with fish and amphibian pathogens in a new clade, the Mesomycetozoea. Patients probably get infected by swimming in fresh water; with the parasite gaining access to nasal mucosal tissue. The organism has not been cultured effectively in the laboratory<sup>5\*</sup>.

The usual clinical presentation is with nasal obstruction, epistaxis or sometimes the presentation of the growth itself in the nose or in the oral cavity. However systemic and cutaneous involvement have been reported. Clinically the lesions are soft, hyperplastic and highly vascular and can be either sessile or pedunculated. Men are more affected than women. Histopathology is diagnostic showing multiple budding sporangia embedded in a fibrovascular stroma infiltrated by chronic inflammatory cells<sup>26\*</sup>.

Recurrence is quite characteristic in rhinosporidiosis and many patients, including ours, have had several ENT procedures for removal. Complications of the disease include local secondary bacterial infection and rarely life threatening dissemination. There is no effective medical treatment; the treatment at present consists of surgical excision with cauterization of the base<sup>78\*</sup>. Rhinosporidiosis

still remains an intellectually challenging and difficult disease to treat.

## **CORRESPONDENCE TO**

Dr Arun Nair  
Registrar  
Department of Otolaryngology  
St John's Medical College Hospital  
Kormangala, Bangalore  
INDIA – 560034  
E-mail: drarunnair@gmail.com

## **References**

1. Kutty et al. Some Observations on Rhinosporidiosis. The American Journal of the Medical Sciences 1963; 88: 685-89.
2. Nair K K. Clinical Trial of Diaminodiphenylsulphone (DDS) in nasal and nasopharyngeal Rhinosporidiosis. The Laryngoscope 1979; 89:291-95.
3. Seng K L et al. Rhinosporidiosis: Differential diagnosis of a large nasal mass. Otolaryngology-Head and Neck Surgery 2001; 124(1):121-22.
4. John C. Rhinosporidiosis: another turn of events. An aquatic parasite, not a cyanobacterium. Advances in anatomic pathology 2001; 8(2):117.
5. Sarnath Nanda A. Rhinosporidiosis: what is the cause? Current opinion in Infectious disease 2005; 18(2):113-18.
6. Sukhanand N J, Ramashandra Rao P V. Rhinosporidiosis. Current opinion in Otolaryngology and Head and Neck Surgery 1998; 6:182-85.
7. Ghosh A et al .Rhinosporidiosis-unusual presentations. Indian J.Otolaryngol.Head Neck Surg 2008; 60:159-62.
8. Richard Wong B S, Marshall Strome. Infectious granulomatous diseases of the head and neck. Current Opinion in Otolaryngology & Head and Neck Surgery 1994; 2:281-90.

**Author Information**

**Arun B. Nair, DLO**

Registrar, Department of Otolaryngology and Head and Neck Surgery, St. Johns Medical College and Hospital

**B.V. Manjula, DLO,DNB**

Senior Resident, Department of Otolaryngology and Head and Neck Surgery, St. Johns Medical College and Hospital

**AM Balasubramanya, MS**

Professor, Department of Otolaryngology and Head and Neck Surgery, St. Johns Medical College and Hospital

**Ravi C. Nayar, MS, DNB**

Professor and Head of Department, Department of Otolaryngology and Head and Neck Surgery, St. Johns Medical College and Hospital