

Nasopharyngeal foreign body: A rare entity with unique symptoms of AOM

Rajesh, Pallavi, R Singh, P Bakshi

Citation

Rajesh, Pallavi, R Singh, P Bakshi. *Nasopharyngeal foreign body: A rare entity with unique symptoms of AOM*. The Internet Journal of Otorhinolaryngology. 2006 Volume 6 Number 2.

Abstract

As an otolaryngologist, one may face challenges in diagnosis and removal of foreign bodies from the airway. At times, there are anxious moments and pleasant surprises by relieving the patient of its symptoms and avoiding disastrous outcomes. A metallic foreign body after being inhaled and ultimately being lodged in the nasopharynx is a rare entity. We report a case of nasopharyngeal foreign body with presenting symptoms of acute otitis media and change in voice in a 4-years male child. The foreign body was diagnosed by flexible nasopharyngoscope and documented by X-ray skull lateral view including nasopharynx and the same was removed under general anaesthesia while keeping the child in Rose's position.

INTRODUCTION

Lodgment of foreign body in the nasopharynx is a rare entity after being inhaled. The symptoms and signs depend almost upon the size, nature and location of the foreign body in the airway. In one of the studies, 2000 patients with laryngotracheal foreign bodies were documented out of which 534 patients were seen within a period of 15 years. Only 2-4% of the inhaled laryngotracheal foreign bodies are coughed out. The majority of inhaled foreign bodies pass either through the glottis into the trachea or the oesophagus.^{2,3} This indicates rarity of impaction or lodged foreign body in the nasopharynx. Inhaled foreign bodies removed after a long period, asymptotically, has also been reported.^{4, 5} Eustachian tube blockage is one of the causes of AOM but on reviewing the english literature no case of AOM secondary to foreign body nasopharynx has been reported.

CASE REPORT

A 4 year old male child was reported to us from paediatrics OPD with two days H/O of pain left ear, change in voice and difficulty in swallowing. The air entry was equal in both the lungs without any additional breath sounds, which was supported by a normal x-ray chest P A view. There was a past history of an episode of difficulty in breathing, unable to cry and a bout of cough while playing with toys 7 days back. The parents vigorously pounded on the back of the child after which the child became comfortable. On ENT examination oral cavity was normal with mild restricted

moments of the soft palate on the left side with post nasal mucopurulent discharge. Ears examination showed normal anterior and post aural spaces, pinna and external auditory canals on both sides. On pneumatic otoscopic examination the right tympanic membrane was normal. The left tympanic membrane was retracted with loss of cone of light reflex and thin leash of blood vessels were seen parallel to the handle of malleus and along the periphery of the drum. The mobility of the left tympanic membrane was restricted on siegalization. On anterior rhinoscopy, there was mucopurulent discharge in both the nostrils. The nasal cavities were sprayed with 10% xylocaine spray and after waiting for 5 minutes the suction was done with disposable plastic non-traumatic 10 FG catheter to clear the discharge in the nostrils. On repeated anterior rhinoscopy nothing abnormal detected in both the nostrils. The child was mummified by wrapping him in a sheet of cloth below the shoulders including both hands by the side of the body. A 3.4mm Olympus flexible nasopharyngoscope (Fig.1) was introduced along the floor of the nasal cavity and with firmly holding the head. A shining metallic foreign body was visualized at the posterior chonae which was not disturbed with the apprehension of dislodging it into the larynx. We planned to remove the foreign body under a controlled situation with a secure lower airway. An X-ray skull lateral view including nasopharynx was taken for documentation (Fig.2) and at the same time the anaesthetist was informed. The child was shifted to operation theater with the precaution to keep the head in dependent position to avoid

accidental dislodgement of foreign body in the larynx.

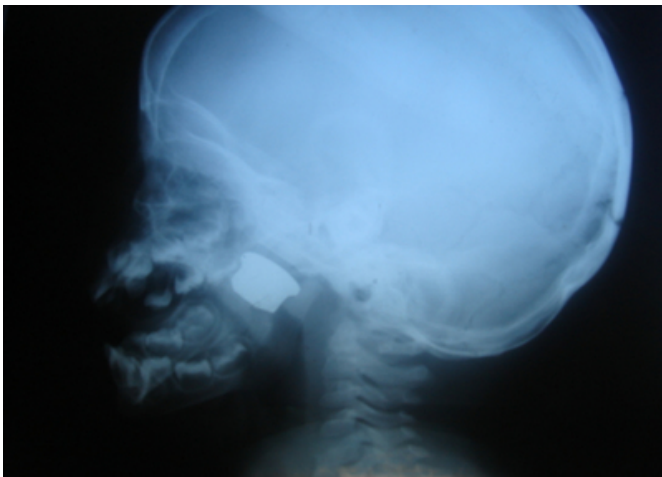
Figure 1

Figure 1: Flexible Naso-pharyngoscope 3.4mm

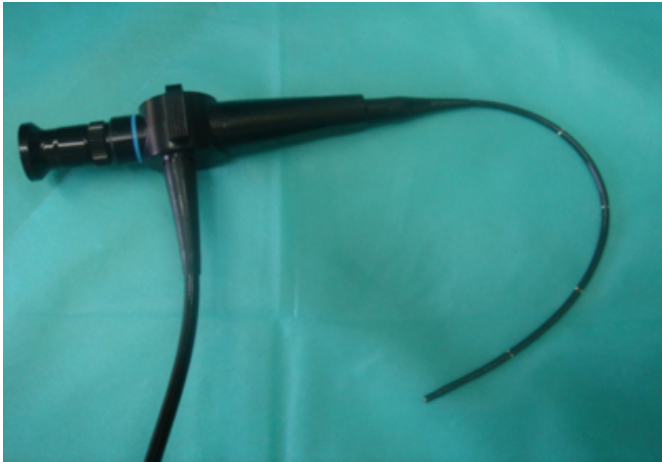

Figure 2

Figure 2: X-ray showing foreign body nasopharynx




PROCEDURE

The anaesthetist planned general anaesthesia with oral intubation. The tracheostomy set was kept ready. After induction, the patient was placed in Rose's position by keeping the child in supine position with head extended by placing a sand bag under the shoulders. The head was supported and stabilized by a rubber ring. An appropriate size Boyles –Davis mouth gag was introduced with the tongue blade in the centre and mouth opened. The gag was stabilized in position by Draffin's bi-pods stand. A saline soaked half inch rolled ribbon gauge was placed around the endotracheal tube in the oropharynx. After lubricating the anterior end a red catheter 16 F G with KY Jelly was introduced through the right nostril till the same seen in the oropharynx and was pulled out of the oral cavity to the

outside by a straight artery forceps. Then both the outer and inner ends were stretched upwards to displace the soft palate posterior superiorly. By doing so the nasopharynx was exposed and the part of the foreign body (Fig.3) was visualized which was grasped with the tonsil holding forceps and was taken out. There was no bleeding encountered. The catheter and the throat pack were removed. After the recovery from anaesthesia the child was sent to the post anaesthesia care unit. Injection Ampicillin 250 mg after test dose was started and I V six hourly and when the child became fully conscious syrup Actifed® [triprolidine hydrochloride 1.25mg and pseudoephedrine hydrochloride 30 mg per 5ml] TDS and Otrivin® [pseudoephedrine 0.25%] nasal drops four drops each nostril TDS were started. The postoperative period was uneventful. The general condition of patient improved. The patient was discharged after two days on syrup Amoxicillin, syrup Actifed and Otrivin nasal drops and after 10 days of repeated follow up the child was perfectly fine with no more ear pain, voice change or difficulty in swallowing.

Figure 3

Figure 3: Metallic foreign body



DISCUSSION

The problem of foreign bodies in the air passages has always given some anxious moment due to its nature, size and locations. The objective of this case report is to identify the site of lodged foreign body after inhalation. A careful history of a sudden episode of difficulty in breathing, unable to cry and a bout of cough is very significant. Symptoms of pain ear and change in voice with difficulty in swallowing and clinical signs are important. A supportive nasopharyngoscopy should be part of the investigation as the suspected nasopharyngeal foreign body may not be radio opaque. In addition to x-ray chest, neck with inclusion of x-ray skull lateral view including nasopharynx is important

radiological investigation.

CONCLUSION

Any thing in the vicinity of the child can be a potential object to be explored and inhaled into the air passage. Although foreign body nasopharynx is a rare entity but subjecting the patient for flexible nasopharyngoscopy and an additional x-ray skull including nasopharynx should be mandatory in all cases of inhaled foreign bodies to avoid disaster if it is dislodged from nasopharynx and falls into the larynx giving rise to sudden death.

CORRESPONDENCE TO

Dr Rajesh Associate Professor Himalayan Institute of

Medical Sciences, Jollygrant, Dehradun, Uttranchal India E mail - drrajeshent@rediffmail.com

References

1. Holinger, P.H. and Holinger, L.D. Use of the open tube bronchoscope in the extraction of foreign bodies. Chest 1978, 73: 721-724.
2. Soni NK, Chatterji P. Thorny Foreign body of upper air way. Indian J Otolaryngology 1978;30:178
3. Satish HS. An unusual foreign body in cervical oesophagus. Indian J otolaryngology 1990;42:173
4. Sharma SC, Bano S. An unusual foreign body in nasopharynx. Indian J Otolaryngology Head Neck Surgery 1992;1:42-3
5. Ogut F, Bereketoglu M, Bilgeric C, Totan S. Metal ring that had been lodged in a child's nasopharynx for 4 years. Ear Nose Throat J 2000;80:235-6

Author Information

Rajesh, MS (ENT. P.G.I. CHANDIGARH)

Associate Professor, Department of ENT & Head and Neck Surgery, Himalayan Institute of Medical Sciences

Pallavi, M.B.B.S. Std.

SGRD Institute of Medical Sciences

Rajeev Singh

Post Graduate Student ENT, Department of ENT & Head and Neck Surgery, Himalayan Institute of Medical Sciences

Parteek Bakshi

Associate Professor, Community Medicine, Himalayan Institute of Medical Sciences