

Neonatal urinary ascitis from idiopathic rupture of bladder.

V Upadhyaya, A Gangopadhyaya, A Pandey, D Gupta

Citation

V Upadhyaya, A Gangopadhyaya, A Pandey, D Gupta. *Neonatal urinary ascitis from idiopathic rupture of bladder.. The Internet Journal of Urology*. 2009 Volume 6 Number 2.

Abstract

Bladder rupture in the neonate is an uncommon event, and mostly occurs as a rare complication of umbilical artery catheterization. The usual manifestations include low urine output, ascites, respiratory distress, and rising serum, urea and creatinine. Another cause is observed in premature infants who are managed in the neonatal intensive care unit by minimal stimulation therapy and mechanical ventilation. We are presenting a case of idiopathic bladder rupture in neonate. The management of such case is discussed with review of literature.

INTRODUCTION

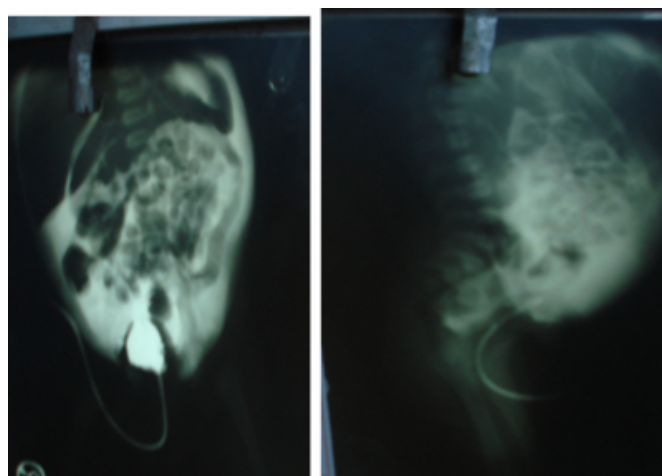
Perforation of the neonatal bladder is rare, with only 17 cases reported between 1956 and 1985¹. Predisposing factors include posterior urethral valves, neurogenic bladder, congenital bladder diverticulum, and detrusor areflexia¹. The majority are the results of umbilical arterial catheterization² causing rupture of the dome of the bladder or of a patent urachus. The posterior urethral valves in male neonates, rarely anterior urethral valve³ and the congenital diverticulum of the bladder may be predisposing anatomical factors for rupture of the bladder⁴. Spontaneous rupture of the bladder has also been reported in the literature as a result of profound hypoxia or morphine administration⁵, though ruptures may also occur without clear predisposing factors and are presumably associated with obstructive uropathy, abdominal trauma, neurogenic bladder, iatrogenic injuries during endoscopic or open surgical procedures, birth trauma, difficult obstetric delivery, urethral catheterization and umbilical catheterization^{6,7}. Extravasation of the urine into the peritoneal cavity is life threatening, as the urine undergoes "autodialysis" by the peritoneal membrane and produces a particular biochemical profile in serum that, in combination with ascites, should lead the clinician to suspect a disruption of the urinary tract⁵. Suggested management is dependent upon the mode of injury and whether the defect is intraperitoneal or extraperitoneal. In either case, identification of the injury and treatment by either an operation or catheter drainage may be lifesaving⁶. Although a rare condition, infants with urinary ascites can present as clinical emergencies in need of prompt resuscitation with subsequent drainage of the urine and decompression of the

urinary tract.

CASE HISTORY

A male infant was delivered at term and at birth voided a small amount of urine, but was then anuric for 48 h, with a blood urea level of 7.1 mmol/L and a creatinine level of 216 mmol/L. The infant developed marked abdominal distension and associated respiratory distress. Ultrasonography showed echogenic mildly-hydronephrotic kidneys, a normal empty bladder and ascites. Catheterization of bladder was done with a 5 F feeding tube with caution. Voiding cystourethrography showed a normal bladder outline, with flow of contrast medium into a large intraperitoneal collection, consistent with intraperitoneal bladder perforation (Fig. 1).

Figure 1



A vesicostomy was performed without repair of the bladder rupture. The posterior as well as anterior urethra was normal.

No urinary tract abnormalities were detected in follow up.

DISCUSSION

Ascites in the neonatal period is a rare condition, and for less than 30% of cases urinary ascites is implicated⁸. The spontaneous or iatrogenic intraperitoneal rupture of the bladder is responsible for this condition. The presence of posterior urethral valves in male neonates is one of the most common causes of spontaneous rupture of the bladder⁹. The congenital diverticulum of the bladder may predispose to the bladder rupture¹⁰. The prolonged exposure to hypoxia that leads to ischemic visceral damage may also cause ischemic lesions to the bladder, which may lead to the rupture. Umbilical arterial catheterization causing trauma to the dome of the bladder or to a patent urachus accounts for 75% of bladder ruptures¹¹. The Foley-catheter has also been reported to induce rupture^{12,13}. Morphine administration can cause urinary retention, which may lead to the rupture of the bladder⁵. Among ruptures associated with umbilical arterial cannulation, the mortality rate is 18%¹⁰. Urinary bladder perforation should be considered in a case of neonatal ascites with renal failure, which is unexplainable by other causes¹⁴. Some cases of congenital bladder perforation and urinary ascites have been diagnosed in utero^{15,16}.

The diagnosis of ascites is made by abdominal X-ray or ultrasound, but it is difficult to determine the origin of the ascitic fluid. Initial radiographic studies should include a plain abdominal film, which characteristically reveals a ground glass appearance with enteric loops in the mid abdomen¹. The association of anuria or oliguria, with hyponatremia, hyperkalemia and elevation of serum creatinine in addition to ascites must lead to the diagnosis of the urinary ascites¹². Ultrasound in some cases may reveal the lesion to the wall of the bladder. In the remainder of cases, the extravasation into the peritoneal cavity of a contrast material infused into the bladder via a transurethral catheter will confirm the diagnosis. In patients with urinary ascites, paracentesis will reveal straw-colored fluid.

A timely preoperative diagnosis and prompt surgical management can temper the morbidity associated with spontaneous bladder rupture². Conservative management with catheter drainage of the bladder for 10-14 days leads to complete healing of the lesion in most cases but in present case the rupture was not healed even after 2 weeks. Large ruptures do not respond to the conservative management and a surgical repair is required. In present case on exploration no rent was observed in the bladder hence vesicostomy was

done.

In our case, the etiology of the rupture of the bladder was unknown. During the operative exploration no anatomical defect was identified as capable of inducing rupture of the bladder. There also was no previous attempt of bladder or umbilical vessel catheterization. There was no history of hypoxia to the patient. The administration of morphine, sedation, and the consecutive urinary retention, is a predisposing factor that can be blamed for the rupture of the bladder.

References

1. Trulock TS, Finnerty DP, Woodard JR. Neonatal bladder rupture: case report and review of literature. *J Urol* 1985; 133: 271-273
2. Arora P, Seth A, Bagga D, Aneja S, Taluja V. Spontaneous bladder rupture secondary to posterior urethral valves in a neonate. *Indian J Pediatr* 2001; 68: 881-882.
3. Oei J, Garvey PA, Rosenberg AR. The diagnosis and management of neonatal urinary ascites. *J Paediatr Child Health* 2001; 37: 513-515.
4. Claahsen-van der Grinten HL, Monnens LA, de Gier RP, Feitz WF. Perinatal rupture of the uropoietic system. *Clin Nephrol* 2002; 57: 432-438
5. Sayan A, Demircan M, Erikci VS, Çelik A, Arikan A. Neonatal bladder rupture: an unusual complication of umbilical catheterization. *Eur J Pediatr Surg* 1996; 6: 378-379.
6. Kaplan WG, McAleer MI. Structural abnormalities of the genitourinary system. In: Avery GB, Fletcher MA, Macdonald GM (eds). *Neonatology Pathophysiology and Management of the Newborn* (5th ed). Philadelphia: JB Lippincott Co.; 1999: 975-1003.
7. Redman JF, Seibert JJ, Arnold W. Urinary ascites in children owing to extravasation of urine from the bladder. *J Urol* 1979; 122: 409-411
8. Diamond DA, Ford C. Neonatal bladder rupture: a complication of umbilical artery catheterization. *J Urol* 1989; 142: 1543-1544
9. Morrell P, Coultthard MG, Hey EN. Neonatal urinary ascites. *Arch Dis Child* 1985; 60: 676-678.
10. O'Brien WJ, Ryckman FC. Catheter induced urinary bladder rupture presenting with pneumoperitoneum. *J Pediatr Surg* 1994; 29: 1397-1398
11. Basha M, Subhani M, Mersal A, Saedi SA, Balfe JW. Urinary bladder perforation in a premature infant with Down syndrome. *Pediatr Nephrol* 2003; 18: 1189-1190
12. Bettelheim D, Pumberger W, Deutinger J, Bernaschek G. Prenatal diagnosis of fetal urinary ascites. *Ultrasound Obstet Gynecol* 2000; 16: 473-475
13. Lowenstein L, Solt I, Talmon R, Pery M, Suhov P, Drugan A. In utero diagnosis of bladder perforation with urinary ascites. A case report. *Fetal Diagn Ther* 2003; 18: 179-182
14. Arora P, Seth A, Bagga D, Aneja S, Taluja V. Spontaneous bladder rupture secondary to posterior urethral valves in a neonate. *Indian J Pediatr*. 2001 Sep;68(9):881-2
15. Cochran WD, Davis HT, Smith C.A. Advantages and complications of umbilical artery catheterization in the newborn. *Pediatrics* 1968;42:769
16. D.B. Glazier, S. J. Underberg-Davis, K.B. Cummings, J.G. Barone. Neonatal bladder rupture due to anterior urethral valves. *British Journal of Urology* 1997,

80,819-820British Journal of Urology (1997), 80, 819± 820

Author Information

Vijay D. Upadhyaya, MS

Senior Resident Pediatric Surgery, IMS

A.N. Gangopadhyaya, M.Ch

Prof. Pediatric Surgery IMS, BHU, Varanasi

Anand Pandey, MS

Senior Resident Pediatric Surgery, IMS

DK Gupta, MCh

Prof. Pediatric Surgery IMS, BHU, Varanasi