

Localization of an ectopic parathyroid adenoma by double-phase technetium99m-sestamibi scintigraphy

I Ghfir, F El Alloussi, N Raïs

Citation

I Ghfir, F El Alloussi, N Raïs. *Localization of an ectopic parathyroid adenoma by double-phase technetium99m-sestamibi scintigraphy*. The Internet Journal of Nuclear Medicine. 2006 Volume 3 Number 2.

Abstract

Double-phase planar scintigraphy using ^{99m}Tc -sestamibi has been introduced as a means to detect and localize parathyroid adenomas. Focal uptake on both early and delayed imaging is typical of these entities. We report a patient with persistent hypercalcemia following subtotal parathyroidectomy, who was found scintigraphically to have an ectopic parathyroid adenoma. Indeed, the acquisition of an additional planar image centred on the mediastinum allowed the ectopic localisation of adenoma. This case suggests that double-phase parathyroid planar scintigraphy is cost-effective, and often necessary, in the assessment of primary hyperparathyroid patients before surgical re-exploration.

INTRODUCTION

^{99m}Tc -sestamibi parathyroid scintigraphy is a means of functional imagery allowing the exploration of the hyperparathyroidy. We report through this work the case of a patient presenting a residual hypercalcemia after subtotal parathyroidectomy and at which the double-phase planar scintigraphy using ^{99m}Tc -sestamibi allowed the description of a mediastinum ectopic hearth.

CASE REPORT

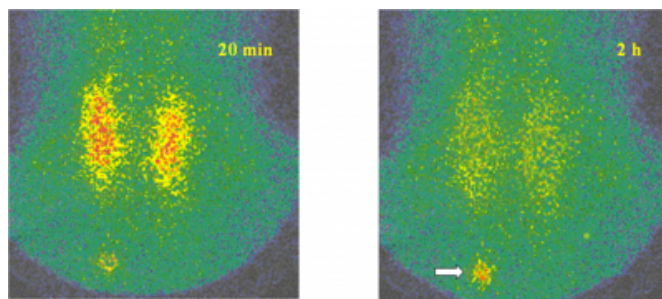
A 50 year old women had a subtotal parathyroidectomy for biological hyperparathyroidy and presented with the persistence of a residual hypercalcemia. The computed tomography and resonance magnetic nuclear imagery were inconclusive sight the post-operative fibrosis.

Parathyroid scintigraphy of the neck and upper thorax and/or mediastinum was performed 20 minutes and 2 hours after injection of 740 MBq of technetium 99m-sestamibi. To this end we used a gamma-camera with large field provided with pin-hole and parallel-hole collimators (high résolution-low energy) intended for mediastinal exploration.

The 20th minute scan showed uptake in a normal appearing thyroid gland as well as uptake in one ovoid area in the upper mediastinum. The 2nd hour image showed wash out of activity from the thyroid and persistence of activity in the upper mediastinum (Figure.1).

Figure 1

Figure 1 : Tc-Sestamibi parathyroid planar scintigraphy : the 20 minute scan showed uptake in a normal appearing thyroid gland as well as uptake in a heart of the right upper mediastinum .The 2 hour image showed wash out of activity from the thyroid and persistence of activity in the upper mediastinum (arrow).



A focused surgical resection was carried out. Pathologic examination of the surgical specimen revealed parathyroid adenoma tissue. The evolution was marked by a clear clinical improvement and a normalisation of the rate of parathormone.

DISCUSSION

A successful parathyroidectomy depends on the identification and the resection of the whole of parathyroids in hyperactivity. During several decades, one did not have recourse to the preoperative imagery before a first surgery. A bilateral, long and meticulous exploration cervical, allowed the cure from 90 to 95% of patients [1]. The two main reasons of the failure of the surgery are: ectopic glands

(retro-oesophagium, mediastinum like that is the case in our patient, intra-thyroid gland, in the sheath of the carotid artery) and multiple parathyroid pathology not detected [2]. The reintervention is often associated on a dramatic reduction of the rate of success and an increase in the surgical complications. The imagery is consequently imperative before one second intervention [3,4]. ^{99m}Tc-sestamibi parathyroid scintigraphy is currently regarded as the most significant technique of the imagery among patients reached of primary hyperparathyroidism [5,6]. Whatever the protocol used, the ^{99m}Tc-sestamibi parathyroid scintigraphy meets generally the need for detection of ectopic glands [7]. When the preoperative imagery indicates a well defined ectopic hearth, suggesting a solitary adenoma, the surgeon can currently choose a surgery focused rather than a bilateral exploration like that was carried out in our patient.

CONCLUSION

Double-phase planar scintigraphy using ^{99m}Tc-sestamibi is a means of functional imagery contributing to the exploration of hyperparathyroidism. Its sensitivity is significantly higher than the other means of morphological imagery particularly

when it acts a second surgical intervention. Its interest seems more considerable for the exploration of ectopic adenoma and to improve the success of surgery.

References

1. Russel CF, EDIS AJ. Surgery for hyperparathyroidism: experience with 500 consecutive cases and evaluation of the role of surgery in the asymptomatic patient. *Br J Surg* 1982; 69: 244-247.
2. Levin KE, Clark OH. The reasons for failure in parathyroid operations. *Arch Surg* 1989; 124 : 911-915 .
3. Sosa JA, Power NR, Levine MA, Undelsman R, Zeiger MA. Profile of a clinical practice. Thresholds for surgery and surgical outcomes for patients with primary hyperparathyroidism : a national survey of endocrine surgeons. *J Clin Endocrinol Metab* 1998; 83 : 2658-2665.
4. Weber CJ, Vansant J, Alazraki N. Value of technetium ^{99m} setamibi iodine 123 imaging in reoperative parathyroid surgery. *Surgery* 1993;114:1011-1018..
5. Giordano A, Rubello D, Casara D. New trends in parathyroid scintigraphy [review]. *Eur J Nucl Med* 2001;28: 1409-1420.
6. Mullan BP. Nucl medicine imaging of the parathyroid [review]. *Otolaryngol Clin North Am* 2004; 37:909-939
7. Haber RS, Kim CK, Inabnet WB. Ultrasonography for ppreoperative localization of enlarged parathyroid glands in primary hyperparathyroidism : comparison with ^{99m}-Technetium sestamibi Scinitgraphy. *Clin Endocrinol (Oxf)* 2002; 57:241-249.

Author Information

I. Ghfir

Department of Nuclear Medicine

F. Z. El Alloussi

Department of Nuclear Medicine

N. Ben Raïs

Head, Department of Nuclear Medicine