

# Eccrine Porocarcinoma Presenting As Ulcerated Exophytic Mass.

O O.P, T J.O, A K.U, S M.O.A

## Citation

O O.P, T J.O, A K.U, S M.O.A. *Eccrine Porocarcinoma Presenting As Ulcerated Exophytic Mass.* The Internet Journal of Pathology. 2009 Volume 11 Number 1.

## Abstract

**Background:** Eccrine porocarcinoma is a rare malignant neoplasm of the eccrine sweat gland associated with a high recurrence rate and poor response to therapy. **Materials and Method:** A report of malignant appendage tumours diagnosed over a 12 months period (August 2007- July 2008). Histology slides stained routinely with Haematoxylin & Eosin were reviewed. Patients' biodata and clinical information were obtained from the medical records. **Results:** Three malignant eccrine poroma were studied. There were 2 females and 1 male aged 38, 35 and 21 years. Clinical presentations were ulcerated exophytic lesion to polypoid circumscribed swellings. The sites of occurrence were the scalp and trunk. Tissue histology showed nests of large oval to spindle to polygonal tumour cells forming occasional tubule containing eosinophilic globules and separated by fibrous septa. **Conclusion:** Eccrine porocarcinoma should be considered in patients with exophytic tumours of the skin. A high index of suspicion, proper histologic interpretation with ancillary immunohistochemical studies will confirm diagnosis.

## INTRODUCTION

Eccrine porocarcinoma is a rare malignant sweat gland tumour that typically arises from the terminal cells of the intraepithelial portion of the eccrine duct.<sup>1</sup> It was first described by Pinkus and Mehregan<sup>2</sup> in 1963, as 'epidermotropic eccrine carcinoma', later in 1969, Mishima and Morioka<sup>3</sup> introduced the term 'eccrine porocarcinoma'. The causation is poorly understood, however it may arise de novo or as a malignant transformation of an eccrine poroma<sup>4</sup>. It has female preponderance, propensity for older age group, although it can be found in young adolescents and middle age.

## PATIENTS AND METHODS

Three patients had confirmed histological diagnosis of eccrine porocarcinoma at the Histopathology Unit, Federal Medical Centre, Lokoja, Kogi State, in the period August 2007 – July 2008. Their tissue biopsies were fixed in 10% formalin, embedded in wax and histological sections on slides were stained with Haematoxylin and Eosin (H&E). The histological and clinical details of the three patients are presented.

## RESULTS

There were two females (35yrs & 38yrs) and one male

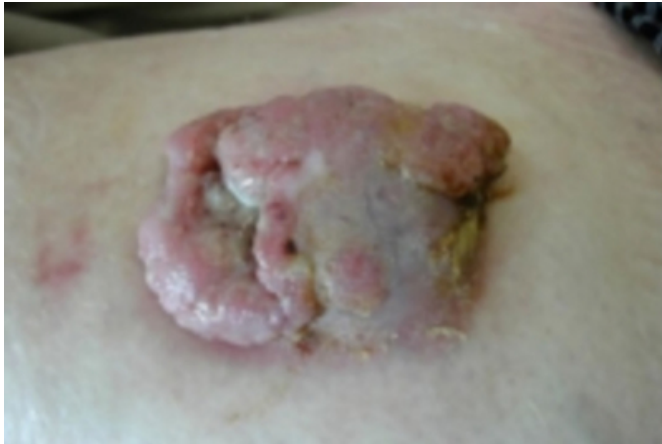(21years). The mean age is 31.3 years. They presented with progressively increasing masses/lesions localized on the left upper outer quadrant of the breast, scalp and right areolar of the breast respectively. Lesion had been presented for 6 months to 2 years.

Clinically, the two females had ulcerated exophytic nodular ulcers on the scalp and upper outer quadrant of left breast respectively, while the male had an ulcerated polypoid mass on the areolar of right breast. They had a provisional diagnosis of squamous cell carcinoma and squamous Papilloma respectively. They all had incisional biopsies for tissue histologic diagnosis. We received ulcerated exophytic masses whose measurement ranges from 5.5x4.5x3.5cm to 4.4x3.8x2.8 to 3.5x2.8x1.7cm respectively.

Histology of tissue biopsies showed sheets, nests, cribriform and large lobules of oval to spindle to polygonal tumour cells forming discrete tubules containing eosinophilic globules. The cells had moderately pleomorphic hyperchromatic to vesicular nuclei and amphophilic cytoplasm. They were diagnosed as eccrine porocarcinoma.

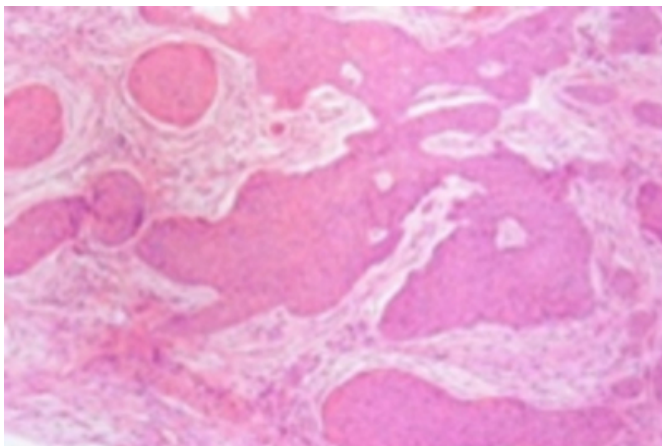
**Figure 1**

Fig 1: Gross appearance of eccrine porocarcinoma as an exophytic tumour.



**Figure 2**

Fig 2: Eccrine Porocarcinoma with ductal differentiation.



**DISCUSSION**

Eccrine porocarcinoma is a rare slow growing, but highly recurrent malignant sweat gland tumour arising from the intra-epidermal portion of the eccrine sweat gland duct epithelium.<sup>1,5</sup>

Our three cases accounted for 0.01% of all cutaneous neoplasms seen in the Histopathology Unit in the study period, while all appendage neoplasm accounted for 0.2%. These low percentages further emphasized the rarity of this tumour.<sup>6-7</sup>

Porocarcinoma had a predilection for the elderly with an average age at diagnosis of 67 years, however, but it may occur at any age.<sup>1</sup> The mean age of our patients (31.3 years) is at variance with the peak age distribution of 6<sup>th</sup> and 9<sup>th</sup> decades reported by Walsh<sup>8</sup> (66.8 years) and Forouzanfar<sup>9</sup> et al (91 years) respectively. There is a female preponderance

as seen by other authors and in this report.<sup>1-2, 5, 8-9</sup> The lesion commonly occur on the lower extremities, head, scalp, upper extremities and trunk.<sup>5, 10</sup> All our cases fall within the ambit of these sites.

Similar studies in Lagos<sup>11</sup> Zaria<sup>12</sup> and Jos<sup>13</sup> in Nigeria reported that these tumours were least common even though they recorded relatively higher percentages attributable to the larger patient size from their respective teaching hospitals which were referral centers.

Clinically, eccrine porocarcinoma presents as a moist nodule, verrucous cauliflower-like infiltrative plaque or as a polypoid lesion that frequently ulcerated and bleeds.<sup>10, 14</sup> Multi-nodularity, rapid growth and ulceration may be associated with local recurrence or metastasis.<sup>10, 14</sup> These features were seen in all three patients.

The predominant histologic features in this series is that of an invasive tumour growing in sheets, solid nests, islands, cribriform and large lobules with attempt at forming tubules. The cells were spindle to polygonal having moderately pleomorphic hyperchromatic to vesicular nuclei and amphophilic cytoplasm. Diagnosis was based on morphologic features alone, as further characterization of the tumour was impossible due lack of ancillary investigative tools, like immunohistochemistry.

Definitive diagnosis is established based on tissue histology and immunohistochemistry reactivity with Diastase Periodic Acid -Schiff (DPAS), Epithelial Membrane Antigen (EMA), Carcinoembryonic Antigen and S-100 protein.<sup>15</sup>

Eccrine porocarcinoma should be considered in the differential diagnosis of any moist exophytic or polypoid lesion or mass of the skin. The treatment is surgical intervention with wide local excision. There is no record in the literature of the recommended margin of excision, which may have an effect on tumour metastasis and patient survival. Moh's surgery is another option of treatment.<sup>16</sup> Adequate histologic sections and comments on resection margins are mandatory in determining prognosis.

**References**

1. Vandeweyer E, Renoirte C, Musette S, Giles A. Eccrine Porocarcinoma: A Case Report. *Acta chir belg* 2006; 106: 121-123.
2. Pinkus H, Mehregan A. Epidermotrophic eccrine carcinoma: A case combining features of eccrine poroma and Paget's dermatosis. *Arch Dermatol* 1963; 88: 587-607.
3. Mshima Y, Morioka S. Oncogenic differentiation of the intra-epidermal eccrine sweat duct; eccrine poroma, poro-epithelioma and porocarcinoma. *Dermatologica* 1969; 138:

238-250

4. Rana RE, Verma SS, Puri VA, Baliarsing AS. Sweat gland tumour (Eccrine Porocarcinoma) of scalp: A rare tumour. *Indian J Plast Surg* 2005; 38: 51-53
5. Affleck AG, Bong JL, Ostroumova MA, Leach IH, Perks AG, Varma S. Eccrine Porocarcinoma. *Dermatology Online Journal* 2006;12; (1): 17.
6. Cooper PH. Carcinoma of sweat gland. *Pathol Annu* 1987; 22 (PE 1): 83-124.
7. Janota I. Adnexal Skin tumours in Nigeria. *Br J Dermatol* 1967; 79: 259-270.
8. Walsh MS. A case of eccrine porocarcinoma. *J R Soc Med* 1990; 83 (8): 529-530.
9. Forouzanfar A, Anwar MU, Ahmad M, Al Ghazal SK. Eccrine Porocarcinoma. *Journal of the College of Physicians and Surgeons Pakistan* 2008; 18 (4): 234-235.
10. Heut P, Dandurand M, Pignodel C, Guillot B. Metastasizing eccrine porocarcinoma; report of a case and review of the literature. *J Am Acad Dermatol* 1996; 35:

860-864.

11. Adeyi O, Banjo A. Malignant tumours of the skin: A 6-year of Histopathologically diagnosed cases (1990-1995). *Nig Qt J Hosp Med* 1998; 8 [2]: 99-102.
12. Samaila M.O.A. Malignant Appendage Tumour in Zaria. *Sudan J Dermatol* 2007; 5 (1): 11-14.
13. Mandong BM, Orkar KS, Sule AZ, Dakum NL. Malignant skin tumours in Jos University Teaching Hospital, Jos. *Nig J Surg Resear* 2001; 3 [1]: 29-33.
14. Robson A, Greene J, Ansari, Kim B, Seed PT, McKee PH, Calonge E. Eccrine porocarcinoma (malignant eccrine poroma): A clinicopathologic study of 69 cases. *Am J Surg Pathol* 2001; 25: 710-720.
15. Urso C, Bondi R, Paglierani M, Salvadori A, Anichini C, Giannin A. Carcinomas of sweat glands: Report of 60 cases. *Arch Pathol Lab Med* 2001; 125: 498-505.
16. Wildemore JK, Lee JB, Humphreys TR. Moh's surgery for malignant eccrine neoplasms. *Dermatol Surg* 2004; 30 (12pt2): 1574-1579.

**Author Information**

**Oluwole O.P**

Department of Pathology, College of Health Sciences, University of Abuja

**Taiwo J.O**

Department of Surgery, Federal Medical Centre

**Awani K.U**

Department of Surgery, Federal Medical Centre

**Samaila M.O.A**

Department of Pathology, Ahmadu Bello University Teaching Hospital