

Intraoperative Cerebrovascular Accident Due To Post Clinoid Meningioma Can Mimic TURP Syndrome During TURP Surgery

V Amale, M Sarkar, S Pandya

Citation

V Amale, M Sarkar, S Pandya. *Intraoperative Cerebrovascular Accident Due To Post Clinoid Meningioma Can Mimic TURP Syndrome During TURP Surgery*. The Internet Journal of Anesthesiology. 2008 Volume 19 Number 2.

Abstract

TURP syndrome is a well known entity in patients undergoing TURP. Patients presenting with intraoperative CVA can mimic TURP syndrome when CVA occurs during TURP surgeries. Presence of post clinoid meningioma further complicates the cause of CVA. Early neurological evaluation, CT-scan and use of newer modalities of investigations such as bispectral index and transcranial doppler can diagnose CVA early and treatment can be started accordingly. A high degree of suspicion is needed in such cases to diagnose the exact cause of altered sensorium in elderly patients undergoing TURP and to manage it accordingly

CASE REPORT

A 68 years hypertensive male was posted for TURP surgery. Blood Chemistry was within normal limits. ECG was suggestive of left ventricular hypertrophy (LVH) and 2D ECHO showed concentric LVH with diastolic dysfunction. Chest X-ray was consistent with mild cardiomegaly. USG abdomen showed mildly enlarged liver with medical renal disease, bilateral cortical scarring with small shrunken left kidney. The patient was on antihypertensive medications and his blood pressure was within acceptable limits. Blood pressure at the time of induction was 140/90 mm Hg. All standard monitors (cardioscope, pulse oximeter, sphygmomanometer) were attached. Subarachnoid block was given with 3.4 ml of 0.5% bupivacaine in sitting position with 25 Gauge spinal needle and T₁₀ level was achieved. Glycine 1.5% was used as irrigating fluid. All vital parameters were monitored and were within acceptable limits. After 45 min of surgical resection the patient became drowsy and unresponsive to oral commands. His respiration became irregular and there was a rise in blood pressure to 170/90 mm Hg and heart rate of 120/min. TURP syndrome was suspected and the patient was intubated. Surgery was abandon and blood samples for serum electrolytes ammonia and osmolality were sent to laboratory. The patient was shifted to ICU.

Sr. electrolytes, ammonia and osmolality were within normal limits. 12 lead ECG was within normal limits and CPK-MB was marginally raised and Troponin-t was negative.

Patient came out of muscle relaxants in ICU and was maintaining saturation on T-piece but Patient was drowsy and not responding to oral commands. Rest all vital parameters were within normal limits.

Supportive treatment consisting of appropriate antibiotics, DVT prophylaxis, antihypertensives, analgesics sedatives water bed, chest physiotherapy were provided.

COURSE IN INTENSIVE CARE UNIT

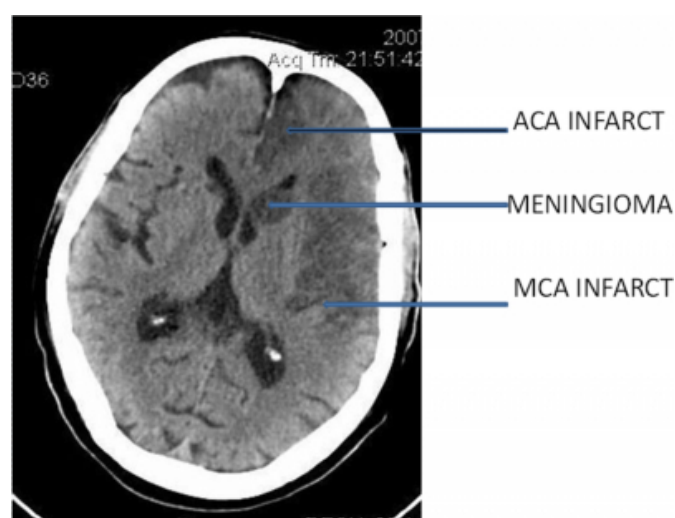
To our surprise all the investigations including

Figure 1

Table showing course of the patient in I C U

Day in ICU	Course in ICU	Significant Ix reports	Measures undertaken
1 st day	Patient on T-piece Unresponsive to oral commands	Nil	Supportive Treatment
2 nd day	EtcO ₂ raised		Ventilatory support
3 rd day	Neurologically same	CT brain-acute infarction in Lt ACA,MCA territory, postclinoid meningioma 30mmx15mm. ABG-within normal limits.	Clopidogrel, mannitol,piracetam
4 th to 8 th day	Same as above		Supportive
9 th day	Anticipated prolonged ventilation		Tracheostomy
10 th to 12 th day	Same as above		Supportive
13 th day	Fever and hypotension	Leucocytosis,raised Sr.creatinine	Dopamine Support started, rest same as above
15 th day	Spiking fever, LRTI	Leucocytosis,raised Sr.creatinine	As per culture sensitivity report antibiotics changed
16 th day	Spiking fever, hypotension, generalized edema	Leucocytosis,raised Sr.creatinine	Support on dopamine, noradrenalin, albumin and FFP transfusion
17 th day	ARDS,oliguria Oliguria, generalized edema	X-ray chest- pulmonary oedema, raised Sr.creatinine	Supports continued
18 th day	Oliguria, generalized edema	Suspected renal failure	Death

Figure 2



DISCUSSION

Cerebrovascular accidents in patients with meningioma who are hypertensive can occur during stressful conditions like surgery and anesthesia . So the occurrence of such an event during TURP where altered sensorium can be attributed to electrolyte abnormalities require a high degree of suspicion.

A standard search of literature could not reveal occurrence of cerebrovascular accident in TURP which was associated with a post clinoid meningioma.

Subarachnoid block(SAB) is a widely accepted anesthetic choice for TURP surgeries because it has advantages like early recognition of TURP syndrome, bladder perforation and decreased blood loss intraoperatively. Except for hypertension and LVH on ECHO our patient did not have any positive finding. Use of a subarachnoid block in such a case is justified. If the diagnosis of postclinoid meningioma was already done we would have not given SAB to the patient. Although central neuroaxial blockade is considered relatively safe procedure certain complications like seizures, transient neurological deficit and radiculopathy and myelopathy [1723] can occur. Diagnosis of a brain tumour after spinal anaesthesia is rare[7]Few case reports mention pituitary tumors due to apoplexy or necrosis[412] and pineal tumor[6]. A case report of incidental finding of meningioma after spinal anaesthesia has been reported[14].Case reports of intracranial meningioma presenting after general anaesthesia are also reported.These patients were either asymptomatic or so subtly symptomatic that no suspicion of intracranial tumor had been entertained preoperatively .Each patient presented with failure to wake up after routine general anesthesia for a nonneurosurgical procedure[816].

TURP syndrome itself can lead to confusional state,unresponsiveness[11] and it is difficult to pin point the exact cause of this neurological states in patients presenting with CVA intraoperatively.Sometimes Sr sodium level may not be the only cause of CNS signs in TURP[13]. A case of intraoperative CVA during laminectomy is reported in which decreased cerebral perfusion resulted due to raised jugular venous pressure as a result of prone position [9].Hypotension may be one of the reasons for intraoperative strokes in patients who are given bolus doses of local anaesthetic epidurally during surgery or as a part of post operative pain relief [5].Rarely cerebral air embolism can occur due to right to left shunt if prostatic venous sinuses are open and are above the level of heart.

If cerebral embolisation is suspected then early diagnosis is both essential and feasible as the mortality associated with infarction of more than 50% of the middle cerebral artery territory is 85%_[15]. C.T. scanning within 5 hrs of symptoms can demonstrate changes in 70-80% patients presenting with acute hemispheric strokes_[15]. Use of newer modalities of investigations like bispectral index may prove to be the earliest indicator of acute perioperative stroke_[10]. Recent modalities like transcranial Doppler may diagnose CVA early and help in deciding the treatment modalities_[1].

To conclude, better results in the management of patients with intraoperative stroke requires high degree of suspicion early recognition and prompt treatment. Even careful physical examinations and investigations preoperatively does not necessary mean uneventful intraoperative course. Early neurological evaluation and CT Scan is advised in such cases. Use of newer monitoring equipments like bispectral index and transcranial Doppler may prove beneficial in early detection of intraoperative stroke.

ACKNOWLEDGEMENT

Dr. Sanjay Oak , Dean , Seth G.S. Medical college , Parel , Mumbai.

References

1. Andrei V Alexandrov, Mathew Joseph: Transcranial Doppler: An Overview of its Clinical Applications. The Internet Journal of Emergency and Intensive Care Medicine. 2000. Volume 4 Number 1.
2. Auroy Y, Benhamou D: Major complications of regional anaesthesia in France, Anaesthesiology 2002; 97: 1274-80
3. Auroy Y, Narchi P, Messiah A et al: Serious complications related to regional anaesthesia results of prospective survey in France, Anaesthesiology 1997; 87(3) : 479-86
4. Bria A, Berger A, Pepcak F: Pituitary necrosis after spinal anaesthesia: A case report, Ann Endocrinol Paris 2000 May 61(2) : 164-7
5. C. Wu Perioperative stroke associated with postoperative epidural analgesia . Journal of Clinical Anesthesia , Volume 12 , Issue 1 , Pages 61 – 63
6. Dutton DA: A post spinal headache associated incidental intracranial pathology, a case report, Anaesthesia 1992, May 47(5): 450-1
7. Ercan Ozer et al: Initial presentation of prostatic adenocarcinoma after spinal anaesthesia as a falxian mass, Journal of Neurological Sciences (Turkish) 2004 21:(1) # 5, 27-32
8. Giordano, Flavio ; Urciuoli, Rosa Maria ; Ragazzi, Paola ; Griva, Federico ; Cossandi, Christian ; Fontanella, Marco ; Pagni, Carlo Alberto. Sudden Presentation of Intracranial Meningioma After Elective General Anesthesia. Journal of Neurosurgical Anesthesiology. 13(2):138-142, April 2001
9. Honma Keiko, Ito asuka, Maekawa Kengo, Baba Tomoko., Goto Tomoko. Intraoperative Stroke in a Patient Undergoing Lumbar Laminectomy. Journal of Clinical Anesthesia VOL.26; NO.7;PAGE.1072-1074(2002)
10. Ian J. Welsby, J. Mark Ryan, John V. Booth, Ellen Flangan, Robert Messier, Cecil O. Borel. The Bispectral Index In The Diagnosis Of Perioperative Stroke: A Case Report And Discussion. Anesthesia Analgesia 2003;96:435-37
11. Malhotra V. Transurethral resection of the prostate. Anesthesiol Clin North Am 2000 Dec;18(4):883-897
12. M Lenn, P Seigne, AJ Cunningham: Pituitary apoplexy after spinal anaesthesia, British Journal of Anaesthesia 1998, vol 81, issue 4616-618
13. N. Mehmet Mutlu, Ayşe P Mutlu Titiz & Nermin Göğüş: Hyponatremia And Neurological Manifestations of TURP Syndrome: The Internet Journal of Anesthesiology. 2007; Volume 12, Number 1.
14. Pallavi Lande Marghade, Sunil Gvalani, Prashant Jedge, Sarla H. Pandya, L. V. Dewoolkar: Incidental Diagnosis Of Sphenoid Meningioma After Spinal Anaesthesia. The Internet Journal of Anesthesiology. 2007. Volume 12 Number 2.
15. Von Kummer R, Meyig-Llamade U, Forsting M, et al. Sensitivity and prognostic value of early CT in occlusion of the middle cerebral artery trunk. AJNR Am J of Neuroradiology 1994;15:9 discussion 16-8.
16. Young, Henry A. ; Smith, Howard F.; Gregory, Susan A.; Gleave, John. Intracranial Meningioma Unmasked by Elective General Anesthesia: Report of Three Cases. Neurosurgery. 14(3):328-331, March 1984.
17. Yuen EC, Layzer RB, Weitz SR, Olney RK. Neurologic complications of lumbar epidural anesthesia and analgesia. Neurology. 1995 Oct;45(10):1795-801

Author Information

Vikram Amale, M.B.B.S.

Junior Resident, Department of Anesthesiology, Seth G S Medical College and KEM Hospital

Manjula Sarkar

Professor, Department of Anesthesiology, Seth G S Medical College and KEM Hospital

Sarla Pandya

Professor and H.O.D., Department of Anesthesiology, Seth G S Medical College and KEM Hospital