

# A Case Of Juvenile Polyarteritis Nodosa With Intestinal Hemorrhage And Multiple Cranial Nerve Palsy

M Arami, B Zamani

## Citation

M Arami, B Zamani. *A Case Of Juvenile Polyarteritis Nodosa With Intestinal Hemorrhage And Multiple Cranial Nerve Palsy*. The Internet Journal of Rheumatology. 2004 Volume 2 Number 1.

## Abstract

Polyarteritis Nodosa PAN is not common in adolescents. Here, we report a case of a 13 year old girl with PAN who presented with recurrent abdominal pains followed by cutaneous and peripheral nerves involvements during three years with a relapsing-remitting course. This is a classic case of PAN in an adolescent who diagnosed late in the course of her disease because its monosymptomatic and unusual presentation. Also there are some reports about cranial nerves involvements with separate mechanism. In our case oculomotor and vestibuloacoustic nerves were seen in the absence of signs of brainstem disease.

## INTRODUCTION

Kussmaul and Maier first described polyarteritis nodosa (PAN) in 1866 after observing areas of focal inflammatory exudations that gave rise to palpable nodules in a patient with advanced disease (1). PAN, like other vasculitides, is generally multisystem and most commonly affects skin, joints, peripheral nerves, the gut, and the kidney vasculature. In 1948, Davson et al described a microscopic PAN characterized by a diffuse necrotizing glomerulonephritis with similar clinical features to classic PAN but with the additional manifestations of small vessel involvement resulting in rapidly progressive glomerulonephritis (RPGN) and pulmonary capillaritis (2).

Polyarteritis nodosa (PAN) is a vasculitis of medium-sized or small vessels. The vasculitis of PAN has a predilection for medium-sized arteries of the skin, peripheral nerves, the gut, and the kidney vasculature. PAN is predominantly observed in patients aged 40-60 years, but can occur in all age groups. When PAN presents in an atypical location and atypical age group, the diagnosis becomes less straightforward.

PAN is not common in adolescents. Here, we report a case of a 13 year old girl with PAN who presented with recurrent abdominal pains followed by cutaneous and peripheral nerves involvements during three years with a relapsing-remitting course. This is a classic case of PAN in an adolescent who diagnosed late in the course of her disease because its monosymptomatic and unusual presentation.

## CASE REPORT

In November 2004, a 15-year old girl was admitted to our hospital because of foot drop and abdominal pain.

The patient had been well until three years before admission, when recurrent abdominal pains developed. The location of abdominal pains was periumbelical and there was not accompanying nausea and/or vomiting, night sweats, intermittent diarrhea and fever. Two years before admission, she noted erythematous vesicles and papules over the both shins with next central ulceration. During last year, she had high blood pressures in her visits in the range of 140/90 to 160/110 mmHg. Some laboratory and radiologic tests were done for evaluation of abdominal pains and hypertension. Immunologic tests for rheumatoid factor, antinuclear antibodies, anti dsDNA antibodies, cANCA, anticardiolipin antibodies, C3, C4, CH50 levels and hepatitis B virus surface antigen and HCV Ab were negative. Erythrocyte sedimentation rate was 8 mm/h and C-reactive protein was 3+ and all other hematological and biochemical tests were normal. Ultrasound examination of abdomen and pelvis, upper GI series, endoscope study of esophagus, stomach and duodenum showed no abnormality. Abdominal and pelvis CT with contrast were normal. Gastric biopsy samples showed chronic inflammatory gastritis.

Four month before admission she complained headache, vertigo and diplopia. Third cranial nerve palsy with ptosis was diagnosed. Hearing loss in left ear was developed in next days. Magnetic resonance imaging (MRI) was normal.

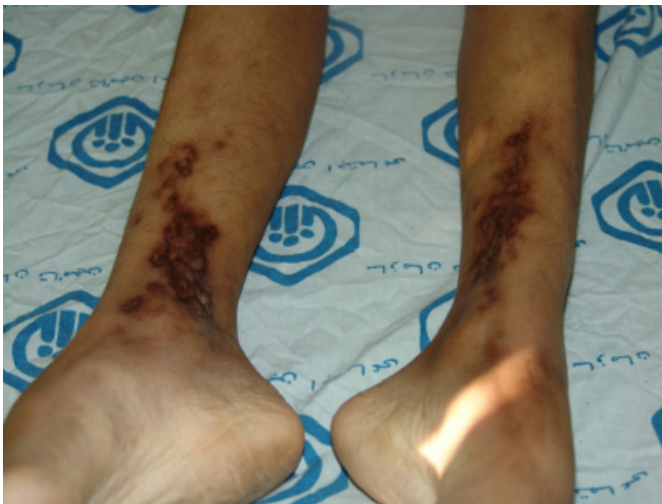Audiometry showed sensory hearing loss in left ear. Two month before, she had an exacerbation of abdominal pain and erythematous nodules on anterior surface of her legs. So she admitted in other hospital. A skin-biopsy specimen disclosed leukocytoclastic vasculitis and the patient were treated with oral prednisone at a dose of 40 mg daily.

Five days before admission, numbness developed in the left toes and progressed to foot drop.

On examination, the patient was cachectic (34 Kg) and had a weight loss of about 8 kg during last month due to her anorexia. There was patchy, brownish pigmentation, with depressed, hyperpigmented areas, 2 to 5 cm in diameter, over both shins (fig 1). No peripheral edema was found. The temperature was 36.8°C, the pulse was 86, and the respirations were 14. The blood pressure was 150/90 mm Hg. The thyroid gland was not enlarged and tender. The lungs were clear and cardiovascular examination was normal. There was hypogasteric and periumbilical tenderness in abdominal palpation. There was no organomegaly and joints were not swollen and tender. The urine was negative for protein; the sediment contained 1 to 2 red cells, 2 to 3 white cells, and 0 to 2 hyaline, granular, and white-cell casts and a few bacteria per high-power field. Echocardiography was normal.

#### **Figure 1**

Figure 1: Ulcerated erythematous nodules on anterior surface of legs



On neurological examination, the patient was oriented, with intact memory and cognition. Fundoscopic examination was normal. The strength was 5/5 at the both hamstring and quadriceps muscles and 1/5 at the left anterior tibial muscle (sever foot drop), the motor power elsewhere was normal.

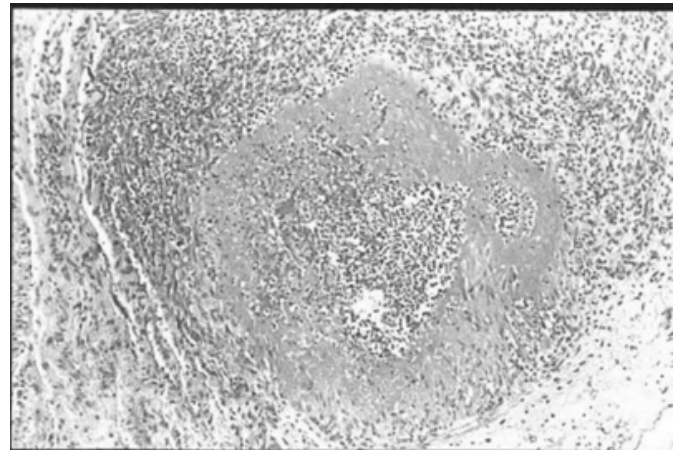
No focal atrophy or abnormal movement was detected. The sensations of a light touch, a pinprick, and temperature were reduced on the lateral aspect and ball of the left foot and all sensation was normal above the ankle. The deep-tendon reflexes were 2+ and the plantar responses were flexor. Mild ptosis in left eye and total hearing loss were found in cranial nerve examination.

On the fourth hospital day, weakness and paresthesia developed in right foot and left hand. Electromyography showed mononeuritis multiplex involving proneal and median nerves.

On the seventh hospital day, the abdominal pain became sever and abdominal rigidity and garding developed. Laparotomy was done and multiple perforations were seen in distal ileum. After resection and anastomosis, the involved segment of small bowel was sent for pathologic study. The pathological features of the specimens are characteristic of classic polyarteritis nodosa. There was evidence of vasculitis involving small to medium size arteries having thick wall and narrow and occasionally occluded lumen, infiltration of lymphomononuclear leucocytes within the wall of vessels in some areas accompanied by fibrinoid change in one small vessel wall. Also, focal ischemic necrosis of small intestinal wall, perforation and acute peritonitis were seen. (Fig 2 )

#### **Figure 2**

Figure 2: pathological features of the intestinal biopsy



We initiated treatment with glucocorticoids (prednisone 1mg/Kg) and cyclophosphamide (500mg IV), to which the patient had a good response. Her abdominal pain disappeared, he gained weight and the blood pressure was 120/80 mmHg in following controls but the peripheral nerves involvement was persistent in the end of one month follow up period.

## **DISCUSSION**

Although the PAN is uncommon in children but there are reports of childhood and juvenile cases. Ettlinger reported 2 infants and 7 older children with polyarteritis nodosa. The most frequent clinical features included prolonged high fever, skin rash, abdominal symptoms, leukocytosis, proteinuria, and signs of either cardiac or renal failure. The 2 infants died of cardiac arrest, whereas renal or neurological involvement was the most common cause of death in the older children. A consistent finding at autopsy was arteritis of the epicardial coronary arteries (3). The criteria for PAN as put forth by the American College of Rheumatology include any three of the following: weight loss greater than or equal to 4 kg, livedo reticularis, testicular pain or tenderness, myalgias, mononeuropathy or polyneuropathy, diastolic blood pressure greater than 90 mm Hg, elevated blood urea nitrogen or serum creatinine levels, presence of hepatitis B reactants in serum, arteriographic abnormality, and presence of granulocyte or mixed leukocyte infiltrate in an arterial wall biopsy (4). The initial presentation of our patient met four criteria more (four) than the minimal three criteria required for classification as PAN. The definite diagnosis of PAN is made by first sampling accessible tissue by biopsy which was done very late in this case; the most accessible tissue sites for biopsy are skin, sural nerve, testes, and skeletal muscle. Prevalence of system involvement in childhood PAN is different than in adults. For example hypertension in children is more common (80% versus 37%), also skin lesions and gastrointestinal involvement are more common in childhood. Ozen et al. using a multicenter survey of 110 children concluded that there are remarkable differences among pediatric patients with PAN, with different clinical manifestations and overall better survival and lower relapse rates when compared with adults. So they recommended diagnostic criteria for polyarteritis nodosa in childhood. They defined involvement of musculoskeletal and renal systems as the major diagnostic criteria in polyarteritis nodosa. Also ten additional minor criteria were defined by them as: (1) cutaneous findings, (2) gastrointestinal involvement, (3) peripheral neuropathy, (4) central nervous system involvement, (5) hypertension, (6) cardiac involvement, (7) lung involvement, (8) constitutional symptoms, (9) presence of acute-phase reactants, and (10) presence of hepatitis B surface antigen. They propose that the presence of five of those criteria, including at least one major criterion, is highly suggestive of polyarteritis nodosa and such a combination was present in 97% of their patients (5, 6).

Leukocytoclastic vasculitis reported in skin biopsy is not diagnostic of polyarteritis nodosa. It could see in some other inflammatory disorders like SLE, Wegener's granulomatosis, and Henoch Schonlein and paraneoplastic syndromes. Also some drugs could induce it. Leukocytoclastic vasculitis has reported in polyarteritis nodosa.

Certain laboratory findings, although nonspecific, may be helpful in the initial evaluation to understand the systemic nature of the disease. These include the following: Elevated erythrocyte sedimentation rate (ESR) greater than 60 mm/h (78-89%), Increased C-reactive protein, Leukocytosis (45-75%), Decreased serum albumin, Normochromic anemia (34-79%), Thrombocytosis, Presence of hepatitis B surface antigen (7-36%), Cryoglobulins, circulating immune complexes, and diminished serum complement (i.e., C3, C4) may be observed in patients with HBV-related PAN but otherwise are not characteristic. Of note, ANCA is rarely found in PAN. In our case some of these laboratory tests were abnormal but the others were not. ANCA and ESR was not positive in any phase of disease but CRP was +++. There was Leukocytosis (11000-14500) and Anemia (8.5-10.5g). This shows that in the absence of an available site for biopsy, Failure to recognize the diagnosis of PAN could be a medical pitfall.

Nervous system involvement is common in PAN. Involvement of the central nervous system is rare in polyarteritis nodosa, but this patient had signs of small-vessel disease, which can result in seizures and stroke. This feature of his illness may have been related to his previous abuse of drugs, including cocaine, and may have been complicated by malignant hypertension. Ten percent of patients with polyarteritis nodosa have ischemic strokes or even cerebral hemorrhages (7). Although, oculomotor motility disorders are rarely seen in PAN but we found a third cranial nerve palsy in our patient... Kirkali et al. reported two cases of PAN presented with third nerve palsy and internuclear ophthalmoplegia. They hypothesized that the third nerve palsy and internuclear ophthalmoplegia were caused by a vascular infarction in the brain stem (8). Also there are some reports about cranial nerves involvements with separate mechanism. Moore et al reported dysfunction of trigeminal, facial and vestibuloacoustic nerves in the absence of signs of brainstem disease that were cranial mononeuritis multiplex (9).

Reports of small numbers of PAN cases have periodically appeared in the pediatric literature. The classic case of PAN

remains rare and accounts for only 0.5 percent of referrals to pediatric rheumatology clinics. The clinical course and progression of PAN in childhood are highly variable, and multisystem involvement leads to confusion with numerous other disorders. Presentation of disease with recurrent abdominal pain could be related to appendicitis and other infective/inflammatory or nonspecific pathologies so early diagnosis and correct classification of PAN in this age group is difficult. Al Mazyad reported 11 case of PAN during seven years (1990-1997) in Saudi Arabia. The clinical presentations were musculoskeletal symptoms in all, mucocutaneous findings in 10 (91%), fever in eight (73%), gastrointestinal manifestations in six (55%) and hypertension in five (45%). The most frequent laboratory findings were leukocytosis, anaemia, thrombocytosis and a high erythrocyte sedimentation rate. He concluded a high index of suspicion with early combination therapy will help in decreasing the mortality in these cases (<sub>10</sub>). There are some reports of benign forms of PAN in children (<sub>11, 12</sub>). Kumar et al reported 10 children younger than 10 years of age with benign cutaneous polyarteritis nodosa (BCPAN). Clinical findings of patients were: fever (10), peripheral gangrene (eight), livido reticularis (four), ulceration, nodules and vesiculobullous lesions alone or in combination (10), black necrotic patches over limbs and trunk (three), and arthralgia or swelling of large joints (seven). Histopathology of the skin lesions revealed vasculitis of small and occasionally medium sized blood vessels. Response to corticosteroids alone occurred in seven patients, while three children needed cytotoxic drugs in addition. In a follow up of 5.6 years (mean) no evidence of systemic involvement was noted (<sub>12</sub>).

This patient underwent an appropriate evaluation for gastrointestinal and gynecologic pathologies with negative results but unfortunately the cutaneous lesions were not

evaluated cautiously. Like other reported cases (<sub>13</sub>) it seems that the abdominal pain is a common symptom in pediatric PAN. Although recurrent abdominal pain is common in this age group but accompanying skin lesions could be help physician to select a proper diagnostic approach.

## References

1. Gene VB, Robert MG. Vasculitis, in: Koopman WJ: Arteritis and allied conditions. 13th edition, chapter 77. Williams and Wilkins. Pennsylvania, 1997; p 1497.
2. Leonard H, Calabrese S, George P. Kelley's Textbook of Rheumatology. 6TH edition, Vol 2. p 1176.
3. Ettlinger RE, Nelson AM, Burke EC, Lie JT. Polyarteritis nodosa in childhood a clinical pathologic study. *Arthritis Rheum.* 1979; 22(8): 820-5. (Abstract)
4. Lightfoot RW Jr, Michel BA, Bloch DA, et al. The American College of Rheumatology 1990 criteria for the classification of polyarteritis nodosa. *Arthritis Rheum* 1990; 33:1088-1094.
5. Ozen S, Anton J, Arisoy N, Bakaloglu A, Besbas N, Brogan P et al. Juvenile polyarteritis: results of a multicenter survey of 110 children. *J Pediatr.* 2004; 145(4): 517-22.
6. Ozen S, Besbas N, Saatci U, Bakaloglu A. Diagnostic criteria for polyarteritis nodosa in childhood. *J Pediatr.* 1992; 120(2 Pt 1): 206-9.
7. Provenzale JM, Allen NB. Neuroradiologic findings in polyarteritis nodosa. *AJNR Am J Neuroradiol* 1996; 17:1119-1126. [Abstract]
8. Kirkali P, Topaloglu R, Kansu T, Bakaloglu A. Third nerve palsy and internuclear ophthalmoplegia in periarteritis nodosa. *J Pediatr Ophthalmol Strabismus.* 1991; 28(1): 45-6.
9. Moore PM, Fauci AS: Neurologic manifestations of systemic vasculitis: a retrospective and prospective study of the clinicopathologic features and responses to therapy in 25 patients. *IS J Med* 1981; 71: 517.
10. Al Mazyad AS. Polyarteritis nodosa in Arab children in Saudi Arabia. *Clin Rheumatol.* 1999; 18(3): 196-200.
11. Siberry GK, Cohen BA, Johnson B. Cutaneous polyarteritis nodosa. Reports of two cases in children and review of the literature. *Arch Dermatol.* 1994; 130(7): 884-9.
12. Kumar L, Thapa BR, Sarkar B, Walia BN. Benign cutaneous polyarteritis nodosa in children below 10 years of age--a clinical experience. *Ann Rheum Dis.* 1995; 54(2): 134-6.
13. Blau EB, Morris RF, Yunis EJ. Polyarteritis nodosa in older children. *Pediatrics.* 1977; 60(2): 227-34.

**Author Information**

**M. A. Arami, M.D.**

Assistant Professor, Neurology Department, Shahid Beheshty Hospital, Kashan University of Medical Sciences

**B. Zamani, M.D.**

Assistant Professor, Rheumatology Department, Shahid Beheshty Hospital, Kashan University of Medical Sciences