

Venous Air Embolism During Supine Craniotomy For Aneurysm: Role of Hyperbaric Oxygen Therapy

J Nates, J Aristizabal, D Kim, C Fife

Citation

J Nates, J Aristizabal, D Kim, C Fife. *Venous Air Embolism During Supine Craniotomy For Aneurysm: Role of Hyperbaric Oxygen Therapy*. The Internet Journal of Anesthesiology. 1999 Volume 4 Number 3.

Abstract

INTRODUCTION

Venous air embolism (VAE) has been estimated to occur in 45% and 12% of the patients undergoing craniotomies in sitting and supine position respectively¹. The number of cases reported has dropped dramatically in last few years, probably due to the fact that it is a well recognized complication and has been already described in the literature during anesthesia in sitting position, cesarean section, laparoscopy, and many others²³⁴⁵⁶⁷⁸. However, it is less known that despite the differences in the incidence of minor VAE episodes during sitting position procedures, the incidence of major cardio-respiratory events as result of VAE is the same (1.5%) in patients undergoing a craniotomy in either position¹. Recently, many authors have noted the lack of awareness of physicians to recognize VAE⁵⁶⁷. This and the fact that hyperbaric oxygen (HBO2) therapy is not readily available in many institutions or even considered, reduce the likelihood that patients will receive rapid treatment after air embolism.

We report a case of a clinically diagnosed VAE and suspected paradoxical embolism (PAE) that responded to rapid HBO2 therapy. Our main purpose is to increase awareness among anesthesiologists of the use of HBO2 in arterial air embolism regardless of etiology, particularly since this well recognized complication still remains under treated in most cases.

CASE REPORT

A seventy-eight year-old Hispanic female was admitted to our institution complaining of severe headache and saying, "she was going to die". She had previous history of coronary heart disease, chronic obstructive pulmonary disease, hypercholesterolemia, chronic gastritis, new onset arterial hypertension and diverticulosis. She had a previous

cholecystectomy, left inguinal herniorrhaphy and right carpal tunnel surgery with no history of allergies or alcohol/tobacco use. Her medications included cimetidine and pravastatine. On arrival to the emergency room she was confused with a Glasgow Coma Score (GCS) 13 (E-3, V-4, M-6), no focal motor deficits or cranial nerve abnormalities were evident, and both pupils were equal and reactive to light and accommodation. A CT scan of her brain showed subarachnoid hemorrhage. A four-vessel cerebral digital subtraction angiography showed a right middle cerebral artery aneurysm and the patient was taken to the operating room for urgent craniotomy.

A central venous line in the right internal jugular vein and an arterial line in the right radial artery were inserted before the procedure started under general endotracheal anesthesia (GETA) in supine position. No precordial Doppler was used but, pulse oximeter, capnograph, EKG, temperature, and a six-channel electroencephalogram (EEG) and bilateral ulnar nerve somatosensory evoked potentials (SEP) were monitored from the beginning of the operation. Twenty five minutes after the scalp had been reflected anteriorly and a burr hole in the right frontal bone had been made, the patient had a sudden drop in end tidal CO₂ from 34 to 24 mmHg, followed by a drop in the systolic blood pressure from 140 to 40 mmHg. The anesthesiologists discontinued the nitrous oxide and began resuscitation with 100% FiO₂, intravenous fluids, and 3 consecutive doses of adrenaline intravenously (1mg, 0.5 mg and 0.75 mg) while the EEG and SEP flattened and the blood pressure remained low for more than 6 minutes. A right frontal ventriculostomy was placed immediately to rule out rebleeding, the intracranial pressure measured <25 mmHg and the surgeon ruled out this possibility. At 11 minutes into the event, the EEG began to gain amplitude and SEP activity returned but with delayed latency. An embolic event was suspected but due to the risks

of rupture of the aneurysm, it was decided to finish the clipping to protect the patient from a catastrophic hemorrhage and hyperbaric therapy was delayed to the end of the procedure. The surgery continued when blood pressure control was achieved, and an eight-mm right middle cerebral artery aneurysm was found and clipped through an extensive anterior skull-base approach. Two hours after the period of hypotension, the patient was transferred to the neurological intensive care unit (NCCU) for further management. The patient had remained stable hemodynamically but the SEP was still delayed and the amplitude of the EEG was still below basal readings under anesthesia.

On arrival to the NCCU, the patient was hemodynamically stable, on no vasopressors, CVP was 9 mmHg, her GCS was 7-T (E=1, V=T, M=5), and the pupils were equal and responsive to light. There was also a major drop in the PaO₂/FiO₂ ratio (P/F ratio = 155) without chest X-ray correlating pathology (see picture 1), increased base deficit, hypovolemia or hypotension. With the clinical diagnosis of venous air embolism and possible arterial gas embolism, the Hyperbaric Medicine team was consulted for urgent HBO₂ therapy. The hyperbaric team concurred with the diagnosis and the patient received a hundred percent oxygen in a US Navy table 6 in a large multiplace hyperbaric chamber, which allowed critical care personnel to be in attendance of a ventilated critically ill patient like this. The patient was readmitted to the ICU after the hyperbaric oxygen treatment without complications, obeying commands and moving all extremities with no apparent neurological sequelae (GCS 11-T, E=4, V=T, M=6) except for confusion evident after extubation (GCS 14, E=4, V=4, M=6). The P/F ratio had returned to normal (>500), and the awake patient was extubated successfully. Next morning, the post-op EKG was unchanged and serial cardiac enzymes were within the normal limits; a bubble contrast echocardiogram confirmed a patent foramen ovale. The patient was followed daily with daily transcranial Doppler (TCD) but she did not develop cerebral vasospasm and was transferred to the ward with a GCS 15 a few days later. During her stay in the hospital there were no further complications, and the patient was discharged home with no neurological deficits.

DISCUSSION

VAE has been treated with changes in position, fluids, vasopressors, G-suits, neck venous compression, and increased positive end expiratory pressure (PEEP), among others ⁸. However HBO₂, a less available or recognized

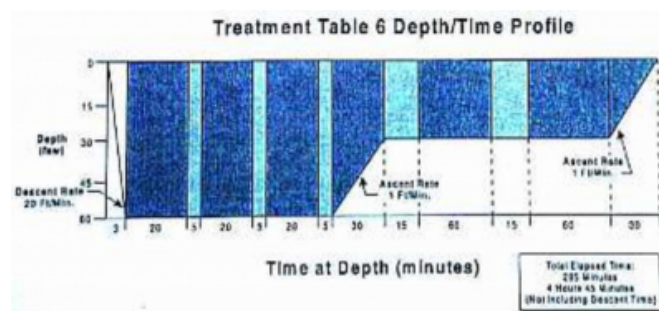
therapy, is the treatment of choice for air embolism of any origin ⁹. Its early use is definitely indicated for this disorder because supportive or pharmacological therapy alone will not decrease or resolve damage to the organs caused by the air emboli. HBO₂ benefits patients with air embolism by reducing the volume of the gas bubbles (Boyle's Law), relieving obstruction to blood flow, increasing oxygen delivery to the tissues and reducing the morbidity and mortality from inflammatory reaction and failure of the affected organs. In addition, it favors nitrogen diffusion (Henry's Law) from the bubbles with complete removal of the gas from the bubbles further reducing their size. Bert ¹⁰ suggested HBO₂ in the treatment of this complication for the first time in 1878.

In 1985, Murphy et al. ¹¹ reported 16 cases treated with HBO₂ over a period of 14 years. In 1987, Takahashi et al. ¹² reported 34 cases where HBO₂ was administered as the first choice. In their series there were 4 craniotomies in the sitting position; all patients suffered hypotension, 3 had altered mental status (coma), and 1 cardiac arrest. The patients were treated within 2 to 5 hours; however only 2 had good outcome. In 1990, Massey et al. ¹³ reported 14 patients with iatrogenic air embolism treated with HBO₂. No statistical difference in outcome was found between the groups treated early and late (after 24 hours). Since even some patients with greater than a 24 hours delay to treatment appeared to respond to HBO₂, the authors recommend HBO₂ even in the event of unavoidable treatment delay. In 1992, Pelaia et al. ¹⁴ reported 14 patients with arterial air embolism (AAE) during cardiopulmonary by-pass treated with U.S. Navy table 6A modified. The authors divided the patients in 2 groups, group A= < 5 hours to HBO₂ and group B= 24-48 hours to treatment. At 12 hours after the witnessed embolism episodes, the CT scans of the brain in 10 patients were normal, only 3 patients had severe brain edema. In 4 of the patients of group A, the CT scan of the brain showed focal areas of hypodensity without cerebral edema at 72 hours. The incidence of neurological symptoms in the group A was 40% versus 100% in the delayed therapy group. Interestingly at 3 months, the neurological recovery was complete in all group A patients; in contrast, all the patients in group B died within 20 days. The above series support the need for early HBO₂ therapy; however, delay even after 24 hours of therapy may still be beneficial ^{13,15}. Dexter and Hindman ¹⁶ when trying to answer the question of what volume of air is enough to trigger a hyperbaric treatment in patients with cerebral arterial air embolism during cardiopulmonary bypass found that, if the air bubbles are large enough to be

seen on CT scan of the brain, the air will not be absorbed for hours or days. They concluded that this population would benefit from delayed hyperbaric treatment.

Based on the above, we hypothesize that in our patient, early therapy prevented the neurological consequences of the VAE or PAE and corrected the ventilation/perfusion defect secondary to an increase in the dead space from the air in the pulmonary tree. The U.S. Navy table 6 (see figure 1) was used immediately after surgery was completed (2 hours from event)¹⁷. The maximum pressure was 2.8 atmospheres absolute (ATA); for 60 minutes with the patient breathing 100% FiO₂. After an ascent rate of 1 foot per minute, the patient was treated at 1.9 ATA for another 120 minutes. The total time of this treatment was 285 minutes not including descent time (see fig. 1).

Figure 1



Despite great concern of a PAE with irreversible neurological injury, at the end of the compression and hyperbaric treatment, the patient was neurologically intact and awake. Furthermore, the ventilation/perfusion abnormality seen before the compression to 2.8 ATA was completely resolved allowing immediate extubation.

The incidence of air embolism in patients undergoing cardiac surgery varies between 79% using transesophageal echocardiography¹⁸ to 100% using transcranial Doppler¹⁹ in open heart surgery; and as we mentioned previously, in 45% of the patients undergoing craniotomies in sitting position. Neurological deficits from small amounts of arterialized gas are rare, and we would not recommend HBO₂ for all patients in whom evidence of arterial bubbles is obtained with Doppler. However, for the 0.1% of patients who develop clinically significant arterial gas embolism during cardiopulmonary bypass²⁰ and the 1.5% who experience this complication during craniotomy¹¹, HBO₂ should be available as quickly as possible.

Anesthesiologists are exposed to more VAE cases than any

other health professional. Every day, anesthesiologists provide anesthesia for laparoscopy, neck dissection, neurosurgery, intravascular procedures, obstetrics, and others, including insertion of central venous lines. As anesthesiologists, the likelihood of being involved in such a case is high, and to know the role of HBO₂ in VAE, PAE or AAE as well as to have an institutional algorithm for emergencies is critical.

IMPORTANT NOTICE IN CASE OF EMERGENCY

A listing of HBO₂ chambers around the country is available from the Undersea & Hyperbaric Medical Society at (301) 942-2950. Alternatively, the Divers Alert Network (DAN) can provide information on the nearest chamber 24 hours per day at 1 (800) 446-2671.

References

1. Faberowski LW, Black S, Mickle P. Craniosynostosis: An Overview. *Am J Anesthesiology* 2000; 27(2):
2. Duke DA, Lynch JJ, Harner SG, Faust RJ, Ebersold. Venous Air Embolism in Sitting and Supine Patients Undergoing Vestibular Schwannoma Resection. *Neurosurgery* 1998; 42(6): 1286-7.
3. Lew TW, Tay DH, Thomas E. Venous Air Embolism During Cesarean Section: More Common Than Previously Thought. *Anesth Analg* 1993; 77(3): 448-52.
4. Kauffman BS, Kaminsky SJ, Rackow EC et al. Adult Respiratory Distress Syndrome Following Orofacial Sex During Pregnancy. *Crit Care Med* 1987; 15: 703-4.
5. Wesley EE, Hite RD, Baker AM, et al. Venous Air Embolism from Central Venous Catheterization: A Need for Increased Physician Awareness. *Crit Care Med* 1999; 27: 2113-2117.
6. Orebaugh SL. Venous Air Embolism: Clinical and Experimental Considerations. *Crit Care Med* 1992; 20:1169-1177.
7. Swartz MA, Munz M, Stern MB. Respiratory Failure Following Stereotactic Neurosurgery in a 53-year-old Woman. *Chest* 1997; 111: 112-114.
8. Palmon SC, Moore LE, Lundberg J, Toung T. Venous Air Embolism: A Review. *J Clin Anesth* 1997; 9(3): 251-7.
9. Undersea & Hyperbaric Medical Society, Committee Report. Revised 1999.
10. Bert P. Barometric Pressure: Researchers in Experimental Physiology. Columbus OH: College Book Company, 1943.
11. Murphy B. et al. Cerebral Air Embolism Resulting from Invasive Medical Procedures *Ann Surg* 1985; 201: 210-242.
12. Takahashi H, Kobayashi, H Sakakibara K: Iatrogenic Air Embolism: A Review of 34 Cases. (9th International Symposium on Underwater and Hyperbaric Physiology, Undersea and Hyperbaric Medical Society, Bethesda, MD, 1987; 931-948.
13. Massey EW, Moon RE, Shelton D, Camporesi EM. Hyperbaric Oxygen Therapy of Iatrogenic Air Embolism. *Journal of Hyperbaric Medicine* 1990; 5(1): 15-20.
14. Pelaia P, Rocco M, Volturo P, Conti G: Arterial Air Embolism during Cardiopulmonary Bypass: Twelve years experience. *Journal of Hyperbaric Medicine* 1992; 7(2): 115-1221.
15. Mader JT, Hulet WH: Delayed Hyperbaric Treatment of Cerebral Air Embolism. *Arch Neurol* 1979; 35: 504-505.

16. Dexter F, Hindman BJ. Recommendations for Hyperbaric Oxygen Therapy of Cerebral Air Embolism Based on a Mathematical Model of Bubble Absorption. *Anesth Analg* 1997; 84: 1203-7.
17. Navy Department. US Navy Diving Manual. Vol. 1 Revision 4, 1999.
18. Oka Y, Inoue T, Hong Y et al. Retained Intracardiac Air. Transesophageal Echocardiography for Definition of Incidence and Monitoring Removal by Improved Techniques. *J Thorac Cardiovasc Surg* 1986; 91(3): 329-38.
19. Van der Linden J, Casimir-Ahn H. When do Cerebral Emboli Appear During Open Heart Operations? A Transcranial Doppler Study. *Ann Thorac Surg* 1991; 51(2): 237-41.
20. Kol S, Ammar R, Weisz G, Malamed Y. Hyperbaric Oxygenation for arterial Embolism During Cardiopulmonary By-pass. *Ann Thorac Surg* 1993; 55(2): 401-3.

Author Information

Joseph L Nates, MD

Departments of Neurosurgery and Anesthesia/CCM/HBM, Health Science Center Medical School

Jaime Aristizabal, MD

Dong H Kim, MD

Caroline E Fife, MD