

Iatrogenic osteonecrosis of the lateral tibial plateau. A case report

A Sane, C Dieme, B Thiam, M Daffe, A Ndiaye, S Seye

Citation

A Sane, C Dieme, B Thiam, M Daffe, A Ndiaye, S Seye. *Iatrogenic osteonecrosis of the lateral tibial plateau. A case report.* The Internet Journal of Orthopedic Surgery. 2008 Volume 13 Number 2.

Abstract

Osteonecrosis is a rare and serious complication of surgical treatment of tibial plateau fractures. It is generally atraumatic even idiopathic. Authors report a case of iatrogenic osteonecrosis of the lateral tibial plateau of a 59 years-old diabetic man who presented a mixed tibial plateau fracture. They insist in two factors (local and general) for the prevention of this complication.

INTRODUCTION

The fractures of the tibial plateau are represented by all the articular fractures of the upper end of the tibia, except for the fractures of intercondylar eminence. Their surgical treatment profited from technical progress of the arthroscopy and the synthesis. Its complications are not rare. Epiphyseal necrosis, rare but serious, is often the fact of the complex depressions in mosaic .

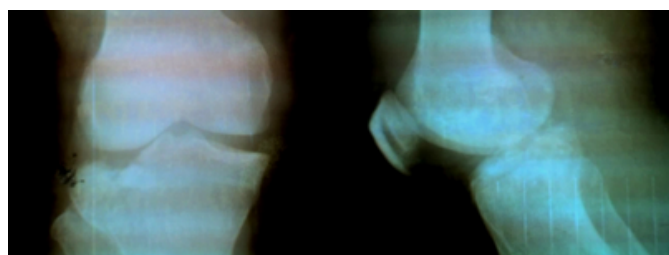
We present a case of idiopathic osteonecrosis of the lateral tibial plateau occurred at a well followed diabetic patient, after a classic synthesis of a tibial plate mixed fracture (separation and depression).

CASE REPORT

A 59 year old patient, diabetic type 2, presented after a traffic accident, a closed traumatism of the left knee. It was received 3 hours after its traumatism. The clinical and radiographic examination had found a mixed fracture (depression and separation) of the lateral tibial plateau without distal vascular and nervous attack (Figure 1).

Figure 1

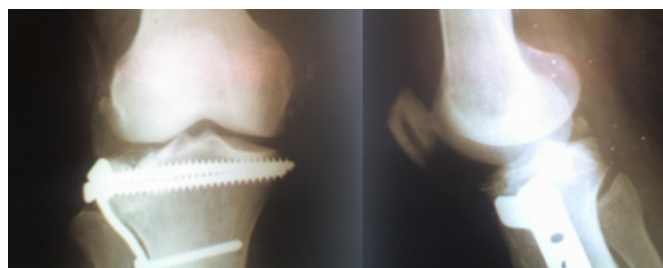Figure 1: Lateral mixed fracture of the left tibial plateau (anteroposterior and lateral views)



We performed the surgery 3 days after with an elevation, osseous grafting and fixation by L-plate. We used a lateral Gernez approach and a sub-meniscal arthrotomy to assess the quality of the reduction. Per-operative exploration had found no meniscal or ligamentous injury. The X ray control showed a satisfactory reduction (Figure 2).

Figure 2

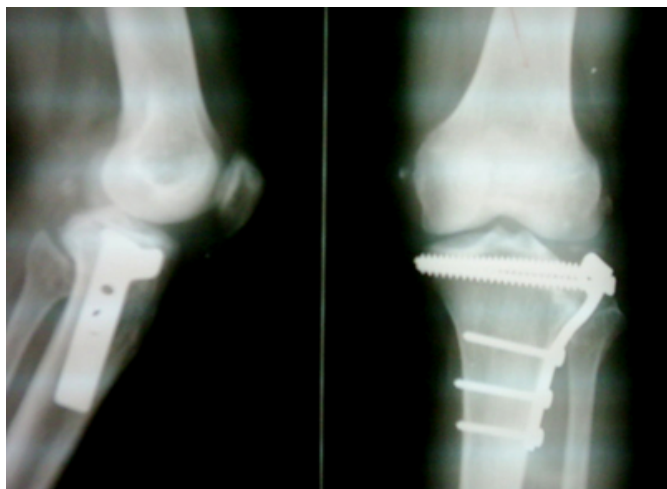
Figure 2: Post operative X rays (anteroposterior and lateral views)



The immediate post-operative evolution was without clinical and biological infection. Functional rehabilitation had been undertaken 15 days afterwards. At 1 year, the functional and anatomical evaluation had found a mechanical pain, a slight limping and a secondary depression of the elevated fragment (Figure 3).

Figure 3

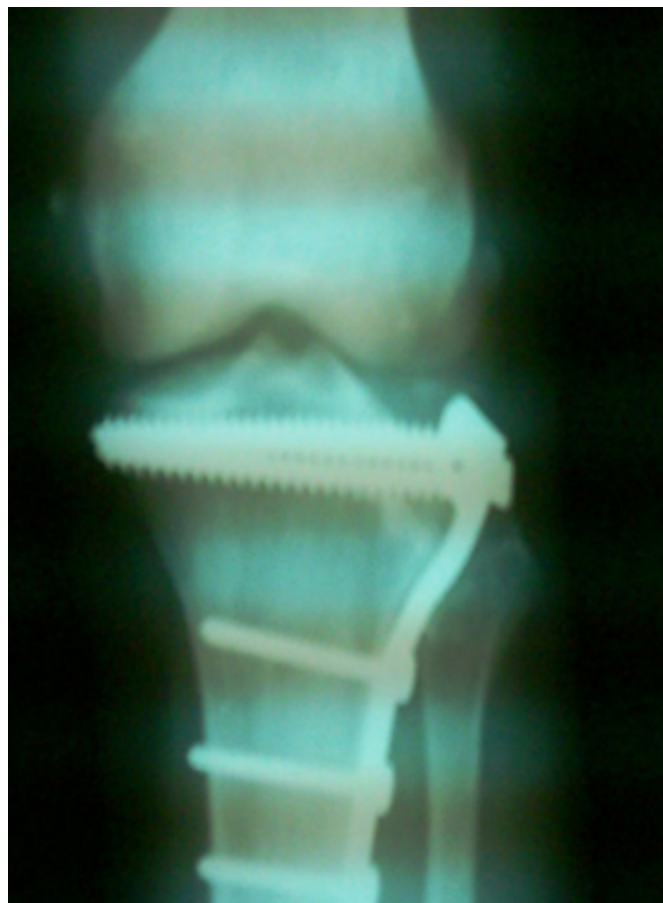Figure 3: X ray control (anteroposterior and lateral views) at 1 year of retreat showing a secondary depression of the elevated fragment



The last evaluation at 3 years of retreat had found an exacerbation of the pain and the slight limping with a perimeter of walk without pain lower than 100m, a lateral laxity in extension, a 0/0/135° mobility of the knee and a lateral tibial plate osteonecrosis (Figure 4).

Figure 4

Figure 4: X ray control (anteroposterior and lateral views) at 3 years of retreat showing lateral tibial plateau necrosis



A material removal associated with a bone puncture was proposed but refused by the patient. It was lost sight of the fact thereafter.

DISCUSSION

The first description of the osteonecrosis of the tibial plate is allotted, in french literature to Angelejan in 1976 and later in english literature to Houpt [51]. The primary form known as idiopathic or spontaneous was largely published contrary to the secondary form [26].

Narvaez and al. tried to work out criteria making it possible to make the difference between the primary and the secondary forms [6]. The idiopathic osteonecrosis occurs without any risk factors while the secondary osteonecrosis would be caused by a number of well-known predisposing factors acting alone or in concert. These risk factors can be local, such gravity of the injuries and the aggressiveness of the surgical treatment, and/or general like the age, osteoporosis, metabolic diseases and the steroid therapy [38]. Therefore there would be significant differences between

these 2 forms especially in the clinical presentation, the location and the extension of the necrosis as well as aspects with the MRI [68]. That is due to a difference of the pathogenic mechanism.

The medial tibial plate, more often reached, is the prerogative of the primitive form. When the necrosis occurs on the lateral tibial plate, the secondary aetiology is strongly suspected. Occurred of one necrosis after a surgical treatment is rare [3412]. It is explained by the difficulties of the surgical treatment of the fractures of the upper end of the tibia related to necrosis of a devitalized fragment [512]. This necrosis is often ignored and allotted to the failure of synthesis [312]. Recently Johnson and al. described occurred of necrosis tibial plate after arthroscopic surgery for meniscal lesions [4].

Its late diagnosis explains the need for a confirmation [3710]. Before the anatomopathological examination and after the bone scintigraphy or bone scan, the MRI is currently the most significant and most specific examination [1245811]. The histological confirmation is sometimes difficult to have [811]. The evolution of necrosis is variable, often pejorative with a progressive aggravation [89]. It was initially appreciated starting from a modification with the knee of the classification of Arlet and Ficat [11]. Carpintero and al. [4] proposed a radiological staging with histological proof whereas Lonner and al. [5] classify necrosis according to the spectrum of subchondral changes observed with the MRI.

The treatment of the osteonecrosis goes from bone grafting, tibial osteotomy to the knee replacement, total or unicompartmental, to measure [7, 9, 10, and 11]]. The management of predisposing factors, local and general, in the secondary forms must allow the reduction of which has occurred necrosis it [3468].

CONCLUSION

The fractures of the tibial plateau are a current pathology in

trauma department. Occurred of complication is often due to the surgical gesture. Osteonecrosis is a rare form whose prevention passes by the correct management of general but especially local factors.

References

1. Carpintero P., Leon F., Zafra M., Montero R., Carreto A. Spontaneous collapse of the tibial plateau : radiological staging
Skeletal Radiol, 2005, 34(7): 399-404
2. Carpintero-Benitez P., Collantes-Estevez E. Osteonecrosis of the tibial plateau
Clin Rheumatol, 1998, 17 : 95-98
3. Duparc J., Cavagna R. Résultats du traitement opératoire des fractures des plateaux tibiaux (à propos de 110 cas)
Int Orthop, 1987, 11(3) : 205-13
4. Johnson T.C., Evans J.A., Gilley J.A., DeLee J.C. Osteonecrosis of the knee after arthroscopic surgery for meniscal tears and chondral lesions
Arthroscopy, 2000, 16(3) : 254-261
5. Lonner J.H., Lotke P.A. Tibial osteonecrosis
Instr Course Lect, 2001, 50 : 477-81
6. Narvaez J., Narvaez J.A., Rodriguez-Moreno J., Roig-Escofet D. Osteonecrosis of the knee : differences among idiopathic and secondary types
Rheumatology, 2000, 39 : 982-989
7. Nourissat Ch., Barba L. Chambaud D., Gacon G. Prothèse unicompartimentaire et nécrose idiopathique du plateau tibial interne
Rev Chir Orthop, 2001, 87 : 367-372
8. Pollack M.S., Dalinka M.K., Kressel H.Y., Lotke P.A., Spritzer C.E. Magnetic resonance imaging in the evaluation of suspected osteonecrosis of the knee
Skeletal Radiol, 1987, 16(2) : 121-7
9. Satku K., Kumar V.P., Chong M., Thambyah A. The natural history of spontaneous osteonecrosis of the medial tibial plateau
J Bone J Surg, 2003, 85-B(7) : 983-988
10. Schindler O.S., Misra R., Spalding T.J.W. Osteonecrosis of the medial tibial plateau : a case report
J Orthop Surg, 2006, 14(3) : 325-329
11. Valenti Jr, Illescas Ja, Barriga A., Dolz R. Idiopathic osteonecrosis of the medial tibial plateau
Knee Surg Sports Traumatol Arthrosc, 2005, 13(4): 293-298
12. Vielpeau C., Locker B., Seite G. Les difficultés du traitement chirurgical des fractures bitubérositaires complexes
Rev Chir Orthop, 1989, 7(3) : 140-3

Author Information

André-Daniel Sane, PhD

Orthopaedic and Trauma department, Aristide Le Dantec teaching hospital, Dakar – SÉNÉGAL

Charles Bertin Dieme

Professor, Orthopaedic and Trauma department, Aristide Le Dantec teaching hospital, Dakar – SÉNÉGAL

Babacar Thiam

Orthopaedic surgeon, Orthopaedic and Trauma department, Aristide Le Dantec teaching hospital, Dakar – SÉNÉGAL

Mohamed Daffe

Senior resident, Orthopaedic and Trauma department, Aristide Le Dantec teaching hospital, Dakar – SÉNÉGAL

Abdoulaye Ndiaye

Associate Professor, Orthopaedic and Trauma department, Aristide Le Dantec teaching hospital, Dakar – SÉNÉGAL

Seydina Issa Laye Seye

Professor and chairman, Orthopaedic and Trauma department, Aristide Le Dantec teaching hospital, Dakar – SÉNÉGAL