Bilateral Accessory Breast

S Sahu, M Husain, P Sachan

Citation

S Sahu, M Husain, P Sachan. *Bilateral Accessory Breast*. The Internet Journal of Surgery. 2007 Volume 17 Number 2.

Abstract

Accessory breasts or polymastia occur in 0.4-6 per cent of women and 1-3% of males. They can consist of any or all components of the breast and may be functional or non-functional. Approximately 67% of accessory breast tissue occurs in the thoracic or abdominal portions of the milk line, often just below the inframammary crease and more often on the left side of the body. Another 20% occur in the axilla. We report a case of bilateral axillary accessory breast. Excision was done under general anesthesia.

INTRODUCTION

The mammary glands are a distinguishing feature of mammals beginning their development early in the embryologic life. At 5 weeks of embryologic development, ectodermal mammary streaks extend bilaterally from axilla to groin. Two weeks later, a mammary ridge or milk line develops in the thoracic portion of the primitive streaks and begins to proliferate as a primary mammary bud. This primary bud subsequently begins growth downward as a solid diverticulum into the underlying dermis during the seventh week. By the 10th week, the primary bud begins to branch, yielding secondary buds by the 12th week, which eventually develop into the mammary lobules of the adult breast. Further differentiation into complete breast parenchyma occurs during the remainder of gestation. The remainder of the mammary streak usually regresses; however, incomplete involution can result in foci of accessory breast tissue anywhere along the line that extends from axilla to groin. [1]

CASE REPORT

A 28-year-old married female presented with a history of painless bilateral axillary swellings since birth. She noticed an increase in size and pain in both the swellings during pregnancy. Her left axillary swelling started secreting milk during the post-partum period. Examination of both axillas revealed a non-tender, soft and freely mobile swelling placed in the subcutaneous plane. Nipple and areolar complex were seen in both the axillary swellings but were more prominent in the left side. Milk could be expressed from the left axillary swelling (FIG. 1, FIG. 2, FIG. 3).

Figure 1

Figure 1: Bilateral Axillary Accessory Breast

Figure 2

Figure 2: Right Axillary Accessory Breast

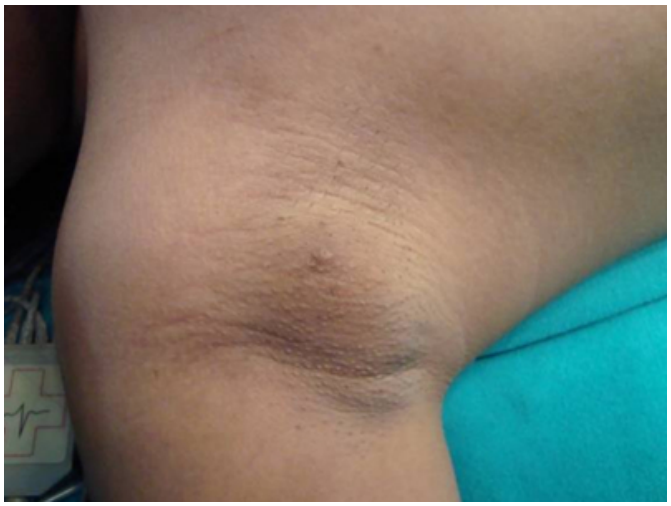

Figure 3

Figure 3: Left Axillary Accessory Breast

The swellings were excised under general anesthesia. On excision of the left accessory axillary breast, milk was found oozing from the line of incision (FIG. 4).

Figure 4

Figure 4: Milk Oozing From The Line Of Incision In The Left Axiilary Accessory Breast

The patient had an uneventful postoperative recovery.

DISCUSSION

Accessory breasts or polymastia occur in 0.4-6 per cent of women and 1-3% of males. They can consist of any or all components of breast and may be functional or non-functional. Approximately 67% of accessory breast tissue occurs in the thoracic or abdominal portions of the milk line, often just below the inframammary crease and more often on the left side of the body. Another 20% occur in the axilla. The remaining locations include anywhere along the milk line. Supernumerary tissue present in any location other than along the milk line represents a migratory arrest of breast primordium during chest wall development and is termed ectopic breast. Aberrant or ectopic breast tissue has been reported to arise from extra sites, including the face, posterior neck, chest, buttock, vulva, hip, shoulder, posterior and/or lateral thigh, perineum, as well as the midback. Rarely bilateral accessory breasts are also reported. [2,3,4,5,18]

In 1915, Kajava published a classification system for supernumerary breast tissue that remains in use today. Class I consists of a complete breast with nipple, areola, and glandular tissue. Class II consists of nipple and glandular tissue but no areola. Class III consists of areola and glandular tissue but no nipple. Class IV consists of glandular tissue only. Class V consists of nipple and areola but no glandular tissue (pseudomamma). Class VI consists of a nipple only (polythelia). Class VII consists of an areola only (polythelia areolaris). Class VIII consists of a patch of hair only (polythelia pilosa). The accessory tissue may range from a subcutaneous focus of breast tissue to a full accessory

breast complete with areola and nipple. The presence of a small nipple is the most frequently noted accessory breast structure. [6,7]

Accessory breast tissue is usually sporadic but familial cases are also reported. They respond to hormonal stimulation and may become more evident during menarche, pregnancy, or lactation. In the absence of areola and nipple, the diagnosis is rarely made clinically although there may be a palpable fullness in the area. Fullness may wax and wane with the menstrual cycle or may manifest during pregnancy and lactation. Discomfort, anxiety, pain, restriction of arm movement, milk secretion, and local skin irritation can occur. Both benign and malignant diseases of accessory breast tissue as in normal breast have been described. Cases of accessory or ectopic breast with benign cystic changes, benign tumors (adenomas and fibroadenomas) and carcinoma are documented. Ductal carcinoma is the most frequent subtype reported. Medullary breast cancer, cystosarcoma phylloides, extramammary Paget's disease, and papillary carcinoma have all been reported in accessory mammary tissue. Sentinel node biopsy is effective in accurately determining the staging of cancer in accessory breast tissue. Because the lymphatic drainage from ectopic breast tissue is unclear, blind dissection of areas such as the axilla can result in considerable morbidity, including intercostobrachial nerve injury, incomplete excision of the accessory tissue, poor wound healing, and lymph edema of the arm. [2,3,8,9,10,11,14,16,17]

Misdiagnosis of accessory breast tissue is common and the most common presumptive diagnoses include lipoma, lymphadenopathy, hidradenitis, sebaceous cyst, vascular malformation, and malignancy. If doubt exists as to the nature of the tissue, mammography, needle biopsy, or surgical biopsy of the area should be undertaken. On mammography, accessory breast tissue in the axilla resembles normal glandular parenchyma and is separate from the breast, unlike the axillary tail of Spence, which is a normal direct extension toward the axilla from the main breast tissue. Cystic or adenomatous changes in the ectopic mass may also be evident on sonography imaging. The MRI appearance is that of a subcutaneous poorly demarcated mass discontinuous with — but having signal intensity and contrast enhancement characteristics similar to — normal breast tissue. [5,12,13]

The treatment of choice for symptomatic accessory axillary breast tissue is surgical excision. Cosmesis is the main indication in the majority of cases. Removal of the tissue will relieve the physical discomfort and also confirms the diagnosis. Liposuction as an alternative if this option is feasible. [3,15]

CORRESPONDENCE TO

Dr. Shantanu Kumar Sahu Assistant Professor, Department of General Surgery Himalayan Institute of Medical Sciences Swami Ram Nagar Post- Doiwala Dehradun Uttarakhand, India Mob.: 0-9412933868 Email: lntshantanu@yahoo.co.in

References

1. Bland KI, Romrell LJ: Congenital and acquired disturbances of breast development and growth. The Breast: Comprehensive Management of Benign and Malignant Diseases. Bland KI, Copeland EM III (eds). Philadelphia, WB Saunders, 2nd Ed., 1998; pp 214-232.
2. Scanlan KA, Propeck PA. Accessory breast tissue in an unusual location. AJR 1996; 166:339-340.
3. Lesavoy MA, Gomez-Garcia A, Nejdl R, Yospur G, Syiau TJ, Chang P. Axillary breast tissue: clinical presentation and surgical treatment. Ann Plast Surg 1995; 35:356-360.
4. Bertschinger K, Caduff R, Kubik-Huch RA. Benign intramammary and axillary lesions mimicking malignancy. Eur Radiol 2000; 10:1029-1030.
5. Adler DD, Rebner M, Pennes DR. Accessory breast tissue in the axilla: mammographic appearance. Radiology 1987; 163:709-711.
6. Kajava Y. The proportions of supernumerary nipples in the Finnish population. Duodecim 1915; 31:143-170.
7. Haagensen CD. Diseases of the Breast, 3rd ed., Philadelphia: Saunders, 1986; pp. 5-7.
8. Brightmore TGJ: Cystic lesion of a dorsal supernumerary breast in a male. Proc R Soc Med 1971; 64:662-663.
9. O'Hara MF, Page DL: Adenomas of the breast and ectopic breast under lactational influences. Hum Pathol 1985; 16:707-712.
10. Hassim AM: Bilateral fibroadenoma in supernumerary breasts of the vulva. J Obstet Gynaecol Br Commonwealth 1969; 76:275-277.
11. Vargas J, Nevado M, Rodriguez-Peralto JL, et al: Fine-needle aspiration diagnosis of carcinoma arising in an ectopic breast: a case report. Acta Cytol 1995; 39:941-944.
12. Yang WT, Suen M, Metreweli C. Mammographic, sonographic and histopathological correlation of benign axillary masses. Clin Radiol 1997; 52:130-135.
13. Laor T, Collins MH, Emery KH, Donelli LF, Bove KE, Ballard ET. MRI appearance of accessory breast tissue: a diagnostic consideration for an axillary mass in a peripubertal or pubertal girl. AJR 2004; 183:1779-1781.
14. Alghamdi H. Accessory breasts: When to excise? Breast J 2005; 11:155-7.
15. Hardikar JV, Nadkarni SV. Polymastia of axilla (a case report). J Postgrad Med 1984; 30:53.
16. Thorne AL, Jackson A, Yiangou C. The use of sentinel node biopsy in the treatment of cancer of an accessory breast. Breast 2003; 12:153-5.
17. Down S, Barr L, Baildam AD, Bundred N. Management of accessory breast tissue in the axilla. Br J Sur 2003; 90:1213-4.
18. Pathak S, Preston J. A rare case of multiple accessory breast tissue in the axillae, lower abdomen and vulval areas. J Obstet Gynaecol. 2007; 27:531-3.

Author Information

Shantanu Kumar Sahu, MS (General Surgery)
Assistant Professor, Department of General Surgery, Himalayan Institute of Medical Sciences

Musharraf Husain, MS (General surgery), DNB (General Surgery), MRCS (Edin.)
Assistant Professor, Department of General Surgery, Himalayan Institute of Medical Sciences

Praveendra Kumar Sachan, MS (General Surgery)
Professor and Head, Department of General Surgery, Himalayan Institute of Medical Sciences