

Coronary Artery Dissection Associated with Exercise Myocardial Perfusion Scintigraphy

Q Chiam, C Bui, R Mansberg, D Nguyen, M Patel

Citation

Q Chiam, C Bui, R Mansberg, D Nguyen, M Patel. *Coronary Artery Dissection Associated with Exercise Myocardial Perfusion Scintigraphy*. The Internet Journal of Nuclear Medicine. 2006 Volume 4 Number 1.

Abstract

Exercise myocardial perfusion scintigraphy (MPS) is commonly performed to assess for ischaemic heart disease. The risks of MPS are primarily related to those of an exercise stress test (EST). The overall cardiac complication rate from maximal EST is very low and is estimated at 0.8 complications per 10, 000 tests¹. Spontaneous coronary artery dissection (SCAD) is an infrequent cause of acute myocardial ischaemia with fewer than 300 cases described in the literature². We describe a male patient with acute myocardial infarction from SCAD associated with MPS.

CASE REPORT


A 72-year-old man presented with recent onset of brief episodes of nocturnal crushing central chest pain. He had been generally well and active (undertaking regular walking exercise). Apart from age, his only other cardiac risk factor was previous heavy smoking history. He reached stage IV of conventional Bruce-protocol treadmill EST with total exercise duration of 9 min 30 sec, peak heart rate of 150 bpm (105% of predicted maximum heart rate (PMHR)) without chest pain. Stress ECG response was mildly abnormal with ST depression up to 1 mm at V4-V6.

Further evaluation with rest/stress Tc-99m sestamibi MPS was performed 10 days later using a one-day protocol. He exercised on the treadmill using the same Bruce protocol for 6 minutes attaining a heart rate of 132 bpm (89% PMHR) with appropriate rise in blood pressure up to 170/80 mmHg. The test was terminated due to dyspnoea, fatigue and satisfactory heart rate response. The stress ECG showed equivocal abnormal response with slowly upsloping ST depression up to 1 mm in V3-V6, which normalised in recovery.

Stress / rest SPECT images revealed a moderate sized, mainly fixed inferior perfusion defect from apex to base, of mild to moderate severity (green arrows, Fig. 1). Post-stress gated SPECT demonstrated normal-sized left ventricle with satisfactory wall motion and thickening. LVEF = 60%. The appearances could represent attenuation artefact in the inferior wall although a prior non-transmural myocardial

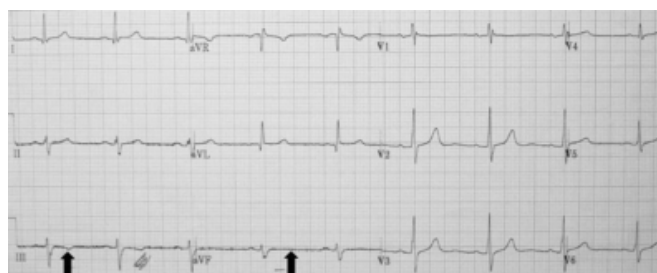infarct at this site could not be entirely excluded. No significant inducible myocardial ischaemia was evident.

Figure 1



The patient reported no chest discomfort during or immediately after stress testing. Approximately 3-4 hours later, he experienced worsening episodes of crushing central chest pain of similar quality to recent nocturnal chest pain and eventually represented to the Emergency Department in the early evening. The initial ECG showed no acute changes. Subsequent serial ECGs showed new T wave abnormalities in leads III and AVF (blue arrows, Fig. 2).

Figure 2

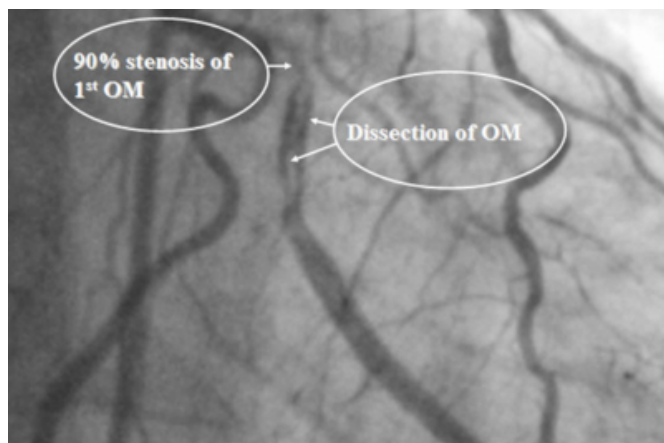


Acute myocardial infarction was confirmed by elevated creatinine phosphokinase up to 2331 U/L (0-195), and elevated troponin T from 0.17 initially up to 2.5 µg/L

(0.00-0.05) over the subsequent 24 hours (the troponin T level was < 0.01 µg/L 2 weeks previously with the initial onset of chest pain). He was treated with aspirin, clopidogrel and low molecular weight heparin.

Coronary angiography performed 3 days later demonstrated 90% stenosis in the true lumen of the 1st obtuse marginal artery branch (1st OM) of the left circumflex artery (LCX) followed immediately by a segment of dissection with good distal run-off (Fig. 3). The anterolateral wall was hypokinetic consistent with myocardial infarction. The right coronary artery (RCA) was dominant with a 50% proximal stenosis. The proximal left anterior descending artery (LAD) demonstrated diffuse 10% stenosis. The patient was managed medically and made uneventful recovery.

Figure 3



DISCUSSION

SCAD is a very rare condition that occurs predominantly in young healthy women during pregnancy or in the postpartum period, or patients with atherosclerotic coronary artery disease^{2, 3}. Sporadic cases have been reported in patients with defective collagen metabolism, immunologic/inflammatory disorders, on certain drugs (such as oral contraceptives, cyclosporin, cocaine) and after vigorous physical exercise^{2, 3, 4}.

SCAD results from an intramural haematoma in the media of the arterial wall that creates a false lumen. Expansion of this lumen with blood or clot accumulation leads to compression of the real lumen and myocardial ischaemia. Primary disruption of the vasa vasorum and subsequent haemorrhage into the media of the arterial wall has been proposed as the most common underlying mechanism of SCAD. An intimal tear as the initial event is only seldom observed⁵. The LAD

is the most frequently involved vessel (66%) followed by the RCA (25%) and LCX (7%). Involvement of the left main artery and multiple dissections are seen in less than 10% of cases².

SCAD may manifest clinically as stable or unstable angina, acute myocardial infarction, cardiogenic shock and sudden cardiac death. The prognosis is governed by the extent of the coronary involvement. Spontaneous resolution of SCAD is also recognized. Treatment of SCAD is controversial and depends on the location and extension of dissection, and other clinical parameters. Medical therapy may be appropriate for patients with no ongoing ischaemia and no haemodynamic instability. Revascularisation may be required for patients with extensive disease or symptoms refractory to medical therapy².

In conclusion, the presence of concomitant atheromatous disease in other coronary arteries suggests plaque rupture leading to coronary dissection associated with exercise as the possible underlying mechanism of the acute coronary syndrome in this patient. Alternative explanations include co-incidental acute coronary syndrome that occurred after the exercise stress test or followed from pre-existing coronary dissection that may have occurred with the initial recent onset nocturnal crushing central chest pain.

CORRESPONDENCE TO

Department of Nuclear Medicine Nepean Hospital Penrith
2751 New South Wales Australia Telephone: 61 2 4734
2156 Facsimile: 61 2 4734 1348 Email:
mansberg@mail.usyd.edu.au

References

1. Gibbons L, Blair SN, Kohl HW, Cooper K. The safety of maximal exercise testing. *Circulation* 1989;80:846-852.
2. Verma PK, Sandhu MS, Mittal BR, Aggarwal N, Kumar A, Mayank M, et al. Large spontaneous coronary artery dissections, a study of three cases, literature review, and possible therapeutic strategies. *Angiology* 2004;55:309-318.
3. Celik SK, Sagcan A, Altintig A, Yuksel M, Akin M, Kultursay H. Primary spontaneous coronary dissection in atherosclerotic patients. Report of nine cases with review of the pertinent literature. *Eur J cardiothorac Surg* 2001;20:573-576.
4. Maraj R, Fraifeld M, Owen AN, Kotler MN, Yazdanfar S. Coronary dissection and thrombosis associated with exercise testing three months after successful coronary stenting. *Clin Cardiol* 1999;22:426-428.
5. Conrads VM, Vorlat A, Colpaert CG, Rodrigus IE, De Paep RJ, Moulijn AC, et al. Spontaneous dissection of three major coronary arteries subsequent to cystic medial necrosis. *Chest* 1999; 116: 1473-1475.

Author Information

Quee Li Chiam, MB BS RANZCR

Department of Nuclear Medicine, Nepean Hospital Penrith

Chuong Bui, MB BS FRACP

Department of Nuclear Medicine, (Discipline Medicine), Nepean Hospital Penrith, (University Sydney)

Robert Mansberg, MB BS FRACP

Department of Nuclear Medicine, (Discipline Medicine), Nepean Hospital Penrith, (University Sydney)

Diep Nguyen, MB BS FRACP

Department of Nuclear Medicine, (Discipline Medicine), Nepean Hospital Penrith, (University Sydney)

Manish Patel, MB BS FRACP

Department of Cardiology, Nepean Hospital Penrith