

# Evacuation Of Fourth Ventricle Hematoma Without Hydrocephalus: Case Report

E Özer,, K Yücesoy, M Senoglu, G Citak, C Yurtsever

## Citation

E Özer,, K Yücesoy, M Senoglu, G Citak, C Yurtsever. *Evacuation Of Fourth Ventricle Hematoma Without Hydrocephalus: Case Report*. The Internet Journal of Neurosurgery. 2004 Volume 2 Number 1.

## Abstract

Massive fourth ventricle hemorrhage obstructs cerebrospinal fluid pathways and can also cause compression of the brain stem. In this report, a 5-year-old girl with fourth ventricle haemorrhage compressing the brain stem is presented. The fourth ventricle haemorrhage was evacuated surgically and the patient showed significant postoperative improvement. Massive fourth ventricle hemorrhage can directly cause brain stem compression and result in poor neurological status without significant contribution from a hydrocephalus. In the presence of brain stem compression, fourth ventricle hemorrhage should be considered for operative evacuation.

This study was performed at Department of Neurosurgery, Dokuz Eylül University Medical Faculty, Izmir-Turkey

## INTRODUCTION

Spontaneous intraventricular haemorrhage is associated with a large number of disorders like aneurysm, hypertension, arteriovenous malformation, tumour and coagulopathies and occurs primarily or in association with intraparenchymal and/or subarachnoid hemorrhage (<sup>9,10,11,12,13,14</sup>). It is a negative outcome predictor for patients with intracerebral and subarachnoid hemorrhages (<sup>2,8, 12,18</sup>). Intraventricular haemorrhages are generally treated with fibrinolytic agents (<sup>15, 16, 17</sup>). There are various other options for treatment of intraventricular hemorrhage but clot-forming packed hemorrhages cause difficulty in management. In the case of a massive fourth ventricle hemorrhage, there may be brain stem compression in addition to CSF pathway obstruction (<sup>1, 2</sup>).

In this article, we report a case of fourth ventricle hematoma which was evacuated surgically because of brain stem compression and in which the evacuation resulted in significant post-surgical improvement.

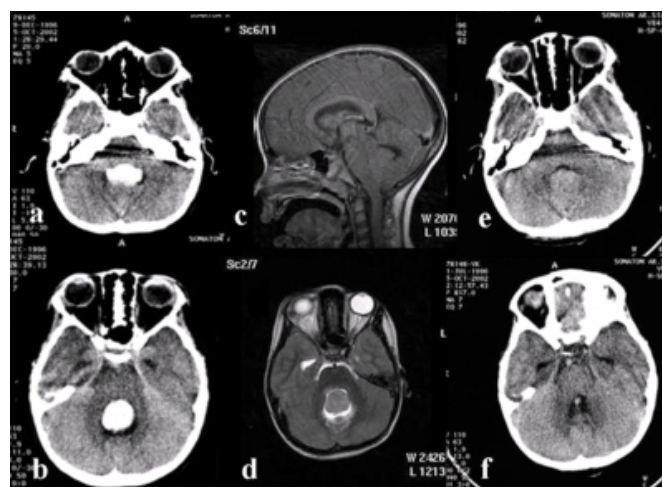
## CASE REPORT

A 5-year-old girl was admitted to a local hospital's emergency department after sudden loss of consciousness. There, a computerised tomography scan was taken which revealed massive intraventricular hemorrhage. The patient was transferred to our hospital. At admission, she was

comatose and didn't open her eyes or follow verbal commands. Painful stimuli caused flexion withdrawal. A CT scan was repeated. Massive fourth ventricle hemorrhage with an anteroposterior diameter of 2.2 cm causing hemorrhagic dilation of the fourth ventricle was shown on the CT (Figures 1a and b).

## Figure 1

Figure 1: CT examinations of massive hemorrhage of fourth ventricle compressing the brain stem (1a and b), there is minimal ventricular enlargement as seen in temporal horns. Sagittal T1 weighted (a) and axial T2 weighted MR images reveal haemorrhage filled fourth ventricle. MRI excluded any vascular abnormality. Figures 1 e and f demonstrate surgical evacuation of haemorrhage and decreased size of ventricles on postoperative CT scans.



There were also hemorrhages in the third and lateral

ventricles bilaterally but in lesser amounts. The hemorrhage also caused minimal ventricular dilation. MRI demonstrated the same findings excluding any vascular abnormality as could be seen (Figures 1b and 1c). An angiographic investigation was planned but the patient showed neurological deterioration and suffered respiratory arrest. Upon deterioration, she was intubated and it was decided that evacuation of the fourth ventricle hemorrhage would be appropriate because there was no significant dilation of ventricles to cause any neurological deterioration. Also, the hemorrhage was large enough to compress the brain stem and cause respiratory arrest.

The patient was taken to the operating room. In the prone position, through a midline incision, a median suboccipital craniectomy and C1 laminectomy were performed. After opening the dura and arachnoid of the systema magna, the hematoma was evacuated easily in the form of a large clot and adequate flow of CSF through the aqueductus was established. The dura was closed using a synthetic patch graft. After the operation the patient was transferred to the intensive care unit. The patient's neurological status quickly improved following the operation; she opened her eyes to verbal stimuli and followed commands on the first postoperative day. Control CT scans on the 2nd postoperative day showed complete removal of the clot and decreased size of ventricles compared with their preoperative size (figures 1e and f). Weaning from the ventilator was planned but unfortunately the patient developed a high fever and tachycardia, a few days after the operation, and CSF examination showed CSF infection. Administration of broad spectrum antibiotics was started to treat the infection. During the course of the infection, hydrocephalus also developed and external ventricular drainage was performed. When the response of the patient to the antibiotics delayed, the dural patch was considered as a source of infection and removed. Infection caused deterioration of the patient's current neurological status and she became unresponsive to verbal stimuli. When the infection was under control, a ventriculo-peritoneal shunt was placed. When the patient was stabilised, digital subtraction angiography was performed and it revealed normal vasculature. After completion of her treatment, she was transferred to physical rehabilitation unit.

### DISCUSSION

Massive fourth ventricle hemorrhage can cause brain stem compression and poor neurological status without significant effect from hydrocephalus. Little attention has been paid to

the presence of blood in the fourth ventricle and its effects on surrounding ependyma and the brain stem rather than CSF pathways. Shapiro et al (2) addressed this issue and made an analysis of 50 cases with fourth ventricle hemorrhage to assess the nature of it. They introduced a new CT description "hemorrhagic dilation" in patients with fourth ventricle hemorrhage and defined it as a clot filling the entire ventricle with no surrounding CSF when the antero-posterior diameter was greater than 1.25 cm. and/or the lateral diameter was greater than 2.0 cm. All of the patients having hemorrhagic dilation suffered from brain death within 48 hours of onset despite ventricular drainage, ICP monitoring and aggressive care. Autopsy studies of three patients showed multiple brain stem microinfarcts most likely caused by compression from hematoma. They suggested that hemorrhagic dilation is an ominous finding and external ventricular drainage alone has no impact on outcome. Indeed, ventriculostomy aims to decompress enlarged ventricles but it is the hematoma itself which compresses the underlying brain stem.

Fourth ventricle hematomas should be considered for evacuation if they cause hemorrhagic dilation as detected on CT scan. Lesions like cerebellar infarcts, hemorrhages causing posterior fossa mass effect and alteration of consciousness are clear indications for suboccipital craniectomy and removal of the mass (20,21,22,23,24,25,26). A hematoma filling and enlarging the fourth ventricle could cause similar mass effect and may be considered to be like other posterior fossa masses, and should be evacuated in the presence of haemorrhagic dilation rather than external ventricular drainage (1). Endoscopic or open surgical intervention for removal of supratentorial intraventricular hematomas have been reported (3,4,5,6,7,19) but only a unique case of fourth ventricle hematoma removal is present in the literature. This was the case of a 45-year-old woman suffering from aneurysmal subarachnoid hemorrhage filling the fourth ventricle. In our case, massive hematoma filling the fourth ventricle and causing brain stem compression and resultant respiratory arrest forced us to evacuate the clot. Also, the absence of gross ventricular enlargement was indicative of brain stem compression, and so indicated that the major contribution to the patient's poor neurological status was brain stem compression. We think, the presence of hydrocephalus should not be an indicator of only external ventricular drainage and operative removal of clot should also be considered in fourth ventricle haemorrhages causing haemorrhagic dilation, because it's clear that external drainage of obstructed CSF is not sufficient to prevent

damage by a fourth ventricle hemorrhage to the brain stem.

Although this is not the case in our patient, fourth ventricle clot evacuation may also prevent development of hydrocephalus in addition to decompressing the brain stem. Hydrocephalus can be managed with external ventricular drainage and shunting but evacuation of hematoma may open CSF pathways. But it is not always possible to prevent development of ventricular dilation with hematoma evacuation because hematoma also causes absorption failure instead of obstruction as in the reported case of hematoma removal by Lagares et al (1), and shunting then is needed. Despite this, evacuation of fourth ventricle hematoma to prevent hydrocephalus and avoid the need for shunting should also be one of the future considerations in these cases.

Massive hematoma of the fourth ventricle may cause brain stem compression and poor neurological status without significant contribution from hydrocephalus. Although a favourable outcome is not the case in our patient due to central nervous system infection, these patients should be considered for treatment with clot evacuation.

### CORRESPONDENCE TO

Dr. Ercan ÖZER DEÜTF Nöroşirürji AD 35340 Inciralti – Izmir – Turkey Phone : 90 (232) 412 3309 Fax : 90 (232) 278 8802 E-mail : ercozer@yahoo.com

### References

1. Lagares A, Putman CM, Ogilvy CS. Posterior fossa decompression and clot evacuation for fourth ventricle hemorrhage after aneurysmal rupture: case report. *Neurosurgery* 2001; 49:208-211
2. Shapiro SA, Campbell RL, Scully T. Hemorrhagic dilation of fourth ventricle. *J Neurosurg* 1994 ; 80:805-809
3. Fuentes S, Metellus P, Dufour H, et al. Endoscopic third ventriculostomy for management of obstructive hydrocephalus secondary to supratentorial intraventricular hematoma. Case report. *Neurochirurgie* 2002; 48(6):510-5
4. Strowitzki M, Kiefer M, Steudel WI. A new method of ultrasonic guidance of neuroendoscopic procedures. Technical note. *J Neurosurg* 2002 ; 96(3):628-32
5. Onoda K, Kurozumi K, Tsuchimoto S, Satoh T. Experience with the high occipital transcortical approach in the treatment of intraventricular hemorrhage. Report of two cases. *J Neurosurg* 2001; 94(2):315-7
6. Anzai K, Kamiyama K, Sasaki T, Nakamura H. Endoscopic evacuation of intraventricular hematoma and third ventriculostomy (Abstract) *No Shinkei Geka* 2000; 28(7):599-605
7. Horvarth Z, Veto F, Balas A, Kover F, Doczi T. Biportal endoscopic removal of a primary intraventricular hematoma: case report.. *Minim Invasive Neurosurg* 2000; 43(1):4-8
8. Karnik R, Valentin A, Ammerer HP, Hochfelner A, Donath P, Slany J. Outcome in patients with intracerebral hemorrhage: predictors of survival (Abstract) *Wien Klin Wochenschr* 2000; 112(4):169-73
9. Darby DG, Donnan GA, Saling MA, et al: Primary intraventricular hemorrhage: clinical and neuropsychological findings in a prospective stroke series. *Neurology* 1988; 38:68-75
10. Gates PC, Barnett HJM, Vinters HV; et al: Primary intraventricular hemorrhage in adults. *Stroke* 1986; 17:872-877
11. Little JR, Blomquist GA Jr, Ethier R: Intraventricular hemorrhage in adults. *Surg Neurol* 1977, 8:143-149
12. Mohr G, Ferguson G, Khan M, et al: Intraventricular hemorrhage from ruptured aneurysm. Retrospective analysis of 91 cases. *J Neurosurg* 1983; 58:482-487
13. Verma A, Maheshwari M, Bhargava S: Spontaneous intraventricular hemorrhage. *J Neurol* 1987; 234: 233-236
14. Marti-Fabregas J, Piles S, Guardia E, Marti-Vilalta JL. Spontaneous primary intraventricular hemorrhage: clinical data, etiology and outcome. *J Neurol* 1999; 246(4):287-91
15. Todo T, Usui M, Takakura K, et al: Treatment of severe intraventricular hemorrhage by intraventricular infusion of urokinase. *J Neurosurg* 1991; 74(1):81-6
16. Goh KY, Poon WS. Recombinant tissue plasminogen activator for the treatment of spontaneous adult intraventricular hemorrhage. *Surg Neurol.* 1998 Dec;50(6):526-31
17. Findlay JM, Grace MG, Weir BK. Treatment of intraventricular hemorrhage with tissue plasminogen activator. *Neurosurgery* 1993; 32(6):941-7
18. Nieuwkamp DJ, Gans K, Rinkel GJ, et al. Treatment and outcome of severe intraventricular extension in patients with subarachnoid or intracerebral hemorrhage: a systematic review of the literature. *J Neurol.* 2000; 247(2):117-21
19. Shimoda M, Oda S, Shibata M, et al. Results of early surgical evacuation of packed intraventricular hemorrhage from aneurysm rupture in patients with poor-grade subarachnoid hemorrhage. *Neurosurg* 1999; 91(3):408-14
20. Auer LM, Auer T, Samaya A: Indications for surgical treatment of cerebellar haemorrhage and infarction. *Acta Neurochir (Wien)* 1986; 79:74-79
21. Chin D, Charney P: Acute cerebellar hemorrhage with brain stem compression, in contrast with benign cerebellar hemorrhage. *Surg Neurol* 1983; 19:406-409
22. Donauer E, Loew F, Faubert C, et al: Prognostic factors in the treatment of cerebellar hemorrhage. *Acta Neurochir (Wien)* 1994; 131:59-66
23. Heros RC. Cerebellar hemorrhage and infarction. *Stroke* 1982; 13:106-109
24. Kobayashi S, Sato A, Kageyama Y, et al. Treatment of hypertensive cerebellar hemorrhage: surgical or conservative management? *Neurosurgery* 1994; 34:246-251
25. Taneda M, Hayakawa T, Mogami H: Primary cerebellar hemorrhage: Quadrigeminal cistern obliteration on CT scans as a predictor of outcome. *J Neurosurg* 1987; 67:545-552
26. Acute cerebellar hemorrhage and CT evidence of tight posterior fossa. *Neurology* 1986; 36:858-860

**Author Information**

**Ercan Özer, M.D.**

Assist.Prof., Department of Neurosurgery, Medical Faculty, Dokuz Eylül University

**Kemal Yücesoy, M.D.**

Assoc.Prof., Department of Neurosurgery, Medical Faculty, Dokuz Eylül University

**Mehmet Senoglu, M.D.**

Assist. Prof, Department of Neurosurgery, Medical Faculty, Kahramanmaraş Sütçü Imam University

**Güven Citak, M.D.**

Resident, Şifa Medical Center

**Cem Yurtsever, M.D.**

Resident, Department of Neurosurgery, Medical Faculty, Dokuz Eylül University