

Ectopic intrathyroidal thymus-Rare finding in an adult

K Mardi, J Sharma

Citation

K Mardi, J Sharma. *Ectopic intrathyroidal thymus-Rare finding in an adult*. The Internet Journal of Head and Neck Surgery. 2008 Volume 3 Number 1.

Abstract

Infrequent occurrence of ectopic intrathyroidal thymic tissue caused by maldescent during early embryologic development is reported. It was incidentally detected during the gross examination of right thyroidectomy specimen of a 27 year old female.

INTRODUCTION

Remnants, implants or accessory nodules comprising of thymic tissue may appear from angle of mandible to thyroid gland. Such ectopic thymic tissue is usually an incidental finding during thyroid surgery in preteens. However such a finding in adults is very rare due to thymic involution in adults. We present one such rare instance in a 27 year old female.

CASE REPORT

A 27-year-old female presented to the hospital with a recent history of a slowly enlarging, painless mass in the anterior part of the neck. Thyroid function test results were within normal limits, and aside from cosmetic disfigurement, the patient was asymptomatic. A fine needle aspiration of the right thyroid revealed a colloid nodule. A right thyroidectomy was subsequently performed.

On gross examination, the right thyroid gland weighed 15.0 g and measured $5.5 \times 3.0 \times 2.5$ cm. The cut surface revealed a well-circumscribed, red-brown, cystic nodule that measured 1.7 cm in maximum dimension. A small red-purple ovoid nodule was identified attached to the inferior aspect of the thyroid gland, measuring $0.8 \times 0.4 \times 0.1$ cm. This nodule appeared grossly consistent with a normal inferior parathyroid gland.

Microscopically, the cystic mass of the thyroid showed follicles of variable size and shape with distinct lymphocytic aggregates representative of an adenomatous nodule arising within a lymphocytic thyroiditis. Interestingly, sections from the presumed parathyroid gland turned out to also contain ectopic thymic tissue with distinct cortex, medulla, and Hassall corpuscles. The Hassall's corpuscles were showing degenerative change in the center.

Figure 1

Figure 1: Ectopic thymic tissue with degenerated Hassall corpuscle(H&E,x20)

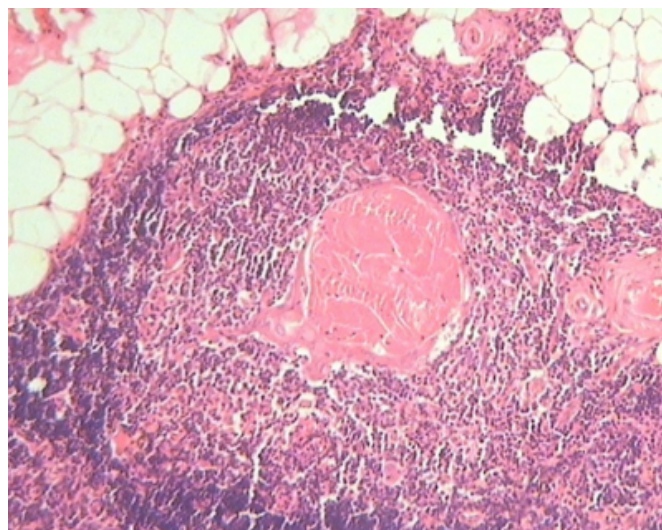
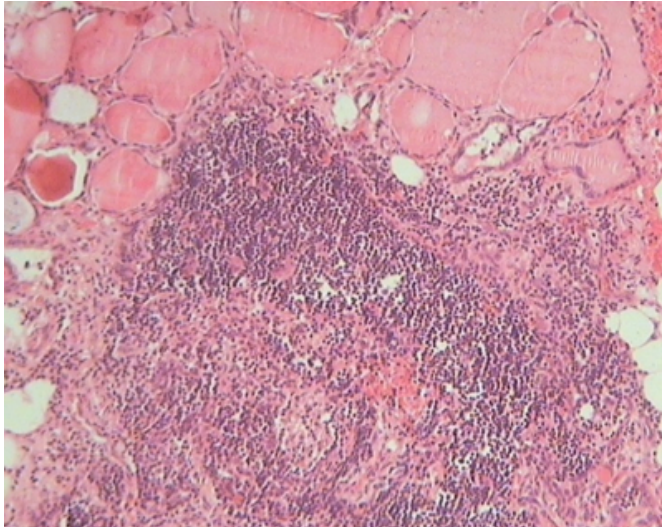


Figure 2

Figure 2:Ectopic thymic tissue along with thyroid tissue



DISCUSSION

The embryologic development of the thymus originates high in the neck in early fetal life and reaches its final destination in the mediastinum only after a process of progressive descent. The thymus commonly shares its origins with the inferior parathyroid glands, both endodermic derivatives of the third pair of branchial pouches. The thymus develops primarily from the ventral wing of the third pharyngeal pouch, whereas the inferior parathyroid glands develop from the dorsal wings of the same pouch. In rare occasions, the thymus fails in its descent and appears as remnants, implants, or accessory nodules anywhere along the cervical pathway from the angle of the mandible to the thyroid gland. The level of the thyroid gland is the most common site for ectopic thymic tissue, but other rare sites include the base of the skull, middle ear, tonsil, submandibular gland, posterior aortic arch, and skin surrounding a bilateral cleft lip.² The presence of ectopic thymic tissue at these sites was explained by the loss and sequestration of a part of the developing thymus, leading to its migration with local tissues.³ Although our case represents ectopic thymic tissue adjacent to normally located thyroid and parathyroid gland, it is interesting to note that the converse may also take place. Maldescent during early embryologic development may also

leave aberrant thyroid and parathyroid tissues within a normally placed mediastinal thymus.

Ectopic thymus from congenital maldescent generally remains dormant and is often found incidentally during thyroid surgery, as in our case. Most reported cases of ectopic thymus occur in the prepubertal pediatric population,^{4,5} correlating with a period of maximum growth of the thymus. Adult cases of ectopic thymus are exceedingly rare,¹ most likely due to age-related involution and replacement by fibroadipose tissue. The incidence of clinically apparent ectopic thymic tissue is rare.³ This is because only a few of these enlarge to become visible or cause symptoms. Ectopic thymic tissue, like its normal counterpart, may also undergo transformation to thymic hyperplasia or even thymic neoplasms. Rare cases of thymomas, thymic carcinomas, and lymphomas have been reported. To obviate this risk of possible malignant transformation and to confirm the diagnosis, excision of these lesions is mandatory.

CORRESPONDENCE TO

Dr Kavita Mardi ,MD,DNB
Assistant Professor
12-A, Type V Quarters
GAD Colony
Kasumpti,
Shimla, H.P
E. mail: kavitamardi yahoo.co.in

References

1. Wu SL, GuptaD, Connelly J. Adult Ectopic Thymus Adjacent to Thyroid and Parathyroid. Archives of Pathology and Laboratory Medicine 2001; 125: 842–3.
2. Bale PM, Sotelo-Avila C. Maldescent of the thymus: 34 necropsy and 10 surgical cases, including 7 thymuses medial to the mandible. Pediatr Pathol 1993;13:181–90.
3. Al-Salem AH. Ectopic thymic tissue stimulating a posterior mediastinal mass. Eur J Pediatr Surg 1992;2:106-7.
4. Shashiraj, Aggarwal A. Undescended thymus presenting as midline neck swelling. Ind J Paediatrics 2005;72:86.
5. Liu D , Kitajima M, Awai K et al. Ectopic cervical thymus in an infant. Radiation Medicine 2006;24:452-55.
6. Tovi F, Mares AJ. The aberrant cervical thymus: embryology, pathology, and clinical implications. Am J Surg 1978;136:631–37.

Author Information

Kavita Mardi, M.D,DNB

Assistant Professor, Dept of pathology, Indira Gandhi Medical College

Jaishree Sharma, M.D

Professor and Head of Department, Dept of pathology, Indira Gandhi Medical College