

A Rare Case Of Tuberculous Retropharyngeal Abscess.

C Amine, B Amine, H Amal, O Abdelatif, E Nouredine

Citation

C Amine, B Amine, H Amal, O Abdelatif, E Nouredine. *A Rare Case Of Tuberculous Retropharyngeal Abscess..* The Internet Journal of Head and Neck Surgery. 2009 Volume 4 Number 2.

Abstract

Tuberculous retropharyngeal abscess is very rare. We describe a case of tubercular retropharyngeal space abscesses treated by incision and drainage. Pus from retropharyngeal abscess examined by BACTEC culture and PCR proved that the abscess was of tuberculous origin.

INTRODUCTION

Retropharyngeal abscess occurs mainly due to pyogenic infection (1), and tuberculous retropharyngeal abscess is very rare (2). In the case of tuberculous retropharyngeal abscess, it is usually due to spinal tuberculosis and is seen mostly in children.

CASE REPORT

A 38 years old male, non-hypertensive, non-diabetic was admitted to the department of otorhinolaryngology with complaints of dysphagia for solid food for about 1 week and difficulty with breathing for 3 days. He had experienced a low-grade irregular fever for about 5 months. The patient had no history of neck pain, ingestion of foreign bodies, earache, dental extraction, endoscopy or other invasive procedure, haematemesis or melaena. On physical examination, a bulge was seen on the posterior pharyngeal wall cystic in consistency and non-tender. There was no bony tenderness in the cervical spine, no lymphadenopathy and no splenomegaly.

Computed tomographic scanning of the neck showed, a huge retropharyngeal space abscess (Fig 1, 2). Blood investigations and Chest X-ray were non specific.

Emergency tracheostomy was done under local anaesthesia with introduction of cuffed T tube followed by incision and drainage of pus from posterior oro-pharyngeal wall. Histopathology examination revealed tuberculosis (Fig.3). Further investigation for HIV infection was negative.

The patient was treated with 4 anti- tuberculosis drugs, isoniazid (400 mg), rifampicin (450 mg), pyrazinamide (1500 mg), and ethambutol (1200 mg) for 2

months, and then continued with 2 drugs (Rifampicin & INH) for 4 months . The patient improved considerably. The patient was free of symptoms at 2 years follow up.

Figure 1

Fig 1: Computed tomographic scan (coronal cut) showing the collected pharyngeal abscess.

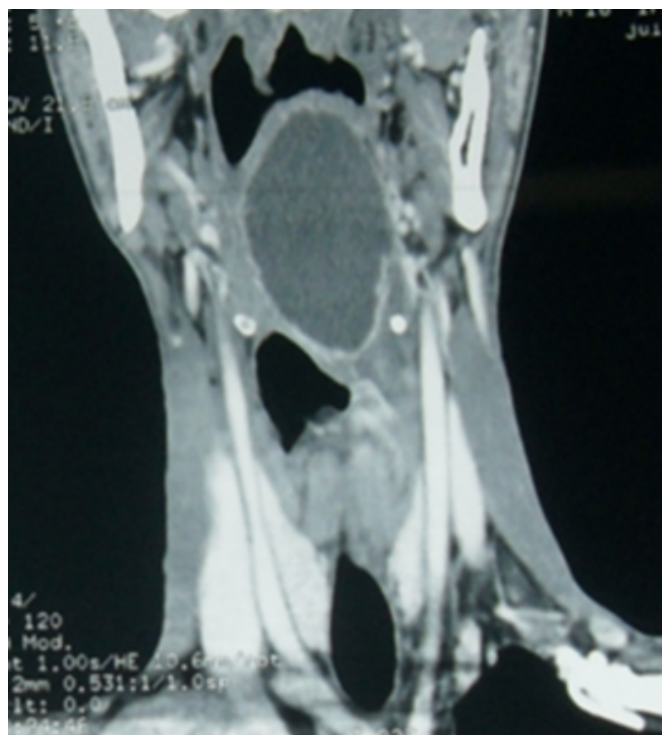

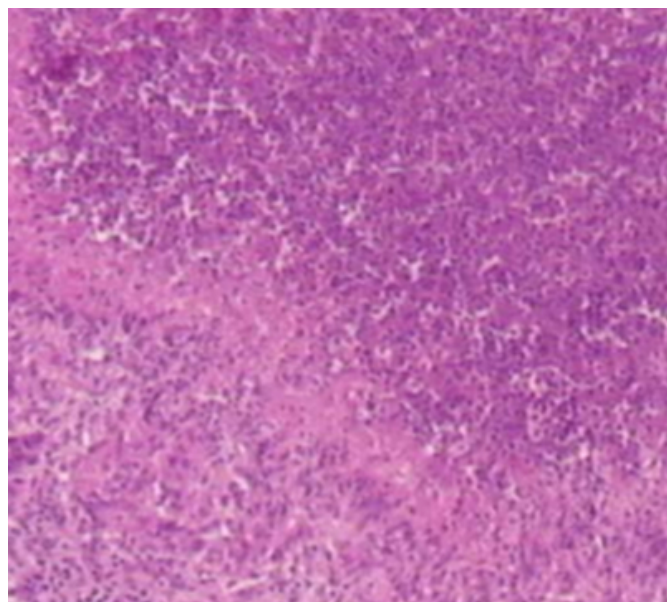
Figure 2

Fig 2: Computed tomographic scan (sagittal cut) showing the collected pharyngeal abscess.

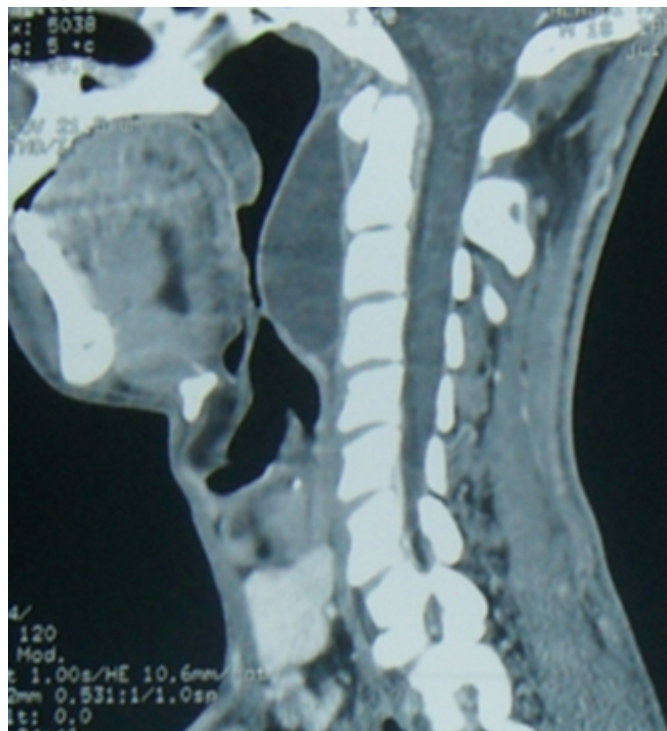

Figure 3

Fig 3: Histological microscopic view of the retropharyngeal tuberculosis.



DISCUSSION

Retropharyngeal abscess are usually seen in children of less than 5 years of age. They are caused by spread of infection from the nasopharynx or the oropharynx, rarely from mastoid infection, as the pus tracks down along the

underside of the petrous bone.

Retropharyngeal abscess in adults is only seen after a penetrating injury or a foreign body piercing the posterior pharyngeal wall.

Retropharyngeal tuberculous abscess is rare presentation of the disease even in the presence of extensive pulmonary tuberculosis (3).

The probable route of tuberculosis spread to the retropharyngeal space is via the lymphatics to a persisting retropharyngeal lymph node which usually disappear after age 4 to 5 years (4, 5).

Clinically, dysphagia, stridor and threatening respiratory obstruction may be the only manifestation (6), cervical lymph node tuberculosis can also be found.

Delay in diagnosis and treatment can lead to complications such as spontaneous rupture of the abscess leading to tracheobronchial aspiration, or stridor due to laryngeal oedema, or mediastinitis.

A retropharyngeal abscess can be drained safely via a transoral route or by an external route following by antitubercular therapy to prevent further complications.

CONCLUSION

Tuberculous retropharyngeal abscess is rare, clinicians should bear this possibility in mind and have to make histopathological exam when the pharyngeal abscess does not respond well to aggressive surgery and antimicrobial treatment.

References

1. Meher R, Jain A, Sabharwal A, Gupta B, Singh I, Agarwal AK. Deep neck abscess: a prospective study of 54 cases. *J Laryngol Otol* 2005; 119:299-302.
2. Benitez P, Guilemany JM, Alobid I, Berenguer J, Mullol J. Transoral approach to drain streptococcus pneumoniae spinal epidural abscess in an HIV-infected adult. *Acta Otolaryngol* 2004;124:863-6.
3. Melchor Diaz MA, Domingo Carrasco C, Monge Jodra R, Marino Espuelas J, Ontanon Martin M. Tuberculous retropharyngeal abscess in an HIV patient. Report of a case. *Acta Otorrinolaringol Esp* 1993;44:467-70.
4. Meher R, Agarwal S, Singh I. Tuberculous retropharyngeal abscess in an HIV patient. *Hong Kong Med J* 2006;12:483-5. Rarely, the abscess may be due to haematogenous spread from pulmonary tuberculosis or tuberculosis elsewhere.
5. Ohar .M C, Chaudhuri. S, Pain. S, Haider.U, Chakraborty.A,Basu. K Retropharyngeal tuberculous abscess along with alcoholic hepatitis and pulmonary tuberculosis *ind j tub.*, 2002,49: 159-60.
6. Kooli H, Marreckchi M, Tiss. M, Kooli M., Hajri H,

Najeh D Z and all. Cold Parapharyngeal Abscess in Spondylodiscitis. Presse Med 2001. 30(1): 19-21.

7. Raj TB. Zarod AP. Acute Non-tuberculous Retropharyngeal Abscess in Adults (Case Reports of three patients). J.laryngo Otol. 1985 ;99(12):1297-300.

Author Information

Cherkaoui Amine

Department Of Oto-Rhino-Laryngology, Hassan II University Hospital

Benlemlih Amine

Department Of Oto-Rhino-Laryngology, Hassan II University Hospital

Hajjij Amal

Department Of Oto-Rhino-Laryngology, Hassan II University Hospital

Oudidi Abdelatif

Department Of Oto-Rhino-Laryngology, Hassan II University Hospital

El alami Nouredine

Department Of Oto-Rhino-Laryngology, Hassan II University Hospital