

# Constrictive Pericarditis Complicating Orthotopic Heart Transplant: Case Report

S Abdel-Samie, P Eberts, M Desouki

## Citation

S Abdel-Samie, P Eberts, M Desouki. *Constrictive Pericarditis Complicating Orthotopic Heart Transplant: Case Report*. The Internet Journal of Pathology. 2010 Volume 11 Number 2.

## Abstract

The major complications in heart transplant recipients are rejection and infection. However, bleeding, pericardial tamponade, cardiac dysrhythmia, circulatory overload, and reduced cardiac output are other complications reported. Here, we report a case of congestive heart failure (CHF) due to constrictive pericarditis on top of orthotopic heart transplantation. This rare complication must be considered in the differential diagnosis of post-transplant CHF in the absence of any other common etiologies. The patient had pericardial effusion in the early post-transplant period and subsequently presented with heart failure unresponsive to standard medical management. Early diagnosis of pericardial constriction after orthotopic heart transplantation requires a high index of clinical suspicion and optimal use of imaging procedures.

## CASE REPORT

A 46-year-old white man who had orthotopic heart transplantation in 1998 for rheumatic heart disease admitted to the hospital for evaluation of progressive weight gain, generalized anasarca and decreased urine output. Echocardiography performed during the last admission demonstrated an end diastolic diameter of 4.5cm, paradoxical ventricular septal motion, a left ventricular ejection fraction at 45%, and dilatation of the right ventricle. The left atrial diameter was found to be abnormal at 6.3cm. No pericardial effusion was identified. The congestive heart failure (CHF) worsened and multiple organ failure ensued. These signs included respiratory failure requiring endotracheal intubation, and renal insufficiency which progressed to acute renal failure requiring hemodialysis. Additional complications included a mycobacterial soft tissue infection of the left foot, central line sepsis, and mesenteric ischemia requiring bowel resection. Following the intestinal surgery, he could not be weaned from the ventilator. An attempt was made to place him back on the transplant list for heart and kidney transplants but he was determined to be ineligible.

Past medical history was significant for aortic and mitral valve repairs in 1980 consequent to rheumatic heart disease, placement of a mechanical prosthetic valve in 1984, pacemaker placement in 1985, and eventually, orthotopic heart transplant in 1998. In 2005, he started suffering from a

two-year-long history of progressive weight gain and edema that led to his eventual hospitalization in 2007. Previous cardiac MRIs demonstrated CHF and a combined constrictive and restrictive pericarditis evidenced by biventricular systolic dysfunction (left ventricular ejection fraction: 36% and right ventricular ejection fraction: 24%) with diffuse biventricular hypokinesis and dyskinetic (paradoxical) ventricular septal wall motion. There was also a "Square root" configuration of the left ventricular filling curve (without atrial kick or evidence of filling during late diastolic filling phase), patchy pericardial thickening, and bilateral atrial and ventricular dilatation (right > left). Endomyocardial biopsies suggested a restrictive cardiomyopathy.

Eventually the family agreed to a "Do Not Resuscitate (DNR)" order, and a palliative care consult was placed. Withdrawal of nonessential care was initiated and removal of all life support took place and limited autopsy examination of the heart only was requested.

On autopsy, external examination revealed the body of well-developed, well-nourished male, who weighed 247 pounds, is 69 inches in length (BMI=36.5), and appears compatible with the stated age of 46 years. The abdomen appeared slightly protuberant, the external genitalia was markedly edematous. There was marked pitting edema of the upper and lower extremities.

Limited autopsy examination of the heart revealed cardiomegaly (heart weighs = 500 grams). The pericardial and epicardial surfaces were roughened and irregular due to the presence of extensive, confluent fibrous adhesions between the inner (parietal serous) pericardial and epicardial surfaces of the heart. The pericardial sac was effectively obliterated with foci of fibrous pericardial thickening and patchy calcifications. Additionally, the external surface of the pericardium (fibrous pericardium) was adherent to the mediastinal pleural surfaces of lungs (Figure 1 A&B).

The coronary arteries arose normally within the right and left sinuses of Valsalva, but the coronary ostia were diminutive (left coronary ostium: 0.1 cm; right coronary ostium: 0.2 cm in maximum dimensions). The major epicardial arteries followed the usual distribution and were widely patent, without significant atherosclerotic plaque, stenosis, or superimposed thrombi; all of the epicardial arteries coursed within the previously described dense, white, firm scar tissue. Both atria and the right ventricle appeared slightly to moderately dilated. Cardiac valves were smooth and pliable and without stenoses, deformities, or vegetations. The valves had the following circumferences: tricuspid valve = 14.0 cm, pulmonic valve = 7.5 cm, mitral valve = 11.0 cm, and aortic valve = 7.5 cm. The myocardium was dark red-brown, firm, and unremarkable with the exception of a focus within the left atrial wall containing transmural plaque-like calcifications and featuring an ulcerated endocardial surface. Specifically, the ventricular myocardium was without foci of softening, discoloration, or fibrosis. The left ventricular free wall thickness = 1.0 cm, right ventricular free wall thickness = 0.4 cm, and the interventricular septal thickness = 1.2 cm. The atrial appendages contained no thrombi. The endocardial surfaces, apart from the previously described plaque-like lesion within the left atrial wall, were thin, delicate, and free of mural thrombi. The aorta and its major branches arose normally, followed the usual course, and were widely patent and free from significant atherosclerotic plaque. The anastomotic suture lines on the endocardial surfaces of the right and left atria and the pulmonary trunk and descending aorta were all intact and without dehiscence. The venae cavae and its major tributaries returned to the heart in the usual distribution and were free of thrombi.

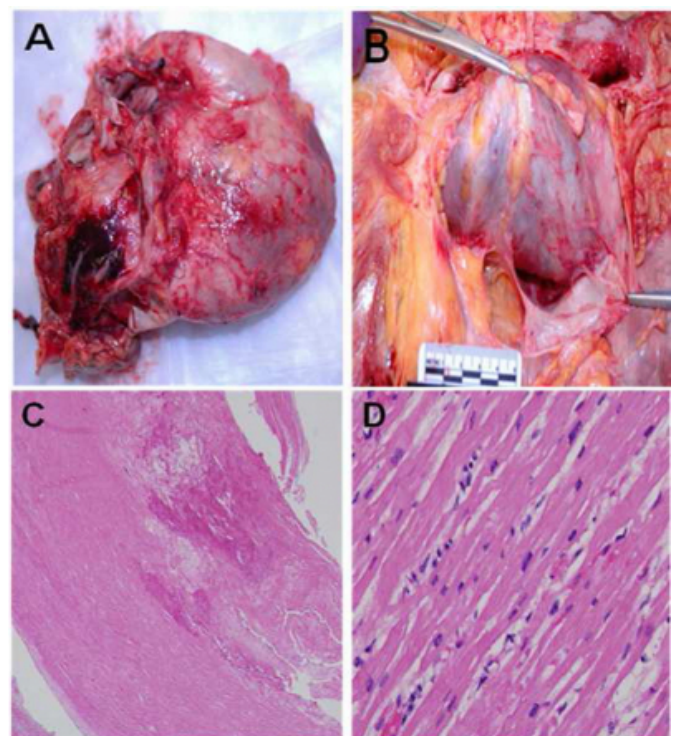
Sections of pericardium, left and right ventricular free walls, and the grossly described left atrial plaque-like thickening were examined microscopically (Figure 1 C&D). Sections of pericardium demonstrated confluent dense fibrosis, along with foci of dystrophic calcification, scattered reactive

mesothelial cells, and numerous birefringent crystals (embedded within the pericardium), several of which are contained within multinucleated foreign body giant cells. The fibrosis extended deeply into the epicardium, where it was accompanied by scattered chronic (mononuclear) inflammatory cells (predominantly lymphocytes), and also into the subjacent myocardium. There was patchy but multifocal replacement fibrosis, consisting of dense collagen that enveloped both individual and groups of myofibers, with relative sparing of the endocardium. There was no significant myofiber disarray or hypertrophy. The grossly described atrial plaque consisted of dense transmural fibrosis with dystrophic calcification.

In light of the gross and microscopic autopsy findings, this patient most probably suffered from complications of CHF due to probable noninfectious combined constrictive and restrictive heart disease (constrictive pericarditis with patchy myocardial replacement fibrosis) complicating orthotopic heart transplant for rheumatic heart disease.

## Figure 1

Figure 1: Gross and histologic evaluation of the heart revealing cardiomegaly and gross pericardial fibrosis and adhesions (A&B). Confluent dense fibrosis, that extends deeply into the epicardium, and multifocal replacement fibrosis consisting of dense collagen that envelops both individual and groups of myofibers, with relative sparing of the endocardium (C). There is no significant myofiber disarray or hypertrophy (D).



## DISCUSSION

This case presented succumbed to a complication of orthotopic heart transplantation outside of the typical spectrum of sequelae that include most commonly the entities of acute and chronic rejection, infection, and cardiac allograft vasculopathy - namely, constrictive pericarditis (CP) combined with some features of restrictive heart disease. In fact, pericardial and mediastinal complications were reported in 12% of 133 heart transplant recipients in a 1994 series from the Department of Surgery at the Montreal Heart Institute in Quebec, Canada (1). This patient's clinical course and autopsy findings closely resemble those described in a case report from Loyola University Medical Center that described a 64-year-old man with a history of rheumatic heart disease who underwent orthotopic heart transplantation following two previous aortic valve repairs with mechanical prostheses, and who presented at 3 months posttransplant with a 10-pound weight gain, increasing abdominal girth, and lower extremity. He underwent both right and left heart catheterizations; the left ventriculogram revealed normal left ventricular function and coronary arteriogram demonstrated widely patent coronary arteries. However, the right heart catheterization displayed elevated right-sided (atrial and ventricular) pressures and venous waveform tracings exhibiting equalization of pressures between right and left ventricles – findings characteristic of CP (2). These observations are remarkably similar to those in the present case.

Other cases of CP after cardiac transplantation have been reported by Copeland et al. (3) and Roca et al. (4). Pericardial complications after heart transplantation, including CP, are uncommon but not unusual (1,5). Therefore, this complication should be recognized in patient with heart transplant.

CP is defined as an inflammatory condition characterized by the encasement of the heart by a rigid non-pliable pericardium due to dense fibrosis and adhesions. This will profoundly restrict diastolic filling of the heart and lead to heart failure. Patients typically present with predominant systemic venous congestion; pulmonary congestion is evident when left-sided filling pressures exceed 15 mm Hg. Elevation of jugular venous pressure and a rapid Y descent are the most common physical findings. Atrial arrhythmias, particularly atrial fibrillation, frequently develop in the late stages of the disease process (6).

Diagnosis depends on the clinical picture, diagnostic

imaging (electro-cardiogram, chest X ray, echocardiography), surgical and pathological criteria. Other diagnostic procedures such as computerized tomography scan, magnetic resonance imaging and myocardial biopsy can also be done (7). Two-dimensional echocardiography will typically show biatrial enlargement, preserved ventricular dimensions, normal systolic function, and often some degree of pericardial thickening. Doppler studies demonstrate significantly increased respiratory variations in flow measured at the atrioventricular valves and hepatic and pulmonary veins, reflecting the lack of normal transmission of intrathoracic pressures to the heart (8).

The clinical and diagnostic distinction between CP and myocardial diseases especially the restrictive cardiomyopathies is very difficult because the hemodynamic behavior of the two processes is similar. However, characteristic changes were seen with respiration that suggests differentiation of these disease states may also be possible by comparing respiratory changes in transvalvular flow velocities (9). Sometimes, pericardial or endomyocardial biopsy will be required to differentiate the two diseases accurately.

CP could be idiopathic or due to infections, radiation therapy or following cardiac surgery. One of the largest study evaluating factors contributing to the development of significant pericardial effusions after orthotopic cardiac transplantation has shown that as many as 70% of patients undergoing cardiac surgery end up developing postoperative pericardial effusions. Most of these effusions are small and asymptomatic and generally resolve within 2 weeks of surgery, but some persist for several months and may even rarely cause tamponade. In a series of 203 patients, significant (moderate and large) pericardial effusions occurred in 21%, an incidence similar to the reports of others (10). Other factors like, acute rejection and the use of cyclosporine may contribute to the development of significant pericardial effusions. However, other studies have found no correlation between cyclosporine treatment and the development of pericardial effusion in patients after their transplantation (10, 11). Antifibrinolytic agents, such as aminocaproic acid, can be used in the perioperative setting to reduce postoperative bleeding. This agent was found to be associated with a dramatically increased incidence of postoperative pericardial effusion and may contribute to retention of clots within the pericardial sac (10, 12). Subsequent clot lysis may encourage fluid inspissation, leading to an effusion. However, it is noteworthy that the

amount of mediastinal chest drainage, duration of chest tube drainage, and the quantities of blood products administered after transplantation were not found to correlate with the development of pericardial effusions (12). So, the underlying basis for CP in the posttransplant setting is most likely the accumulation of blood products within the pericardial sac with subsequent deposition and healing of the pericardial surface. In the course of such healing, scar formation in the form of adhesions occurs and leads to the constrictive physiology.

The treatment of choice for symptomatic CP is mechanical relief of the constriction, which can be problematic because it involves mechanical stripping of the pericardium (pericardiectomy). This procedure carries a significant risk of subjacent myocardial injury; the mortality rate of which (following cardiac surgery) is 11%. However, the majority of operative survivors experience improvement in the hemodynamics and the quality of life (13-15). Without treatment this disease is characterized by high morbidity and mortality and as of now there is no other truly effective intervention for CP.

In conclusion, this patient experienced a very unusual complication of orthotopic heart transplantation; one that must be considered in the differential diagnosis of posttransplant CHF in the absence of rejection, infection, or another clearly defined etiology.

### References

1. Carrier M, Hudon G, Paquet E, et al. Mediastinal and pericardial complications after heart transplantation. Not-so-unusual postoperative problems? *Cardiovasc Surg*. 1994 Jun;2(3):395-7.
2. Ramana RK, Gudmundsson GS, Maszak GJ, Cho L, Lichtenberg R. Noninfectious constrictive pericarditis in a heart transplant recipient. *J Heart Lung Transplant*. 2005 Jan;24(1):95-8.
3. Copeland JG, Riley JE, Fuller J. Pericardiectomy for effusive constrictive pericarditis after heart transplantation. *J Heart Transplant*. 1986 Mar-Apr;5(2):171-2.
4. Roca J, Manito N, Castells E, et al. Constrictive pericarditis after heart transplantation: report of two cases. *J Heart Lung Transplant*. 1995 Sep-Oct;14(5):1006-10.
5. Loire R, Tabib A, Roux N, Dureau G. [Pericardium and heart transplantation]. *Arch Mal Coeur Vaiss*. 1994 Apr;87(4):467-73.
6. Myers RB, Spodick DH. Constrictive pericarditis: clinical and pathophysiologic characteristics. *Am Heart J*. 1999 Aug;138(2 Pt 1):219-32.
7. Wang ZJ, Reddy GP, Gotway MB, Yeh BM, Hetts SW, Higgins CB. CT and MR imaging of pericardial disease. *Radiographics*. 2003 Oct;23 Spec No:S167-80.
8. Oh JK, Hatle LK, Seward JB, et al. Diagnostic role of Doppler echocardiography in constrictive pericarditis. *J Am Coll Cardiol*. 1994 Jan;23(1):154-62.
9. Palka P, Lange A, Donnelly JE, Nihoyannopoulos P. Differentiation between restrictive cardiomyopathy and constrictive pericarditis by early diastolic doppler myocardial velocity gradient at the posterior wall. *Circulation*. 2000 Aug 8;102(6):655-62.
10. Vandenberg BF, Mohanty PK, Craddock KJ, et al. Clinical significance of pericardial effusion after heart transplantation. *J Heart Transplant*. 1988 Mar-Apr;7(2):128-34.
11. Hastillo A, Thompson JA, Lower RR, Szentpetery S, Hess ML. Cyclosporine-induced pericardial effusion after cardiac transplantation. *Am J Cardiol*. 1987 May 1;59(12):1220-2.
12. Quin JA, Tauriainen MP, Huber LM, et al. Predictors of pericardial effusion after orthotopic heart transplantation. *J Thorac Cardiovasc Surg*. 2002 Nov;124(5):979-83.
13. Nataf P, Cacoub P, Dorent R, et al. Results of subtotal pericardiectomy for constrictive pericarditis. *Eur J Cardiothorac Surg*. 1993;7(5):252-5; discussion 5-6.
14. McCaughan BC, Schaff HV, Piehler JM, et al. Early and late results of pericardiectomy for constrictive pericarditis. *J Thorac Cardiovasc Surg*. 1985 Mar;89(3):340-50.
15. Seifert FC, Miller DC, Oesterle SN, Oyer PE, Stinson EB, Shumway NE. Surgical treatment of constrictive pericarditis: analysis of outcome and diagnostic error. *Circulation*. 1985 Sep;72(3 Pt 2):II264-73.

**Author Information**

**Souzan A. Abdel-Samie**

Departments of Biochemistry & Molecular Biology, Division of Basic Sciences and Pathology & Laboratory Medicine,  
Medical University of South Carolina

**Paul Eberts**

Departments of Biochemistry & Molecular Biology, Division of Basic Sciences and Pathology & Laboratory Medicine,  
Medical University of South Carolina

**Mohamed Mokhtar Desouki, MD, PhD**

Departments of Biochemistry & Molecular Biology, Division of Basic Sciences and Pathology & Laboratory Medicine,  
Medical University of South Carolina