

Endometrial Intraepithelial Neoplasia And Its Correlation With WHO Classified Endometrial Hyperplasia

R Khanna, G Rupala, V Khanna

Citation

R Khanna, G Rupala, V Khanna. *Endometrial Intraepithelial Neoplasia And Its Correlation With WHO Classified Endometrial Hyperplasia*. The Internet Journal of Pathology. 2010 Volume 12 Number 1.

Abstract

Introduction: Endometrial hyperplasia produces a continuum of lesions that may be precursor to endometrial carcinoma of endometrioid histology. The World Health Organization (WHO) classification is currently the most commonly accepted system of classifying endometrial hyperplasias, the problems with which have prompted the development of an alternative system based on Endometrial Intraepithelial Neoplasia (EIN). **Materials and Methods:** We undertook the study using revised EIN criteria to differentiate EIN lesions from lookalikes. EIN diagnostic criteria's, such as gland area>stromal area, cytologic change in focus of altered architecture, lesion size>1 mm and exclusion of cancer and mimics were applied on two hundred endometrial biopsies that were initially classified as hyperplasia using WHO classification system. **Results:** Out of total two hundred cases, 41.5% were diagnosed as simple typical hyperplasia, 19% cases as complex typical hyperplasia, 9.5% cases as simple atypical hyperplasia and 30% cases as complex atypical hyperplasia respectively. Out of these WHO classified hyperplasias, 39% were re-classified as EIN and 61% as non-EIN lesions. Majority of WHO classified atypical hyperplasias were reclassified as EIN. **Conclusion:** EIN criterias can easily be applied to routine haematoxylin and eosin stained sections and is more reproducible than WHO system of classification. Few of the lesions diagnosed as simple hyperplasia without atypia correspond to EIN and have a worse prognosis. EIN successfully segregates patients into high and low cancer risk groups.

INTRODUCTION

Due to inadequately supported reproductive pathologic criteria's in existing World Health Organization (WHO) classification of endometrial hyperplasia, the diagnosis of precancerous lesions of the endometrium remains unstandardized¹. There are many shortcomings in the WHO endometrial hyperplasia classification system that subclassifies hyperplasia by cytology as atypical / non atypical and architecture as complex / non complex.^{2,3} Overall reproducibility of atypical hyperplasia diagnosis is poor, because of nonspecific reporting patterns and intra/inter-observer variation which leads to confusion among clinicians and pathologists. The Endometrial Collaborative Group, an international group of 19 pathologists has recently attempted to clarify the concept of endometrial neoplasia and proposed two categories of endometrial lesions, endometrial hyperplasia and endometrial neoplasia, the latter divided into intra-epithelial and invasive neoplasia. True endometrial hyperplasia rarely progresses to neoplasia while lesions formerly designated as "atypical hyperplasia" are presently reclassified as Endometrial Intraepithelial Neoplasia (EIN), which carries a

significant risk of progression into invasive carcinoma^{4,5}.

According to Endometrial Collaborative Group, there are many advantages to diagnose premalignant endometrial disease as EIN such as 1) Pre-cancers should be placed in a single diagnostic category 2) Pre-cancers are monoclonal and thus neoplastic and parallelism with other pre-cancerous nomenclature systems elsewhere in the female genital tract is required 3) Endometria which do not meet diagnostic criteria for EIN can be diagnosed as "Endometrial Hyperplasia" to distinguish them from EIN lesions. Long term prospective multicenter studies have shown that the EIN system is prognostically superior then other commonly used systems⁹. Based on these considerations, the present study was designed to review Endometrial Intraepithelial Neoplasia (EIN) and to correlate it with WHO classification of endometrial hyperplasia.

MATERIALS AND METHODS

Two hundred patients who were not on therapeutic hormones and who presented with abnormal vaginal bleeding were included in this study. The histopathological

material consisted of dilatation and curettage, endometrial biopsy and hysterectomy specimen. The material was fixed in 10% formalin and processed in graded alcohol and xylene, embedded in paraffin wax and thin sections were taken on pre-labelled slides. The hydrated sections were then subjected to haematoxylin and eosin staining. Two pathologists separately examined the slides using the WHO hyperplasia classification system which was considered as primary diagnosis and then reclassified these lesions as Endometrial Intraepithelial Neoplasia using EIN criterias⁶ such as 1) Glandular crowding (volume percentage stroma < 55%): EIN lesions have a stromal volume less than that of the glands 2) Cytologic demarcation: EIN lesions have an abnormal cytology within the crowded glands comprising an EIN focus. 3) Size of the lesion should exceed 1mm. 4) exclude confounding benign processes like secretory endometrium, polyps, repair etc. 5) exclude carcinoma. The percentages of each WHO hyperplasia category that was re-classified as EIN were then determined and classified as EIN lesion or Non-EIN lesion.

RESULTS

In the present study, two hundred cases of various endometrial hyperplastic lesions were examined, out of which majority of patients with WHO classified endometrial hyperplasias were from 4th and 5th decade of life whereas Endometrial Intraepithelial Neoplasia lesions were more prevalent in 5th decade of life. As shown in table 1; out of total two hundred cases, 41.5% were diagnosed as simple typical hyperplasia, 19% cases as complex typical hyperplasia, 9.5% cases as simple atypical hyperplasia and 30% cases as complex atypical hyperplasia respectively.

Figure 1

Table 1: Showing distribution of cases in hyperplastic group according to WHO classification

Histologic diagnosis	Cytologic atypia	Architectural pattern	No of cases n (%)
Simple typical hyperplasia	Absent	Regular	83 (41.5%)
Complex typical hyperplasia	Absent	Irregular glands crowded back to back	38 (19%)
Simple atypical hyperplasia	Present	Regular	19 (9.5%)
Complex atypical hyperplasia	Present	Irregular glands crowded back to back	60 (30%)

By applying various EIN criteria's to WHO classified hyperplastic lesions, it was found that majority of simple and complex hyperplastic atypical lesions were reclassified as EIN (72%), whereas 47% of complex hyperplastic lesions without atypia and 3% of simple atypical hyperplastic lesions were rediagnosed as EIN as shown in Table 2.

Figure 2

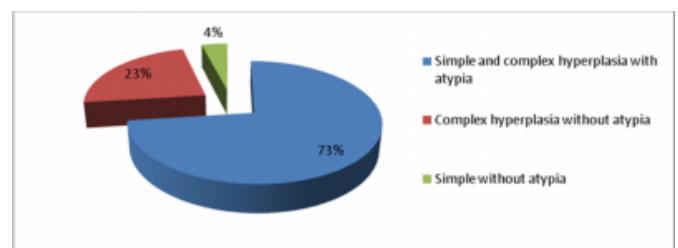
Table 2: WHO Endometrial hyperplasia re-classification using EIN criteria

WHO hyperplasia diagnosis	EIN diagnosis n (%)	Total
Simple and complex hyperplasia with atypia	57 (72%)	79
Complex hyperplasia without atypia	18 (47%)	38
Simple hyperplasia without atypia	3(3%)	83
Total	78(39%)	200

As shown in figure 1, Out of total seventy eight re-classified Endometrial Intraepithelial Neoplasia lesions, 73% were contributed by simple and complex atypical hyperplastic lesions and 4% by simple hyperplastic lesions without atypia.

Figure 3

Figure 1: Percentage contribution of EIN lesions among total EIN lesions in different Endometrial Hyperplasias



DISCUSSION

In this study, majority of cases of endometrial hyperplasias and EIN lesions were seen in 5th decade of life which was similar to the study done by Mutter et al⁷ and Kurman et al⁸. The number of cases of simple typical hyperplasias in the present study was found to be similar with the study done by Kurman et al⁸, Baak et al⁹, Baak et al¹⁰ and Hecht et al¹¹. Seventy eight cases (39%) of EIN lesions were re-diagnosed from two hundred cases of WHO classified endometrial hyperplasia which was relatively similar to study done by Hecht et al¹¹. Table 3 shows comparison of WHO classified simple typical hyperplasia, complex typical hyperplasia and atypical hyperplasias with EIN as studied by different authors.

Figure 4

Table 3: Various studies comparing WHO classified hyperplasia with EIN

Authors name	Simple typical hyperplasia	EIN n(%)	Complex typical hyperplasia	EIN n(%)	Atypical hyperplasia	EIN n(%)
Baak et al ⁹	65	9(13%)	6	2(34%)	61	35(58%)
Hecht et al ¹¹	56	2(3.5%)	18	8(45%)	23	18(78%)
Baak et al ¹⁰	289	37(12.8%)	67	29(43%)	123	58(47%)
Present study	83	3(3.5%)	38	18(47%)	79	57(72%)

In the present study, two pathologists subjectively, reclassified EIN lesions from WHO classified hyperplasia by examining H&E stained sections of endometrial lesions. Due to resource constraints, there are many limitations in the present study. We did not employ molecular analysis of premalignant lesions and computerized morphometry techniques, which enables more objective histologic changes in premalignant lesions, which are essential in accurate diagnosis of EIN. Nevertheless, our study has demonstrated that diagnosis of EIN can be made “subjectively” by histopathological examination, by strictly adhering to EIN diagnostic criteria’s. Subjective diagnosis of EIN lesions is of great value in resource constrained countries, however this may limit the accurate diagnosis, hence further studies, expertise and experience are needed to strengthen the present view.

CONCLUSION

Our study concluded that Endometrial Intraepithelial Neoplasia (EIN) lesions are commonly seen in postmenopausal women. Few of the lesions diagnosed as simple hyperplasia without atypia correspond to EIN and have a worse prognosis. EIN criteria can be easily applied to routine haematoxylin and eosin stained histopathological sections which segregates patients into high and low cancer subgroups. Unreliable diagnosis of endometrial hyperplasia leads to unnecessary suffering, surgical complications and high treatment costs. Diagnosis of EIN is essential as clinical management of EIN is totally different from endometrial adenocarcinoma. EIN lesions are managed either by

hormonal or surgical therapy, whereas the treatment of adenocarcinoma is stage dependent. WHO classification of endometrial hyperplasia needs further improvement for diagnostic accuracy, which will then take a new approach towards premalignant endometrial diseases¹².

References

1. Mutter GL: Endometrial intraepithelial neoplasia (EIN). Will it bring order to chaos? The Endometrial Collaborative Group. *Gynecol Oncol* ;2000 Mar;76(3):287-90.
2. Kurman R, Norris H: Endometrial hyperplasia and metaplasia in Blaustein’s Pathology of the Female Genital Tract. Springer-Verlag; 322-337,1987.
3. Scully RE, Bonfiglio TA, Kurman RJ, Silverberg SG, Wilkinson EJ: Uterine corpus Histological typing of Female Genital Tract Tumors. New York, Springer-Verlag;13-31,1994.
4. Kenneth M, Feeley Michael Wells: Advances in Endometrial Pathology. Recent advances in Histopathology - No.19; P 20-21.
5. Mutter GL: EIN Central [On Line]; <http://www.endometrium.org>, 2001.
6. Mutter GL: Diagnosis of premalignant endometrial disease. *J Clin Pathol*; 2002 May; 55(5):326-31.
7. Mutter GL, Ince TA, Baak JP, Kust GA, Zhou XP, Eng C: Molecular identification of latent precancers in histologically normal endometrium. *Cancer Res*; 2001 Jun 1;61(11):4311-4.
8. Kurman RJ, Kaminski PF, Norris HJ: The behavior of endometrial hyperplasia. A long-term study of "untreated" hyperplasia in 170 patients. *Cancer*; 1985 Jul 15;56(2):403-12.
9. Baak JP, Orbo A, van Diest PJ, Jiwa M, de Bruin P, Broeckaert M, Snijders W, Boodt PJ, Fons G, Burger C, Verheijen RH, Houben PW, The HS, Kenemans P: Prospective multicenter evaluation of the morphometric D-score for prediction of the outcome of endometrial hyperplasias. *Am J Surg Pathol*; 2001 Jul;25(7):930-5.
10. Baak JP, Mutter GL, Robboy S, van Diest PJ, Uytendille AM, Orbo A, Palazzo J, Fiane B, Løvslett K, Burger C, Voorhorst F, Verheijen RH: The molecular genetics and morphometry-based endometrial intraepithelial neoplasia classification system predicts disease progression in endometrial hyperplasia more accurately than the 1994 World Health Organization classification system. *Cancer*; 2005 Jun 1;103(11):2304-12.
11. Hecht JL, Ince TA, Baak JP, Baker HE, Ogden MW, Mutter GL: Prediction of endometrial carcinoma by subjective endometrial intraepithelial neoplasia diagnosis. *Mod Pathol*; 2005 Mar;18(3):324-3
12. Tavassoli FA, tratten MR: WHO Classification of tumors Pathology and genetics tumors of the breast and female genital organs. Geneva: WHO Press; 2003.

Author Information

Ruchee Khanna, MD

Department of Pathology, Manipal University

GM Rupala, MD

Department of Pathology, U.P. Rural Institute of Medical Sciences & Research

Vinay Khanna, MD

Manipal University