

Unusual case of acne fulminans: face predominant without chest and trunk lesion

K Yamanaka, D Tsuruta, I Kurokawa, M Ishii, H Kobayashi

Citation

K Yamanaka, D Tsuruta, I Kurokawa, M Ishii, H Kobayashi. *Unusual case of acne fulminans: face predominant without chest and trunk lesion*. The Internet Journal of Dermatology. 2008 Volume 7 Number 1.

Abstract

Acne fulminans is a rare severest acne mainly affected with teenage boys with sudden onset of fulminant necrotizing acne presenting simultaneously with synovitis-acne-pustulosis-hyperostosis-osteitis (SAPHO) syndrome-like bone lesions and systemic symptoms. Histopathologically, massive inflammatory process around the sebaceous glands is observed. We present a case of face predominant acne fulminans without back and chest lesion. Thus far, there have been no definite reports of acne fulminans without back and chest lesion. Differential diagnosis between rosacea fulminans and acne fulminans were discussed.

INTRODUCTION

Acne fulminans is a rare severest acne mainly affected with teenage boys with sudden onset of fulminant necrotizing acne presenting simultaneously with synovitis-acne-pustulosis-hyperostosis-osteitis (SAPHO) syndrome-like bone lesions and systemic symptoms; fever, leukocytosis, anemia and myalgia [1]. Lesions undergo rapid suppuration, leaving ragged hemorrhagic ulcers [1]. It mainly affects on the trunk (back and chest), and sometimes on the face [1,2]. After 2 to 3 months, complete remission is obtained with scarring without any treatments. Histopathologically, massive inflammatory process around the sebaceous glands is observed [3]. We present a case of face predominant acne fulminans without back and chest lesion.

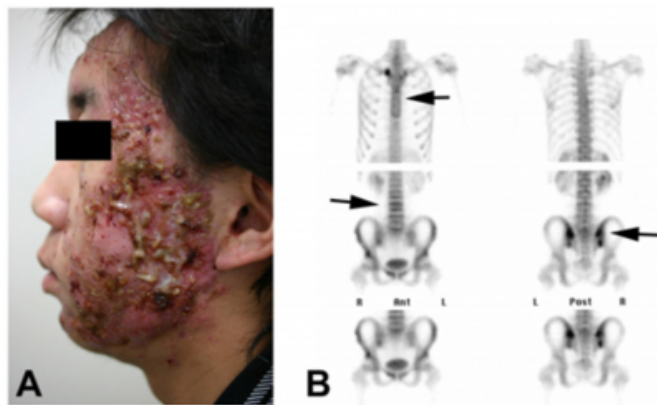
CASE REPORT

A 19-year-old man was referred to our hospital because of acneiform eruptions with severe pustular discharge on the face and fierce pain on the back. He reported that the eruption had suddenly appeared and spread in two weeks, and noticed accompanying low-grade fever. He had been treated with antibiotics and a nonsteroidal anti-inflammatory drugs (NSAID, 25 mg of diclofenac sodium) at a nearby hospital, but the acneiform eruption enlarged in area, the purulent discharge rapidly increased, and the back pain became fierce. The lesions were severely painful acne with purulent secretion on the entire cheek, forehead, and jaw (Figure 1A) without any eruptions on the back and chest, accompanied by fierce back pain. Laboratory testing showed leukocytosis (13,100/ l) and an elevation of C-reactive

protein (5.4 mg/dl). Histopathology from the affected cheek showed infiltration of many lymphocytes and epithelioid cells with fistula in the dermis, suggesting the diagnosis of chronic granulomatous inflammation. There was no positive growth of any microbes in the culture of the purulent secretion. Human leucocyte antigen (HLA) testing demonstrated HLA-A2, -A24, -B51, and -B61, but HLA-B27 was negative. Moreover, the concentration of testosterone, leutenisng hormone, androstendione, dehydroepiandrosterone and 17-alpha-hydroxyprogesterone (reported to be elevated after ACTH stimulation in severe acne variants)[4] was in nomal limits. Bone scintigraphy revealed uptake in the sternoclavicular joints, sacroiliac joints, and a vertebra (Figure 1B). From the above findings, we diagnosed this patient as having acne fulminans and treated with 30mg of oral prednisolone and 50 mg of diclofenac sodium daily with incision for drainage of the subcutaneous abscess. All of his symptoms perfectly disappeared in 3 months without any treatments, although mild scar remains permanently on his cheek.

Figure 1

Figure 1: (A) Acneiform eruptions with purulent secretion on the entire cheek, forehead, and jaw. (B) Bone scintigraphy revealed uptake in the sternoclavicular joints, sacroiliac joints, and a vertebra.



Differential diagnosis of this patient must be made between rosacea fulminans and acne fulminans. Rosacea fulminans is characterized by the sudden onset of severe nodular acne with draining sinuses confined to the face of young female without systemic symptoms or polyarthralgia [3]. The symptoms usually prolong in months or years, but it completely diminishes without scar formation [5]. Our patient did not fulfill above mentioned symptoms, because the patient 1) is male, 2) has systemic symptoms; 3) recovered in 3 months without any treatments, 4) has scarring, 5) have polyarthralgia. We, therefore, diagnosed our patient as acne fulminans rather than rosacea fulminans, although there are one discrepancy; face predominant distribution of acne. Thus far, there have been no reports of acne fulminans without chest and back lesion with face lesion.

The etiology of acne fulminans is uncertain. However, abnormal immunologic reaction to sebum or bacterial antigens, such as *Propionibacterium acnes*, drug-induced, heredity factor, abnormal circulating or exogenous androgens have been speculated [1,3,4,6]. But in our case, there are no positive infectious agents, no history of families, no drug usage before the onset of the disease, and no hormone abnormalities. Therefore, we can not determine the cause of this disease in our patient. The accumulation of similar cases warrants the clue of the pathogenesis of this rare disease.

CORRESPONDENCE TO

Daisuke Tsuruta, MD Department of Dermatology Osaka City University Graduate School of Medicine 1-4-3 Asahimachi, Abeno-ku, Osaka 545-8585 Japan
dtsuruta@med.osaka-cu.ac.jp

References

1. Mehrany K, Kist JM, Weenig RH, Witman PM. Acne fulminans. *Int J Dermatol* 2005; 44: 132-133.
2. Choi EH, Bang D. Acne fulminans and 13-cis-retinoic acid. *J Dermatol* 1992; 19: 378-383.
3. Karvonen SL, Rasanen L, Cunliffe WJ, Holland KT, Karvonen J, Reunala T. Delayed hypersensitivity to *Propionibacterium acnes* in patients with severe nodular acne and acne fulminans. *Dermatology* 1994; 189: 344-349.
4. Placzek M, Arnold B, Schmidt H, Gaube S, Keller E, Plewig G, Degitz K. Elevated 17-hydroxyprogesterone serum values in male patients with acne. *J Am Acad Dermatol* 2005; 53: 955-958.
5. Mori R, Matsushima S, Honda T, Horiguchi Y, Imamura S. Chronic superficial pyoderma of the face: an unusual male case of rosacea fulminans. *J Dermatol* 2005; 32: 189-192.
6. Traupe H, von Muhlendahl KE, Bramswig J, Happle R. Acne of the fulminans type following testosterone therapy in three excessively tall boys. *Arch Dermatol* 1988; 124: 414-417.

Author Information

Kazuhoshi Yamanaka, MD

Department of Dermatology, Osaka City University Graduate School of Medicine

Daisuke Tsuruta, MD

Department of Dermatology, Osaka City University Graduate School of Medicine

Ichiro Kurokawa, MD

Department of Dermatology, Mie University Medical School

Masamitsu Ishii, MD

Department of Dermatology, Osaka City University Graduate School of Medicine

Hiromi Kobayashi, MD

Department of Dermatology, Osaka City University Graduate School of Medicine