

External fixation in the management of Intertrochanteric fractures in elderly high risk patients

S Tak, G Dar, K Kangoo, M Halwai

Citation

S Tak, G Dar, K Kangoo, M Halwai. *External fixation in the management of Intertrochanteric fractures in elderly high risk patients*. The Internet Journal of Orthopedic Surgery. 2007 Volume 8 Number 2.

Abstract

42 Intertrochanteric fractures in elderly high risk patients, with a score of II-III as per the classification of physical status according to the system of American Society of Anesthetists, were treated with external fixation, at an average age of 72 years. There were 19 male and 23 female patients. The left hip was affected in 24 patients and right hip in 18 patients. The patients were followed from 6-18 months; average follow up was 9 months. Final assessment was done at 6 months using modified Harris hip score. Average time for union was 14 weeks (11-20 weeks). 29 patients were ambulatory with out any support and 10 patients needed the help of a stick at final assessment. 23 patients had grade 1 pin tract infection, 10 patients had varus angulation more than 5°, external rotation deformity more than 5° was seen in 4 patients and shortening of more than 1 cm was seen in 5 patients. 30 patients had no pain and 9 patients had mild activity related pain at final follow up. We concluded that external fixation is a good alternative which can restore mobility and achieve fracture union in elderly high risk patients with Intertrochanteric fractures.

INTRODUCTION

Intertrochanteric fracture is one of the most common fractures of the hip especially in the elderly with porotic bones, usually due to low-energy trauma like simple falls^{1,2}. The incidence of Intertrochanteric fracture is rising because of increasing number of senior citizens with osteoporosis^{2,5}. By 2050 the incidence is estimated to be doubled^{1,2}. In India the figures may be much more². Compared to patients with femoral neck fractures, patients with Intertrochanteric fractures are significantly older, more likely to be limited to home ambulation, and more dependent in their activities of daily living; therefore, they tend to have an overall poorer prognosis.¹ Problems of these fractures are (1) association with substantial morbidity and mortality (2) malunion (3) implant failure, cutout of head, and penetration into hip. (4) great financial burden to the family (5) associated medical problem like diabetes, hypertension².

It is universally agreed that the treatment of Intertrochanteric fractures is stable internal fixation as early as possible. Stable fixation is the keystones of successful union of inter trochanteric fractures². Factors beyond the control of surgeon for successful treatment are: (i) fracture geometry and stability, (ii) bone quality, (iii) comminution. Factors under the control of surgeon are: (i) good reduction, (ii)

proper choice of implant, (iii) proper surgical technique, and (iv) availability of modern operation rooms, entire set of implants, instrumentation and image intensifier.²

Currently accepted methods of fixation for these fractures are a compression hip screw or intramedullary nail. In elderly patients with associated medical co morbidities, these major surgical procedures can not be undertaken unless patient is thoroughly evaluated and the medical problems addressed. In such situations external fixator, which can be applied under local anaesthesia and sedation or under short regional anaesthesia, provides a stable method of fixation so that patients could be ambulated early and complications of recumbence avoided.¹²

PATIENTS & METHOD

From Jan 2005 to Apr 2007, 42 elderly patients with Intertrochanteric fractures were treated with external fixation at Bone and Joint Surgery Hospital. The American society of Anesthetists score was grade II-III (Table 1)²⁰. The age of patients ranged from 65-89 years and average age was 72 years at the time of surgery. There were 19 male and 23 female patients. Left hip was involved in 24 and right hip in 18 patients. Domestic fall was the most common cause of injury (38 patients). Rest of the patients had suffered fracture because of road traffic accidents. There were 30 type A1 and

12 type A2 fractures as per the AO/OTA classification system. 6

Figure 1

Table 1: Classification of Physical status according to the system of American Society of Anesthetists.

<i>Grade</i>	<i>Description</i>	<i>No. of Patients</i>
I	A normal healthy person.	-
II	A patient who has mild systemic disease	9
III	A patient who has severe systemic disease that is not in-capacitating	33
IV	A patient who has severe systemic disease that is a constant threat to life.	-
V	A moribund patient not expected to survive for 24 hours with or without surgery	-
VI	Added to any class for surgery on an emergency basis.	-

OPERATIVE TECHNIQUE

The average interval between injury and surgery was 7 days. Local anaesthesia with sedation was used in 18 patients, in rest of the patients short spinal or epidural anaesthesia was used. Fracture table and image intensifier was used for reduction in all cases. Fracture was fixed with two Schanz screws passed from lateral aspect greater trochanter along the neck engaging the subchondral bone of head. Two more Schanz screws were passed in the proximal femur. All the pins were connected with an external rod. Fig.1

Figure 1: External fixation of intertrochanteric fracture

Figure 2

Figure 1A: Pre operative Radiograph

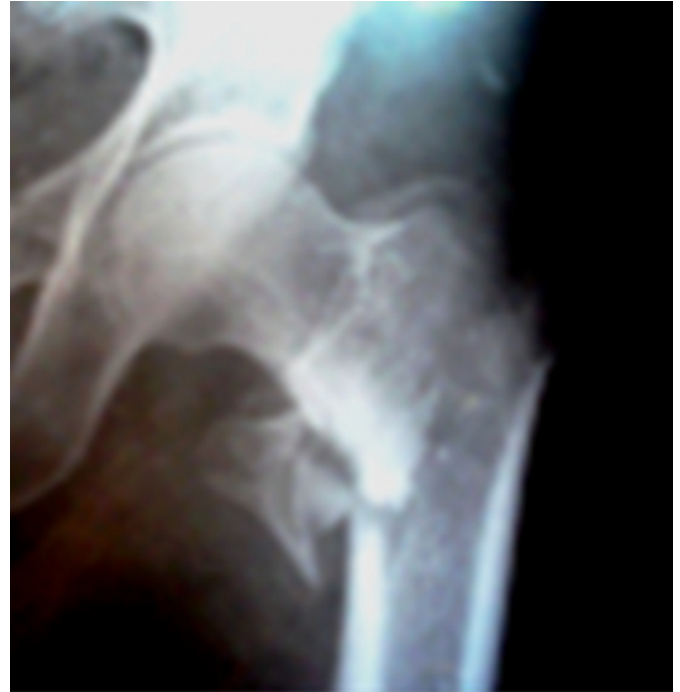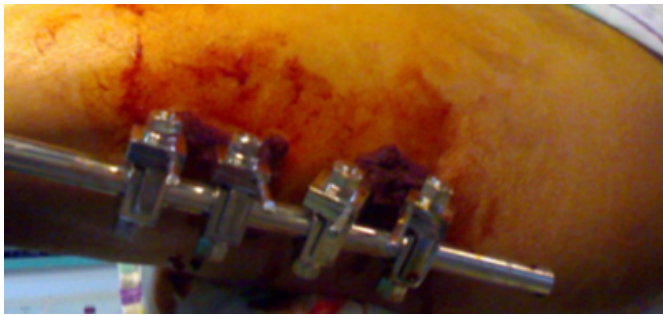
**Figure 3**

Figure 1B: Post Operative Radiograph

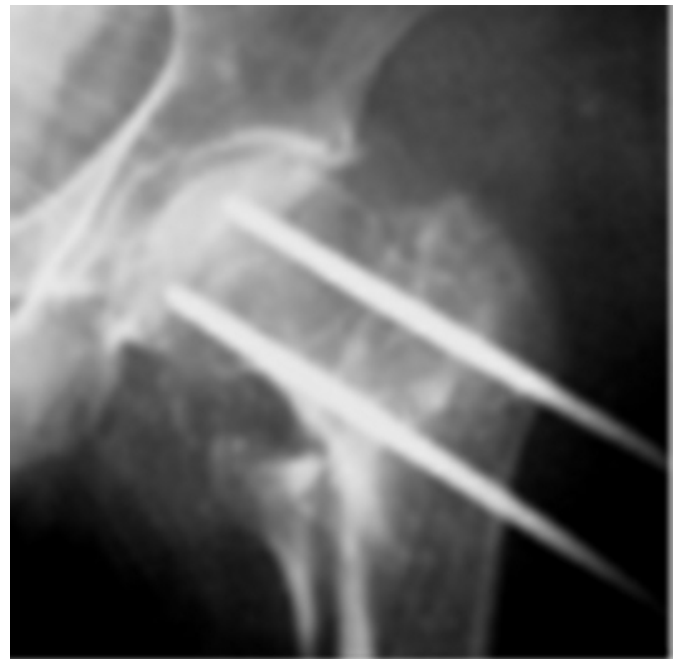

Figure 4

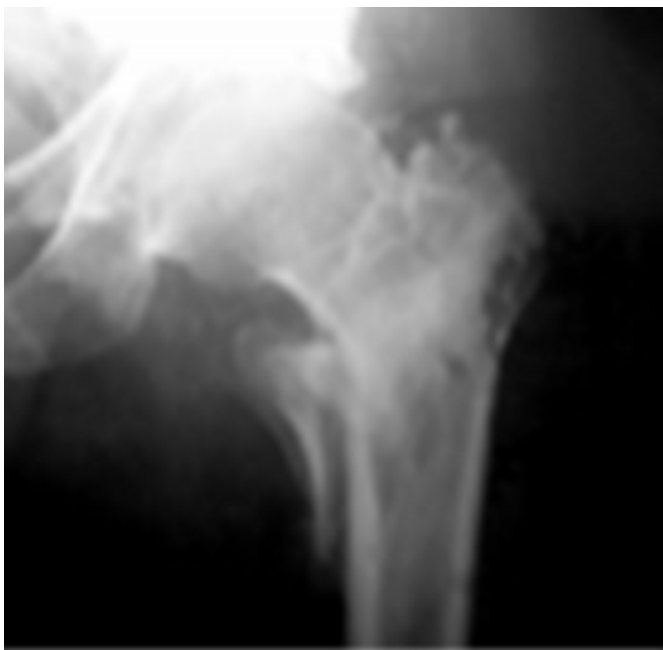Figure 1C: Clinical Photograph



Stability of fracture fixation was checked under image intensifier using varus- valgus stress. Post operatively all patients had a progressive program of weight bearing using a walking frame followed by crutches from day one after surgery. No patient needed blood transfusion intra operatively or post operatively. Appropriate physiotherapy was advised for hip and knee. Pin sites were cleaned daily with saline and betadine. In all the patients external fixator was removed with out anaesthesia after radiological evidence of fracture union. Fig. 1D

Figure 5

Figure 1D: United fracture after removal of External fixation.



FOLLOW UP

Patients were followed regularly for 6-18 months, average follow up was 9 months. Patients were assessed regularly at 6,12,18,24 weeks and at 6 months. Final assessment was done at 6 months using modified Harris hip score ^{18,19} . 2

patients were lost in follow up before 12 weeks. At each visit patients were checked for signs of pin tract infection, ROM of hip and knee, pain at hip and knee, shortening of limb and ambulatory status of the patients. AP and Lateral X rays were taken to assess the loosening or migration of pins and status of union, mal-union in external rotation or varus angulation.

RESULT

Average healing time was 14 weeks (range 11-20 weeks). Maximum ROM was gained in 10 weeks (range 8-16 weeks). There was no non union, although there was delayed union in 3 fractures up to 20 weeks. Pin tract infection was the most common complication, 23 patients were affected by grade 1 pin tract infection which resolved with removal of pins. Shortening of 1cm or more was seen in 5 patients. External rotation deformity of 5° or more was seen in 4 patients. Varus angulation of 5° or more was seen in 10 patients. Only 3 patients had ROM of hip and knee less than 100°. All patients were ambulatory at final follow up. 29 patients needed no support while 10 patients needed support of a cane in opposite hand. 30 patients had no pain at final follow up, while 6 had mild and 3 had activity related pain. 11 patients had mild limp. 3 patients were not able to climb up stairs. Average modified Harris hip score was 67.

DISCUSSION

Hip fractures are among the most devastating injuries in the elderly ¹ . The impact of these injuries goes far beyond immediate clinical consideration and extends into the domains of medicine, rehabilitation, psychiatry, social work and medical economics ² .The mortality rate associated with these fractures is 10-30% in first year after trauma. ³ An increased mortality rate after fracture of the hip is associated with male sex, advanced age, untreated or poorly controlled systemic disease, cerebral dysfunction, institutionalization, internal fixation before control of medical co morbidities, and postoperative complications ⁴ .

Treatment goals for these patients include early rehabilitation, restoration of anatomic alignment and maintenance of fracture reduction. Closed reduction with external fixation has been reported to be cost effective way of managing hip fractures in developing countries. ¹⁷

Sliding hip screw is the preferred method of treatment for the peritrochanteric fractures of the femur ⁷ . Substantial complications like fixation failure, poor functional out come and associated morbidity have been reported with the use of

this fixation system in osteoporotic hip fractures in elderly. ⁷

Vossinakis and Badras ^{8,9} reported patients with trochanteric fractures fixed with orthofix external fixator had better functional result, shorter operative time, less blood loss, less pain and shorter hospital stay than patients with sliding hip screw.

Moroni et al ¹¹ reported less varus malunion in external fixators with hydroxyapatite coated pins, compared to sliding hip screws, however in our study we had more varus mal union and external rotation deformity than reported by this author.

Karan and Singh et al. ¹² in a comparative study of sliding hip screw and external fixator, reported better results with external fixators in terms of blood loss, hospital stay, delay in surgery, duration of surgery there by reducing co morbidity associated with these fractures.

Kazakos K, Lvras DN et al. ¹³ in a study of 56 elderly patients reported no significant difference in function pre injury and post operative follow up of 12 weeks. There was significant reduction in post operative mortality at 6 months compared with other modalities of treatment.

A. Dhal et al. ¹⁴ reported 154 Intertrochanteric fractures fixed with external fixator, good fixation and early ambulation was achieved in all cases. Complications like pin tract infection, and delayed loss of reduction was seen in 6 & 9 cases respectively. Average time of union was 16 weeks.

Pin tract infection and stiffness of knee are reported as most common complications associated with external fixation of Intertrochanteric fractures. ^{8,9,10,15,16} In our study stiffness of knee was not a complication probably we placed Schanz pins more proximally in femur. Superficial pin tract infection was seen in 23 patients which resolved with removal of pins. There was secondary loss of reduction with varus angulation and external rotation deformity in 14 patients.

We concluded that external fixation of Intertrochanteric fractures can provide an alternative method of fixation in elderly high risk patients. It can be done under local anesthesia with minimal blood loss, reduces the complications associated with major surgical procedures, is cost effective and has good final functional outcome.

CORRESPONDENCE TO

Dr. Shafaat Rashid Tak. M.S. Orthopaedics, Registrar

Department of Orthopedics, Government Medical College
Srinagar, India. Email: shafaatrahsid@yahoo.co.in
Phone: +91-9419005535 Fax : +91-0194243730

References

1. Koval KJ, Zuckerman JD. Current Concepts Review: Functional Recovery after Fracture of the Hip. *J Bone Joint Surg Am* 1994;76:751.
2. Kulkarni GS, Limaye R, Kulkarni M, Kulkarni S. Intertrochanteric fractures. *Indian J Orthop* 2006;40:16-23
3. Cummings SR, Nevitt MC: A hypothesis :the cause of hip fractures. *J Gerontol* 1989;44, M107-111.
4. Koval KJ, Aharonoff GB, Rokito AS, et al. Patients with Femoral Neck and Intertrochanteric Fractures. *Clin Orthop* 1996;330:166.
5. Levelle DG. Fractures of hip. In Canale ST, ed *Campbell operative Orthopaedics* 10th ed. Vol. 3: 2873.
6. Muller ME, Allgower M: *Technique of internal fixation of fractures*. AO Manual of internal fixation 4th ed. Springer Verlag 2001.
7. Larsson S. Treatment of osteoporotic fractures. *Scand J Surg*. 2002;91:140-6.
8. Vossinakis IC, Badras LS: External fixator compared with Sliding hip screw for Pertrochanteric fractures of femur. *J Bone Joint Surg [Br]* 2002;84B:23-9.
9. Vossinakis IC, Badras LS: Management of Pertrochanteric fractures in high risk patients with an external fixation. *Int Orthop* 2001;25:219-22.
10. Devgan A, Sangwan SS. External fixator in management of trochantric fractures in high risk geriatric patients: a friend to elderly. *Indian J Med Sci* 2002;56:285-90.
11. Moroni A, Fadni C, Pegreff F. Dynamic hip screw compared with external fixation treatment of osteoporotic pertrochanteric fractures: A prospective randomized study. *J Bone joint Surg [Am]* 2005;87-A:753-9.
12. Karn NK, Sing GK, Kumar P, Sherestha BP, Sing MP. Comparison between external fixation and sliding hip screw in the management of trochantric fractures of femur in Nepal. *J Bone Joint Surg [Br]* 2006;88-B:1347-50.
13. Kazakos K, Lvras DN, Verettas Illakis I, Xarchas K: External fixation of Intertrochanteric fractures in elderly high-risk patients. *Acta Orthop Belg*. 2007 Feb;73(1):44-8.
14. Dhal A, Varghese M, and Bhasin VB. External fixation of Intertrochanteric fractures of femur. *J Bone Joint Surg [Br]*;1991;73-B:955-58.
15. Tomak Y, Kocaoglu M, Piskin A, Yildiz C, Gulman B, Tomak L. Treatment of intertrochanteric fractures in geriatric patients with a Modified external fixator. *Injury*. 2005;36:635-43.
16. Subasi M, Kesemenli C, Kapukaya A, Necmioglu S. Treatment of intertrochanteric fractures by external fixation. *Acta Orthop Belg*. 2001;67:468-74.
17. Kamble KT, Murthy BS, Pal V. External fixation in unstable Intertrochanteric fractures of femur. *Central institute of Orthopaedics, Safdarjang Hospital, New Delhi, India*. PMID:8730390.
18. Harris W H. Traumatic arthritis of the hip after dislocation and acetabular fracture treatment by mold arthroplasty. *J Bone Joint Surg (Am)* 1969;51A:737-55.
19. Fredlund VG. Total hip replacement in Mseleni joint disease undertaken in a rural hospital: five year follow up. *Electronic doctor* 2003;PIMD:2125918.
20. White BL, Fisher, WD, Laurin CA. Rate of mortality for elderly patients after fracture of the hip in the 1980s. *J Bone Joint Surg Am* 1987;69:1335.18.

Author Information

Shafaat Rashid Tak, M.S.Orthopaedics

Registrar, Department of Orthopedics Government, Medical College

Gh Nabi Dar, M.S. Orthopaedics

Registrar, Department of Orthopedics Government, Medical College

K.A. Kangoo, M.S. Orthopaedics

Associate Professor, Department of Orthopedics Government, Medical College

M.A. Halwai, M.S. Orthopaedics

Associate Professor, Department of Orthopedics Government, Medical College