

# Characteristics Of The Mental Foramen In Different Populations

T Hasan

---

## Citation

T Hasan. *Characteristics Of The Mental Foramen In Different Populations*. The Internet Journal of Biological Anthropology. 2010 Volume 4 Number 2.

## Abstract

The mental foramen is an oval or circular opening on the anterior surface of the mandible; through which the mental bundle exits and innervates the ipsilateral chin, lower lip and gingiva. Mental foramen is the determinant of the mental triangle and forms an important landmark of the human mandible. It holds strategic importance during invasive and non invasive procedures of the mandibular region. It is considered a highly suitable model to study bone remodeling activity and the maturity pattern of the human mandible. Its modal position varies according to age and race and has been cited ranging from sub canine to sub molar in different populations. Variations like multiple or absent foramina are often encountered. These variations in the position and number of the mental foramen have been reported to exhibit a clear racial trend in the pattern of their occurrence. Recent advancements in clinical dentistry have increased the possibility of procedures in the mental region and a detailed knowledge of the mental foramen anatomy may not only aid in the prevention of post surgical neurovascular complications and morbidity; but also hold the potential of contributing as an identifying maxillofacial anthropologic characteristic feature for different populations. The awareness of its typical morphologic features in different ethnicities is pivotal for anatomists, ortho-dentists, surgeons and paleoanthropologists alike and a more elaborate mention of the same in our standard anatomy textbooks would be a welcome change.

## ABBREVIATIONS

MF - mental foramen

AMF - accessory mental foramen

## INTRODUCTION

The mental foramen represents the termination of the mental canal. It is an oval or circular opening on the anterior surface of the mandible. The inferior alveolar nerve and artery, after traveling through the mandibular foramen, exit at the mental foramen as the mental nerves and vessels which innervate the lower teeth, lip, gingiva and lower face.<sup>1,2</sup> The mental foramen is usually located below or between the apex of the first and second premolar<sup>3,4</sup>. (Fig.1) The direction of opening is posteriorly outward and upward.<sup>3</sup> Variations of the mental foramen are often encountered, (Fig.2) ranging from difference in modal position<sup>4,5,6</sup> or presence of accessory foramina<sup>7</sup> or even complete absence in some rare cases<sup>8,9,10</sup>. These variations have been reported to exhibit a clear racial trend.<sup>4,5,6</sup>

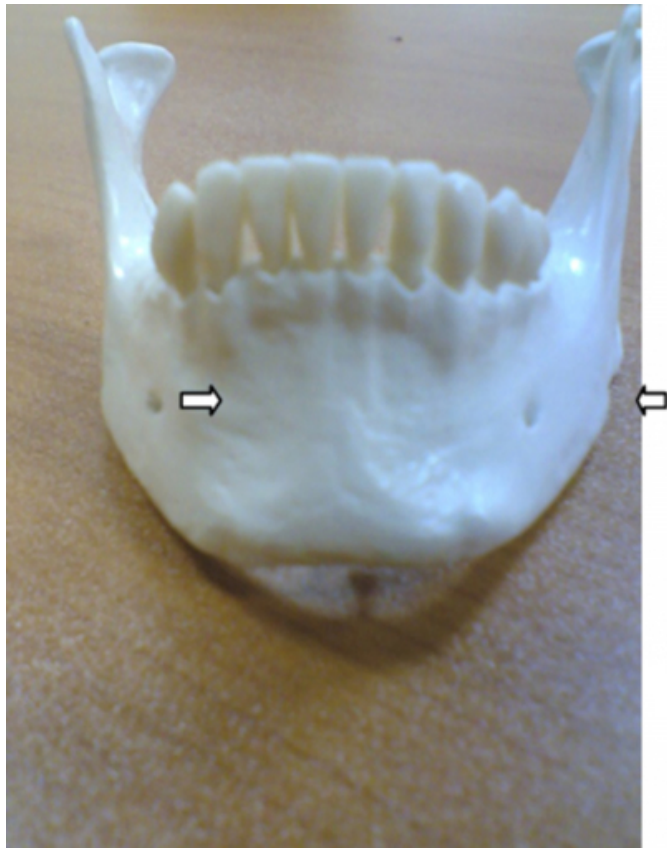
The mental foramen is a strategically important landmark during osteotomy procedures, anesthetic nerve blocks and prevention of neurovascular complications after invasive

procedures on the lower jaw. Its anatomy is important for evaluating the morphometric symmetry of the mental triangle, microscopic and macroscopic morphology and maturity of the human mandible, bone remodeling activity and paleoanthropologic features of the facial skeleton in different populations.

This review elucidates the population based characteristic morphologic features of the mental foramen.

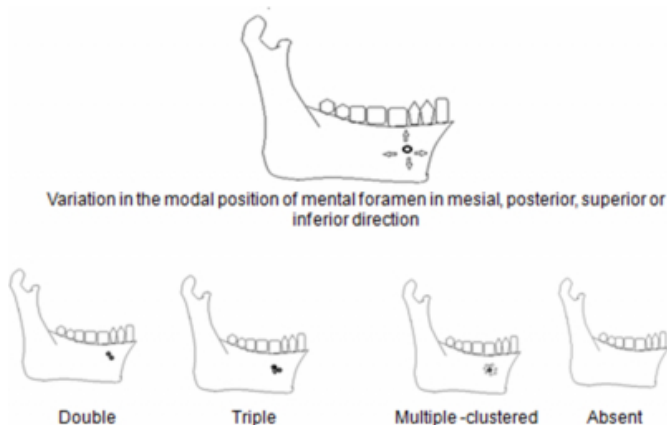
**Figure 1**

Fig 1- Normal position of the mental foramen on the anterior surface of the human mandible



**Figure 2**

Fig.2 Variations in the position and number of the mental foramen as observed in different populations



## DISCUSSION

Paleoanthropologists believe that tooth position may not be a reliable indicator of mental foramen position because of variability of tooth size within and between taxa and during eruption levels. The MF morphology, (in terms of modal

position and number), varies not only according to age<sup>11</sup>, sex<sup>12,13</sup> and ethnicity;<sup>4,5,6</sup> but even within the same race; in different geographic regions<sup>14,15,16</sup> and within the inhabitants of the same geographic area.<sup>17</sup>

## GROSS MORPHOLOGY OF THE MENTAL FORAMEN IN DIFFERENT POPULATIONS

Medical literature is not unified in the description of the morphology of the mental foramen. Different anatomy and radiology text books give contradicting statements regarding the morphometric characteristics of the mental foramen; thereby depicting variable racial trends.<sup>6</sup>

**Africans:** The mental foramen was observed to exhibit dimorphism; it was 14.89 mm above the lower border of the mandible in males and 14.21 mm in females. Also, it was 16.16 mm below the alveolar ridge in males and 15.66 mm in females. The average size of the long and the short axis of the foramen were 5.66mm and 3.97mm respectively in the male and 4.99 mm and 3.87 mm respectively in the female mandibles.]12These measurements were statistically similar to another study on mandibles from Alagoas state.<sup>18</sup>

**Tanzanians:** The mental foramen was frequently located below the apex of the second premolar and between the 2<sup>nd</sup> premolar and 1<sup>st</sup> molar. A significantly less common location was between 1<sup>st</sup> and 2<sup>nd</sup> premolars and below 1<sup>st</sup> molar. The mental foramen was a-symmetrically located between the right and left sides and predominantly oval. The direction of opening was mostly superior and postero-superior and rarely labial, mesial or posterior.<sup>19</sup>

**Mongoloids:** The mental foramen was observed to be located in line with the longitudinal axis of the lower second premolar.<sup>5</sup>

**Caucasoids:** It was more medially located, between first and second premolars.

**Blacks:** It was found to be placed more posterior in blacks than in whites; between the second premolar and first molar.<sup>5,20</sup>

**Byzantiums:** The most common position of MF was between the first and second premolars on the right side, whereas on the left side it was in line with the lower second premolar.<sup>21</sup>

**Japanese:** The MF was observed to lie at an average height of 12.96 mm from the inferior edge of mandible. The largest horizontal diameter ranged between 3.25-3.32mm whereas the vertical diameter ranged from 2.38-2.39mm between the

right and left sides. The MF was located in similar statistic proportions between the 1st and 2nd premolars and below the 2nd premolar on the right side. On the left side, it was mostly between the 1st and 2nd premolars. The MF was predominantly single and oval with larger horizontal diameter.<sup>18</sup>

Sri Lankans: The most common MF position was in line with the longitudinal axis of the lower second premolar followed by a position between first and second premolar. The mean transverse and vertical diameters of the foramen were 3.31 and 2.5mm, respectively. The mental foramen was located 24.87 mm (right side) and 24.77 mm (left side) lateral to the symphysis menti. In a majority of cases, the mental foramen was oval in shape and its usual direction of opening was postero-superior. The incidence of multiple mental foramina was 3.92%.<sup>22</sup>

Israelis: The mental foramen was found to be predominantly single and oval with an average long diameter of 2.37 mm. The common location was between the roots of 1<sup>st</sup> and 2<sup>nd</sup> premolar.<sup>11</sup>

Zimbabweans: The mental foramen was mostly oval shaped. The frequency of occurrence of the mental foramen was highest below the lower second premolar on the right side and between 2<sup>nd</sup> premolar and 1<sup>st</sup> molar on the left side. In a vertical plane, the mental foramen was predominantly located under the midpoint of the line joining the lower border of the mandible to alveolar ridge.<sup>23</sup>

Malawians: The mental foramen was seen to be oval in shape, oriented postero superiorly, located inferior to the second premolar tooth and bilaterally symmetrical in a majority of cases. Its vertical position was slightly below the midpoint of the distance between the lower border of the mandible and the alveolar margin.<sup>24</sup>

Turkish: The distance of the mental foramen from the lower border of the mandible was noted to be 14.61mm and 14.29 mm on the right and the left sides, respectively.<sup>25</sup> The distance from the upper border was 13.6 mm and 14.62 mm on the right and left sides. The horizontal diameter of the mental foramen was 2.93 mm on the right side and 3.14 mm on the left side. The vertical diameter was 2.38 mm and 2.64 mm on the right and left sides respectively. The mental foramen was found under the root of the second premolar in most mandibles. The average inclination was 96.82 degrees which was in accordance with the findings of another study done on dry mandibles from Alagoas State.<sup>18</sup>

Jordanians: The mental foramen was seen most commonly below and between the mandibular premolar teeth, and the most frequent appearance was the continuous type; showing similarity to Caucasian populations.<sup>26</sup>

### THE LOCATION OF THE MENTAL FORAMEN IN RELATION TO CHRONOLOGICAL AGE

The MF location also shows changes with age.<sup>11</sup> In children before tooth eruption, the MF is somewhat closer to the alveolar margin; during the eruption period, the MF descends to half way between the upper and lower margins and in adults with the teeth preserved, the MF is somewhat closer to the inferior border. With loss of teeth and bone resorption the MF moves upwards closer to the alveolar border. In extreme cases of resorption; the MF and the adjacent part of the mandibular canal are open at the alveolar margin. The mental nerve emerges from the MF closer to or at the alveolar border; according to the degree of resorption. In severe resorption, the mental nerve and the final part of the inferior alveolar nerve may be found directly under the gums.<sup>11</sup>

### VARIATIONS OF THE MENTAL FORAMEN

A lot of research done in the past highlights the genetic and racial influence on mental foramen variations. In 1970; Kadanoff et al demonstrated the variations in the number of mental foramina ranging from being absent to double or triple; equal or unequal sized; close or widely separate or even multiple; in the form of a cluster.<sup>27</sup> Identifying these variations by a prior digital scan may reduce the incidence of post procedural paralytic and hemorrhagic complications in the mental region, thereby significantly reducing morbidity.

### ACCESSORY FORAMEN

Unlike non human primates, the mental foramen is usually single in humans, but accessory foramina have been recorded. It has been suggested that separation of the mental nerve into several fasciculi earlier than the formation of the mental foramen until the 12th gestational week could be a reason for the formation of accessory mental foramen.<sup>28</sup>

### POPULATION SPECIFIC INCIDENCE ACCESSORY (MULTIPLE) MENTAL FORAMINA

The incidence of accessory foramina varies between ethnic groups, while non-Caucasians may have a higher incidence than Caucasians; there are yet no reported gender differences.<sup>28,29</sup> The incidence of accessory mental foramen among various ethnic groups, is reported as follows: 2.6% in French; 1.4% in American Whites; 5.7% in American

Blacks; 3.3% in Greeks; 1.5% in Russians; 3.0% in Hungarians; 9.7% in Melanesians; and 3.6% in Egyptians.<sup>7</sup> In the Japanese population, the incidence was found to be 6.7-12.5%, which is rather high as compared to other ethnic groups.<sup>29</sup> The multiple foramina are usually unequal in size: a single large foramen with smaller (satellite) foramina.<sup>30</sup> Danny.R. , in 1998, demonstrated AMF to be more frequent in Nazca, African Americans and less common in Asian Indians and American Whites. The incidence occurrence was equal for right- and left sides. However, in certain ethnic groups like African Americans, AMF were reported to be more frequent in males, though this observation may not be a representative of all populations.<sup>31</sup>

### CLINICAL SIGNIFICANCE OF ACCESSORY (MULTIPLE) MENTAL FORAMINA

The presence of nerve fibers in accessory foramina may be significant in the effectiveness of local anesthesia following a routine inferior alveolar nerve block.<sup>32,33</sup> Blood vessels present in accessory foramina can be a cause of intraosseous hemorrhages during implant procedures.<sup>34,35</sup> The possible role of accessory foramina and their neurovascular contents in the spread of tumors of this region has also been recognized.<sup>36-39</sup>

### ABSENT MENTAL FORAMEN

Absent mental foramen is an extremely rare anatomic variation. Infact, man is the only primate known to have agenesis of the mental foramen. Accessory mental foramina are a more common variation than MF absence in humans.<sup>40</sup> The frequent reasons for absence may range from atrophy, post traumatic fibrosis, osteoblastic hyperplasia, geriatric bony resorption or congenital agenesis.<sup>40</sup>

### POPULATION SPECIFIC INCIDENCE OF ABSENT MENTAL FORAMEN

Medical literature is very scant when it comes to reports of absent mental foramen. Till now, published records state only 'four cases'<sup>8,41,42,43</sup> of unilateral absence and a 'single' case of bilateral absence<sup>40</sup>. Unilateral absence of the mental foramen is very rare; the frequency ranges from less than 0.02%<sup>9</sup> to 0.47%<sup>8</sup>; while the frequency of bilateral absence is statistically negligible.<sup>40</sup> The incidence of absence has been equally reported between Caucasians and Blacks; and no particular genetic or racial trend has been observed regarding this phenomenon.<sup>40</sup>

### CLINICAL SIGNIFICANCE OF ABSENT MENTAL

## FORAMEN

Since the mental foramen marks the exit of mental nerves and vessels (the sensory supply of the lower lip-chin area), absence of MF would mean no outlet for this neurovascular bundle and probable sensory alterations in that area. Clinical implications would include ineffective mental block in anesthesia. Moreover, the subjects could possibly present with some neurosensory disturbance in the mental region or around lips due to this rare condition.<sup>40</sup>

### DETECTION OF VARIATIONS IN THE MENTAL FORAMEN

Detection is possible by macroscopic inspection of dry mandibles, plane or periapical radiography or computed tomography scans. However, radiographic localization is difficult due to lack of consistent anatomical landmarks for reference, and the foramen cannot be clinically visualized or manually palpated. The foramen may not appear on conventional radiographs, and linear measurements need to be adjusted to account for radiographic distortion and discrepancies in the findings. Computerized tomography (CT) scans are usually more accurate.

### SIGNIFICANCE OF THE MENTAL FORAMEN IN ROUTINE CLINICAL PRACTICE

Sometimes, an anterior loop of the mental nerve may be present mesial to the mental foramen and may cause mental nerve injury during dental implants.<sup>44</sup> Guidelines to verify the position of the mental foramen and validating the presence of an anterior loop of the mental nerve while establishing a zone of safety (in millimeters) for implant placement can avoid such nerve injury. Furthermore, radiographic assessments result in a high percentage of false negative findings. These false findings can cause sensory dysfunction due to inferior alveolar nerve damage in the foraminal area. The foramen may occasionally misdiagnose with a radiolucent lesion in the apical area of the mandibular premolar teeth. Additionally, local anesthesia of the terminal incisive branches of the inferior alveolar and mental nerves can be obtained effectively if the mental foramen is correctly identified. Therefore, computerized tomography (CT) scans are more accurate for detecting the mental foramen than conventional radiographs.

### DEVELOPMENTAL ASPECTS AND PALEOANTHROPOLOGIC SIGNIFICANCE OF THE MENTAL FORAMEN

Histological and embryological studies on human fetus sections characterize the mental foramen of the mandible as

a highly suitable model to study the spatial relationship of nerves, vessels and dental primordia during bone remodeling activity. The MF exhibits changing remodeling activity at different gestational ages- apposition, inactivity, and resorption.<sup>45</sup> A study on human fetuses revealed the earliest position of the MF to be in the interstitial bone between primary canine and first molar. A positional change in the dorsal direction was described during the first half of the prenatal period.<sup>46</sup>

Paleoanthropologists believe that the mental foramen is the landmark for determining the maturity of the human mandible. Modern human adults are truncated or paedomorphic, in mental foramen position with respect to Neanderthals. However, adults of the two taxa have similar bi-mental foramen breadth with respect to mandibular size.<sup>47</sup>

### CONCLUSION

The recent trend of replacement of missing teeth by dental implants and the increasing frequency of orthognathic surgeries have highlighted the clinical significance of the mental foramen. Mental foramen variations often remain unnoticed and undiagnosed. Even so, in order to obtain effective nerve block and to avoid post-procedural neurovascular complications in the mental region, particular attention should be paid to the morphology of the mental foramen. A prior CT scan can elucidate jaw structures and prevent patient morbidity. Therefore, a detailed knowledge of the mental foramen anatomy and its variations in different populations is essential for dentists, orthopedicians and anatomists alike. A future prospect of interest lies in their possible contribution to the maxillofacial anthropologic characteristic identification for different populations and races. A more elaborate mention of its population based morphology and clinically relevant variations in our standard anatomy text books would be a welcome change.

### References

1. Williams P L, Bannister LH, Berry MM., Collins P, Dyson M, Dussek, J. E. Gray's Anatomy: The anatomical basis of medicine and surgery. 38th Ed. New York, Churchill Livingstone; 2000.
2. Bavitz JB, Harn SD, Hansen CA, Lang M. An anatomical study of mental neurovascular bundle implant relationships. *Int J Oral Maxillofac Impl* 1993; 8: 563-573
3. Haghani S, Rokouei M. Radiographic evaluation of the mental foramen in a selected Iranian population. *Indian J Dent Res*. 2009; 20: 150-152.
4. Zivanovic S. Some morphological characters of the East African mandible. *Acta. Anat.* 1970; 77:109-119.
5. Green, R. M. The position of the mental foramen: A comparison between the Southern (Hong Kong) Chinese and other ethnic and racial groups. *Oral. Surg. Oral. Med. Oral. Pathol.* 1987; 63:287-290.
6. Santini A, Land M.A. Comparison of the position of the mental foramen in Chinese and British mandibles. *Acta. Anat.* 1990;137:208-212.
7. Sawyer DR, Kiely ML, Pyle MA. The frequency of accessory mental foramina in four ethnic groups. *Archives of Oral Biology*. 1998; 43: 417-420.
8. Azaz B, Lustmann J. Anatomical configurations in dry mandibles. *Br. J. oral Surg* 1973 ;2:1-9
9. Inke G, Von Partieller Verschluss des Mandibular- kanals mit Fehlen des Foramen mentale am Unter – kiefer eines Afrikaners *Anat Anz* .1968;123:111-113
10. De Freitas V, Madeira MC, Toledo Filho JL, Chagas CF. Absence of the mental foramen in dry human mandibles. *Acta Anat (Basel)*. 1979; 104: 353-355.
11. A. Gershenson H, Nathan E, Luchansky. Mental Foramen and Mental Nerve: Changes with Age *Acta Anatomica*.1986;126:21-28
12. Souaga K, Adou A, Angoh Y. Topographical and morphological study of the mandibular foramen in black Africans from the Ivory Coast. *Odontostomatol. Trop*. 2004 ;27(105):17-21.
13. Danny R. Sawyer, Michael L. Kiely and Marsha A. Pyle The frequency of accessory mental foramina in four ethnic groups *Archives of Oral Biology* 1998; 43:417-420
14. Phillips JL, Weller RN, Kulild JC. The mental foramen: Part II. Radiographic position in relation to mandibular second premolar. *J of Endodontics* 1992; 18: 271-274.
15. Weller RN, Phillips JL., Kulild JC. The mental foramen: Part III. Size and position on panoramic radiograph. *J of Endodontics* 1992; 16: 383-386.
16. Lindh C, Petersson A, Kling B. Measurements of distances related to the mandibular canal in radiographs. *Clin Oral implant Res*. 1995 ; 6 : 96-103.
17. Ari I Kafa IM, Basar Z, Kurt M A. The localization and anthropometry of mental foramen on late Byzantine mandibles. *Coll. Antropol*. 2005;29:233-236.
18. Oliveria J E M., Arajo, A. L. D, Silva C. M. F, Sousa R C F, Lima FJC. Morphological and morphometric study of the mental foramen on the M-CP-18 jiachenjiang point. *Int. J. Morphol*. 2009; 27(1):231-238.
19. Fabian FM. Position, shape and direction of opening of the mental foramen in dry mandibles of Tanzanian adult black males. *Ital J Anat Embryol*. 2007; 112(3):169-177.
20. Cutright B, Quillopa N, Schubert W. An anthropometric analysis of the key foramina for maxillofacial surgery. *J. Oral. Maxillofac. Surg*. 2003; 61:354-357.
21. Ikiz T, Erem. Relation of the mental foramen to teeth on the mandibles belonging to the Byzantine period *International journal of anthropology*. 1997;12 :1-4
22. Ilayperuma I, Nanayakkara G, Palahepitiya N. Morphometric analysis of the mental foramen in adult Sri Lankan mandibles. *Int. J. Morphol*. 2009; 27(4):1019-1024.
23. Mbajorgu EF, Mawera G, Asala SA, Zivanovic S. Position of the mental foramen in adult black Zimbabwean mandibles: a clinical anatomical study. *Cent Afr J Med*. 1998 ;44:24-30.
24. Igbigbi PS, Lebona S. The position and dimensions of the mental foramen in adult Malawian mandibles. *West Afr J Med*. 2005;24:184-189.
25. Oguz O, Bozkir M. G. Evaluation of location of mandibular and mental foramina in dry, young, adult human male, dentulous mandibles. *West Indian Med. J*. 2002; 51(1):14-16.
26. Taiseer AK, Abed AH, Hamasha KTA. Position of the mental foramen in a northern regional Jordanian population *Surgical and radiologic anatomy*. 2007;29(3): 231-237.
27. Kadanoff D, Mutafov ST, Jordanov J, Über die Hauptöffnungen resp. Incisurae des Gesichtsschädels

- (Incisura frontalis seu Foramen frontale, Foramen supraorbitale seu Incisura supraorbitalis, Foramen infraorbitale, Foramen mentale). Gegenbaurs Morphol. Jahrbuch, 1970; 115: 102-118.
28. Naitoh M, Hiraiwa Y, Aimiya H, Gotoh K, Arijji E. Accessory mental foramen assessment using cone-beam computed tomography. *Oral Surg Oral Med Oral Pathol Oral Radiol Endod* 2009; 107: 289-294
  29. Toh H, Kodama J, Yanagisako M, Ohmori T. Anatomical study of the accessory mental foramen and the distribution of its nerve. *Okajimas Folia Anat Jpn*. 1992; 69: 85-87.
  30. Soikkonen K, Wolf J, Ainamo A, Xie Q. "Changes in the position of the mental foramen as a result of alveolar atrophy". *J Oral Rehabil*. 1995; 22: 831-3.
  31. Danny R. Sawyer, Michael L. Kiely and Marsha A. Pyle. The frequency of accessory mental foramina in four ethnic groups *Archives of Oral Biology* 1998; 43: 417-420
  32. Agnieszka P, Małgorzata B. Accessory mandibular foramina: Histological and immunohistochemical studies of their contents. *Archives of Oral Biology*. 2010; 55: 77-80
  33. Madeira C, Percinoto M, Das G, Silva M.. Clinical significance of supplementary innervation of the lower incisor teeth: a dissection study of the mylohyoid nerve. *Oral Surg Oral Med Oral Pathol*. 1978; 46: 608-614.
  34. E. Kaufman N, Serman J, Wang P.D. Bilateral mandibular accessory foramina and canals: a case report and review of the literature, *Dentomaxillofac Radiol*. 2000; 29: 170-175.
  35. McDonnell D, Nouri M.R., Todd M. The mandibular lingual foramen: a consistent arterial foramen in the middle of the mandible, *J Anat*. 1994; 184: 369-371.
  36. Fanibunda K, Matthews JN. Relationship between accessory foramina and tumour spread in the lateral mandibular surface. *J Anat*. 1999; 195: 185-190
  37. McGregor JA, MacDonald G. Patterns of spread of squamous carcinoma within the mandible. *Head Neck Surg*. 1989; 11: 457-461.
  38. J.A. McGregor and D.G. MacDonald, Routes of entry of squamous cell carcinoma into the mandible. *Head Neck Surg*. 1988; 10: 294-301.
  39. McGregor JA, MacDonald DG. Spread of squamous cell carcinoma to the nonirradiated edentulous mandible-a preliminary report. *Head Neck Surg*. 1987; 9: 157-161.
  40. Hasan T, Fauzi M, Hasan D. Bilateral absence of the mental foramen; a rare variation. *International journal of anatomic variations*. 2010; 3: 167-169
  41. De Freitas V, Madeira MC, Toledo Filho JL, Chagas CF. Absence of the mental foramen in dry human mandibles. *Acta Anat (Basel)*. 1979; 104(3): 353-355.
  42. Freitas V, Teixeira Pinto C, Zorzetto NL, Madeira MC, Pieffer CR. Contribuição para o estudo da localização e das variações do forame mental em mandíbulas humanas. *Revta bras. Odontol*. 1975; 194: 156-160
  43. Freitas V, Madeira MC, Teixeira Pinto C, Zorzetto NL. Direction of the mental canal in human mandibles. *Austr. dent. J*. 1976; 21: 338-340.
  44. Arzouman MJ, Otis L, Kipnis V, Levine D. Observation of the anterior loop of inferior alveolar canal. *Int J Oral Maxillofac Impl*. 1993; 8: 295-300.
  45. Ralf J, Radlanski, Herbert R, Souzan L, Richard A, Schneider. Bone remodeling during prenatal morphogenesis of the human mental foramen. *European Journal of Oral Sciences*. 2004; 112: 301-310.
  46. Kjaer I. Formation and early prenatal location of the human mental foramen. *Sc J Dent Res*. 1989; 97: 1-7
  47. Williams FL, Krovitz GE. Ontogenetic migration of the mental foramen in Neandertals and modern humans. *J Hum Evol*. 2004; 47(4): 199-219

**Author Information**

**Tabinda Hasan**

Jazan University