

# Koebner Phenomenon in Radiation Associated Angiosarcoma of the Breast: Linear Metastasis in Split Skin Graft Donor Site

A Chhabra, A Goyal, R Mansel

---

## Citation

A Chhabra, A Goyal, R Mansel. *Koebner Phenomenon in Radiation Associated Angiosarcoma of the Breast: Linear Metastasis in Split Skin Graft Donor Site*. The Internet Journal of Surgery. 2006 Volume 9 Number 2.

## Abstract

Secondary angiosarcoma of the breast following radiotherapy though rare is a well recognised entity. The estimated incidence of developing radiation associated angiosarcoma after breast conserving surgery ranges from 0.9% to 1.6% [1, 2]. We report an 80 year old female with a metastatic lesion in the skin donor site secondary to radiation associated angiosarcoma. To our knowledge, this is the first case to be reported of a patient with metastatic lesion in the skin graft donor site secondary to radiation associated cutaneous angiosarcoma, possibly due to koebner phenomenon. A possible pathological basis for the sequence of events is discussed.

## INTRODUCTION

Angiosarcoma is a malignant vascular tumour of endothelial origin and can be either primary or secondary. Secondary angiosarcoma of the breast can occur in patients with chronic lymphoedema following an axillary dissection or after breast conserving surgery followed by radiotherapy.

We describe a case of radiation induced angiosarcoma of the breast with linear metastasis along the split skin graft donor site, possibly due to koebner phenomenon.

The koebner phenomenon is the localizing of skin disease to a site of trauma in an individual who is susceptible to that disease. It is a well described entity in benign lesions such as psoriasis and lichen planus and malignant lesions such as melanoma and Kaposi's sarcoma. However, it has not been described in association with radiation induced angiosarcoma.

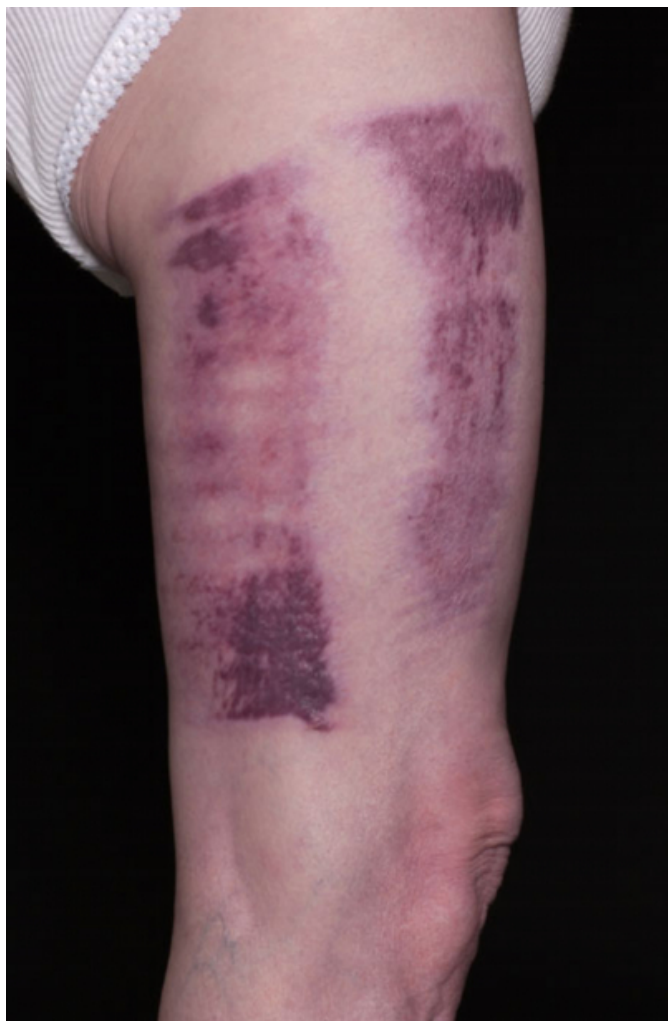## CASE REPORT

An 80 year old female underwent breast conserving surgery, along with adjuvant radiotherapy to the breast for right sided invasive breast cancer in 1993. She developed radiation induced breast angiosarcoma 10 years following completion of the primary treatment. The diagnosis was confirmed by biopsy and she underwent mastectomy along with immediate latissimus dorsi flap reconstruction to treat the breast angiosarcoma. Unfortunately the angiosarcoma recurred in

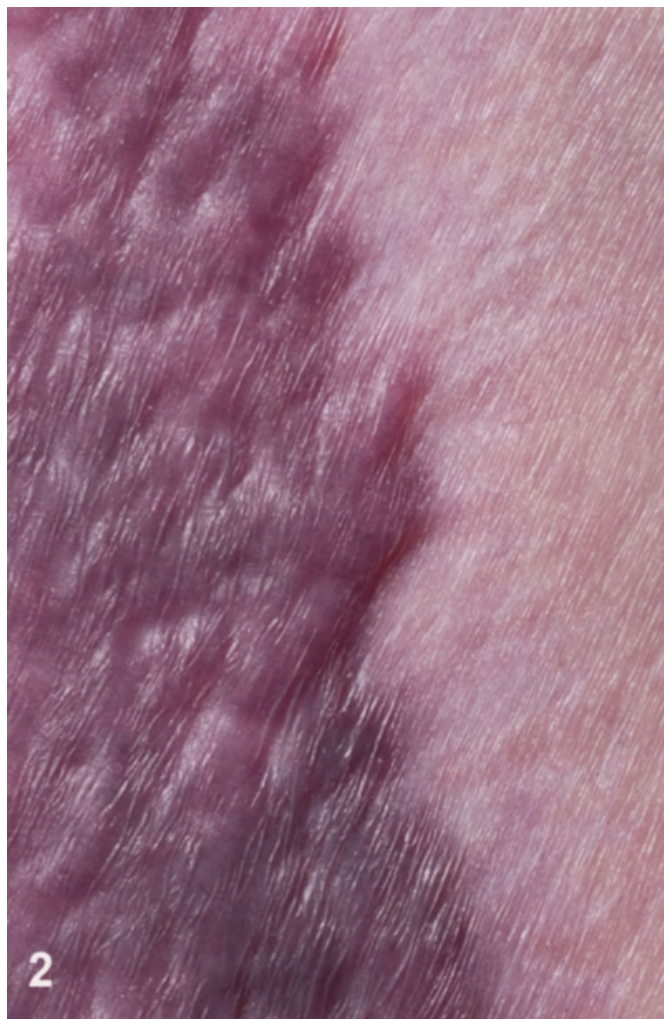
the latissimus dorsi flap donor scar. The recurrent tumour was excised and the defect was closed with a split thickness skin graft from the right thigh. She remained symptom free for 3 months, when she developed multiple linear nodules along the skin graft donor site (Fig: 1&2), skin graft recipient site (Fig: 3) and flap recipient site (Fig: 4). These recurrences were treated with palliative radiotherapy and systemic chemotherapy.

**Figure 1**

Figure 1 & 2: Metastatic linear nodules at the split skin graft donor site

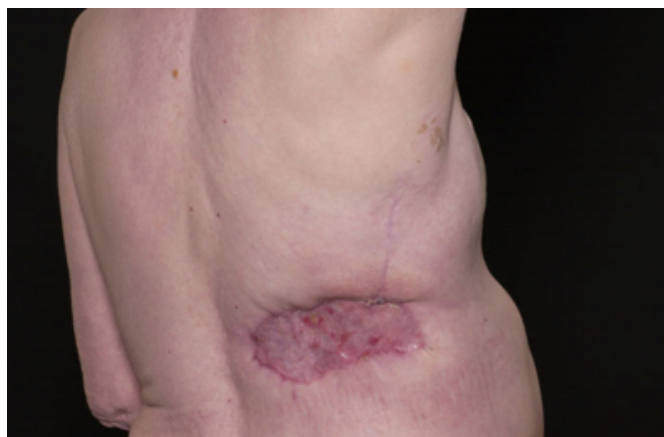


**Figure 2**



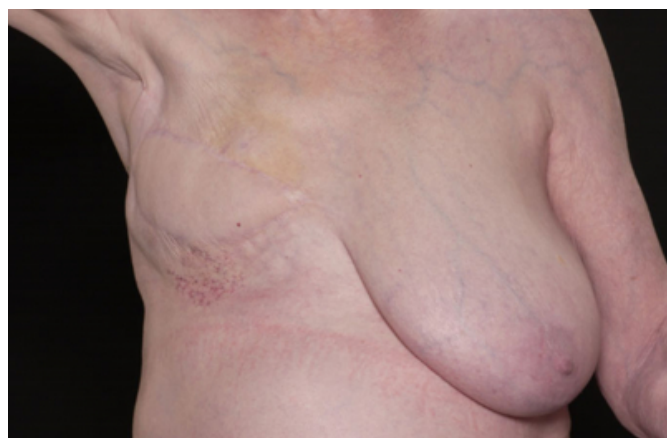**Figure 3**

Figure 3: Metastatic multiple reddish nodules at the skin graft recipient site



**Figure 4**

Figure 4: Recurrent reddish purple lesions of the skin at the right latissimus dorsi flap recipient site



## DISCUSSION

Secondary angiosarcomas can arise in the field of radiation therapy but are fortunately rare despite the widespread use of radiotherapy to treat the breast carcinoma. Unlike other radiation therapy-induced sarcomas, secondary angiosarcoma often occurs within a short time interval following radiation therapy. Secondary angiosarcoma is reported to develop after exposure to radiation, with a latent period of approximately 7.6 years (range, 2-10 years) in various series [3, 4]. Characteristically this tumour presents as purple discoloration of the skin, reddish-brown to purple, raised rash or nodule, bluish eczematous lesion associated with or without a palpable mass in the breast. Diagnosis is usually by incisional or excisional biopsy on clinical suspicion. Mammography, ultrasound and FNAC are of little help in the diagnosis of radiation-induced angiosarcoma.

Histologically the tumour consists of a freely anastomosing vascular channels lined by atypical endothelial cells invading the dermis and the subcutaneous fat.

Immunohistochemical markers expressed include the factor V111-related antigen, vimentin, CD31 and CD34 indicating vascular origin of these tumours.

As the majority of the radiation-associated tumours are multifocal, the primary treatment of these tumours is salvage mastectomy or local resection with wide margins. If a patient develops metastatic or recurrent lesions, these may be treated with palliative systemic chemotherapy and locoregional radiotherapy but with limited success.

We propose that the metastatic lesion on the skin graft donor site in this case might be due to Koebner phenomenon. It has

been reported that the site of trauma such as split thickness skin graft donor sites and flap donor sites may be site of metastasis from various malignancies including sarcoma, carcinoma and melanoma[5, 6]. In vivo studies have shown that vascular damage and vascular flow predisposes to metastasis and that an increased number of tumour cells lodge at a site of trauma[7]. It has been postulated that basic fibroblast growth factor (b-FGF), released from traumatized tissue, plays an important role in the development of the Koebner phenomenon [8] and may lead to the development of a tumour [9]. In addition, Yamamoto et al. reported an increase in expression of basic fibroblast growth factor levels in angiosarcoma patients.[10]. We suggest that haematogenous seeding of tumour cells at the site of trauma and b-FGF synthesized in the tumour endothelial cells may play a key role in the growth and progression of angiosarcoma.

In conclusion, this case demonstrates that linear metastatic skin deposits may occur at the skin graft donor site because of Koebner phenomenon. Surgeons treating angiosarcoma patients should be cognizant of this potential complication.

## CORRESPONDENCE TO

Alok Chhabra Department of Surgery Wales College of Medicine Cardiff University Cardiff- CF14 4XN United Kingdom Tel: +44(0)2920744710 Fax: +44(0)2920761623 Email: chhabraa1@cardiff.ac.uk

## References

1. Strobbe LJ, P.H., van Tinteren H, Wijnmaalen A, Rutgers EJ., Angiosarcoma of the breast after conservation therapy for invasive cancer, the incidence and outcome. An unforeseen sequela. *Breast Cancer Res Treat.*, 1998. 47(2): p. 101-9.
2. Zucali R, M.M., Placucci M, Di Palma S, Veronesi U., Soft tissue sarcoma of the breast after conservative surgery and irradiation for early mammary cancer. *Radiother Oncol*, 1994. 30(3): p. 271-3.
3. Cafiero F, G.M., Peressini A, Queirolo P, Bertoglio S, Comandini D, Percivale P, Sertoli MR, Badellino F., Radiation-associated angiosarcoma: diagnostic and therapeutic implications--two case reports and a review of the literature. *Cancer*, 1996. 77(12): p. 2496-502.
4. Otis CN, P.R., McKhann C, Merino MJ, Duray PH., The rapid onset of cutaneous angiosarcoma after radiotherapy for breast carcinoma. *Cancer*, 1986. 57(11): p. 2130-4.
5. Taylor, C.D., et al., Acute development of invasive squamous cell carcinoma in a split-thickness skin graft donor site. *J Burn Care Rehabil*, 1998. 19(5): p. 382-5.
6. McLean, N.R. and J.G. Boorman, Secondary malignant melanoma arising in a contralateral thigh donor site. *Br J Plast Surg*, 1984. 37(3): p. 386-7.
7. Fisher, B., E.R. Fisher, and N. Feduska, Trauma and the localization of tumor cells. *Cancer*, 1967. 20(1): p. 23-30.
8. Sharpe, R.J., et al., Cyclosporine inhibits basic fibroblast

growth factor-driven proliferation of human endothelial cells and keratinocytes. Arch Dermatol, 1989. 125(10): p. 1359-62.

9. French, P.D., J.R. Harris, and D.E. Mercey, The Koebner

phenomenon and AIDS-related Kaposi's sarcoma. Br J Dermatol, 1994. 131(5): p. 746-7.

10. Yamamoto, T., et al., Expression of basic fibroblast growth factor and its receptor in angiosarcoma. J Am Acad Dermatol, 1999. 41(1): p. 127-9.

**Author Information**

**Alok Chhabra, MBBS, MS, MRCS**

Department of Surgery, Wales College of Medicine, Cardiff University

**Amit Goyal, MBBS, MS, FRCS**

Department of Surgery, Wales College of Medicine, Cardiff University

**R .E. Mansel, FRCS**

Department of Surgery, Wales College of Medicine, Cardiff University