

Coronary persistent abscess

P Biswajit, V Sharma, S Shrivastav

Citation

P Biswajit, V Sharma, S Shrivastav. *Coronary persistent abscess*. The Internet Journal of Cardiology. 2008 Volume 7 Number 2.

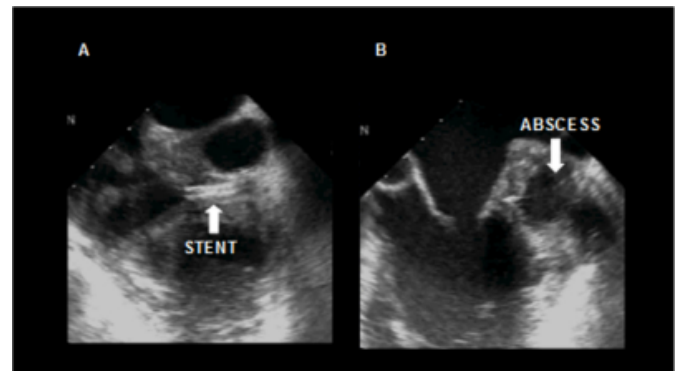
Abstract

Sir:

Coronary stent infection is an uncommon condition with sinister prognosis. We came across a case of coronary stent infection with abscess formation. Staph aureus was identified as the culpable organism in microbiological specimens. The patient was appropriately treated with antibiotics and underwent coronary bypass grafting with debridement of abscess cavity.

Figure 1

Figure . Panel A and B shows TEE images of coronary stent surrounded by abscess cavity.



References

Author Information

Paul Biswajit, D N B Cardiology
Consultant Cardiologist

Vinay Sharma, D M Cardiology
Consultant Cardiologist

Sameer Shrivastav, D M Cardiology
Principal Consultant Cardiologist