

Idiopathic Retroperitoneal Fat Necrosis In A Patient On Long-Term Steroids

P Gupta, M Bhattatiry, N Eshaghi, A Tirkes, M Kumar

Citation

P Gupta, M Bhattatiry, N Eshaghi, A Tirkes, M Kumar. *Idiopathic Retroperitoneal Fat Necrosis In A Patient On Long-Term Steroids*. The Internet Journal of Radiology. 2004 Volume 4 Number 1.

Abstract

It is well known that long-term steroids use alters lipid metabolism that leads to excessive fat deposition. We report a case of idiopathic retroperitoneal fat necrosis with imaging findings on computed tomography (CT) in a patient who has been on long-term steroid use.

INTRODUCTION

Long-term exposure to steroids leads to excessive fat deposition, however spontaneous necrosis of retroperitoneal fat in these patients is generally not suspected and has not been published in the literature. We report on extensive idiopathic retroperitoneal fat necrosis in such one patient with imaging findings on computed tomography (CT).

CASE REPORT

A 57-year-old male patient with Still's disease and diabetes was admitted for surgical repair of incarcerated right inguinal hernia. His medications included Prednisone 20 mg four times a day and Glipizide 5 mg once a day orally for 5 years.

During the hernia repair, greenish material was seen protruding from the deep inguinal ring. Because of this unexpected finding, the retroperitoneum was explored by separate midline infraumbilical approach. Large greenish infiltrating mass was seen in the retroperitoneum. It consisted of large amount of necrotic material. The kidneys, ureter and other major organs were intact. The mass was biopsied and sent to pathology. The hematocrit remained stable before and after surgery. Amylase and lipase levels were within normal limits. Contrast enhanced CT scan of the abdomen and pelvis was performed immediately after the surgery, which revealed extensive infiltrative soft tissue density in the right-sided retroperitoneum. The pancreas and kidneys were normal. The radiological differential diagnosis included retroperitoneal hemorrhage, urine leak, infiltrating liposarcoma and lymphoma. The pathology result was consisted with fat necrosis.

Figure 1

Figure 1: Axial contrast-enhanced computed tomography (CT) image of upper abdomen shows excessive intraabdominal fat deposition.

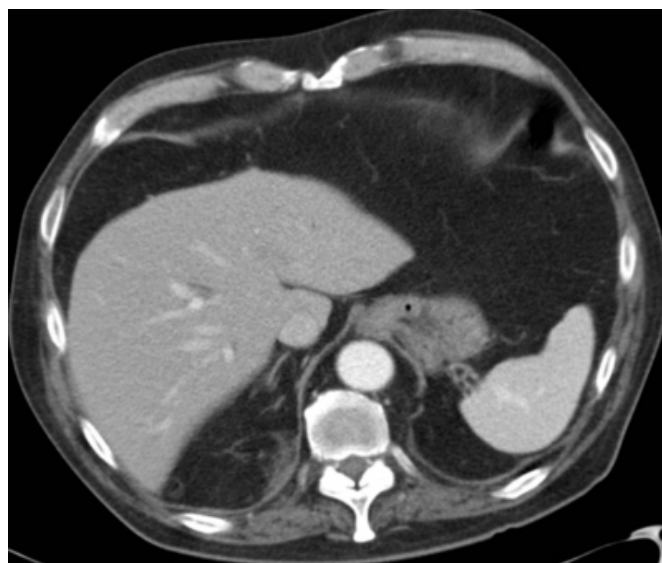


Figure 2

Figure 2: Axial contrast-enhanced CT scan images (A, B, C and D) show infiltrating heterogeneous soft tissue density extending from the right upper retroperitoneum to the pelvis (arrows). Note that the pancreas and kidneys are normal.

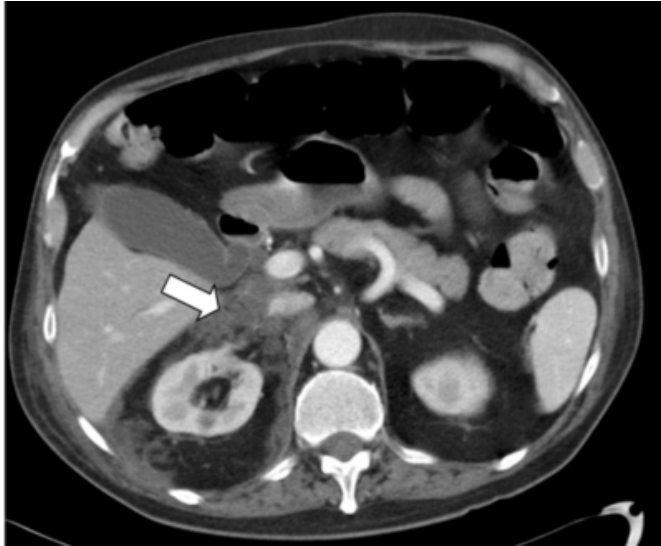

Figure 3

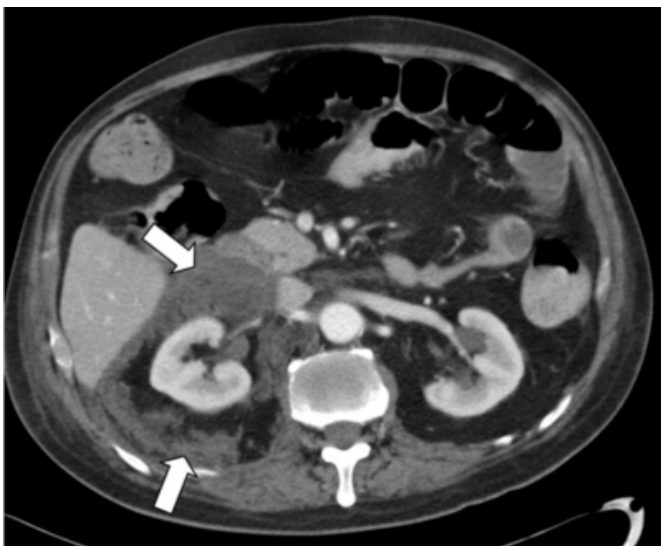

Figure 4

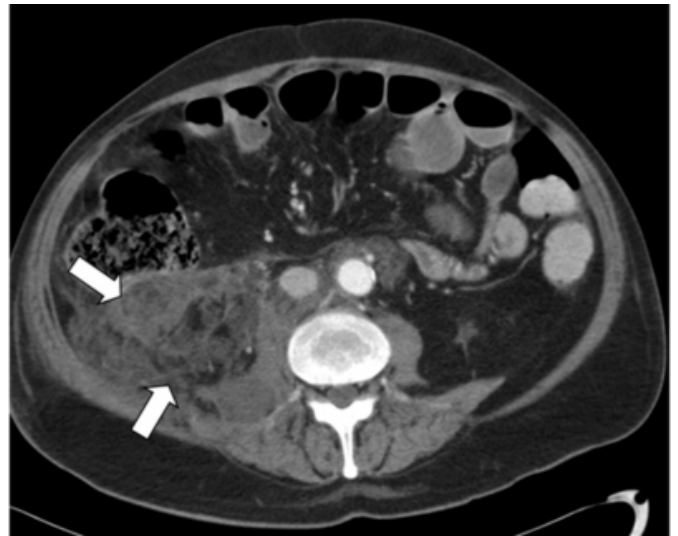
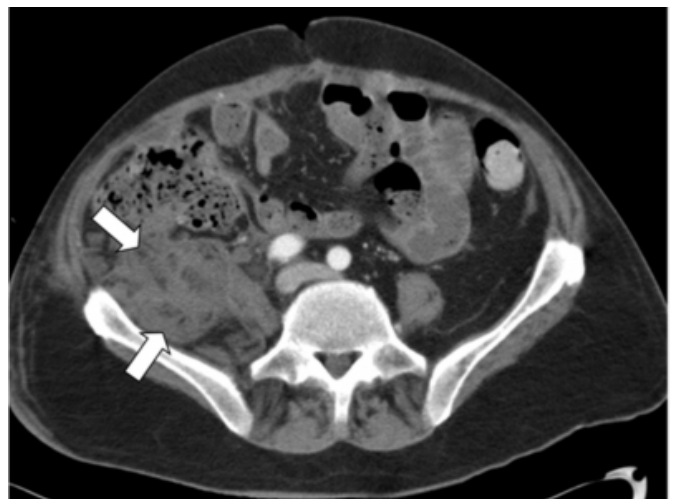
Figure 5



Patient did well with conservative treatment and now symptom free for last nine months.

DISCUSSION

It is well known that long-term exposure to steroids leads to excessive fat deposition¹. However, the mechanism by which steroids alter fat metabolism remains poorly understood². Fat Necrosis is caused either by release of enzymes from pancreas (enzymic fat necrosis) or by trauma to fat, either by a physical blow or by surgery (traumatic fat necrosis). The effect of the enzymes (lipases) is to release free fatty acids, which then can combine with calcium to produce detergents (soapy deposits in the tissues). Histologically, one sees shadowy outlines of fat cells with calcium deposits, foam cells (foamy macrophages), and surrounding inflammatory reaction³.

In our case there was no imaging or laboratory evidence of pancreatitis and there was no history of recent trauma to cause secondary fat necrosis. This patient was on steroid for long-term, however spontaneous necrosis of retroperitoneal fat in patients on long-term steroids is generally not suspected. There are several case reports of encapsulated fat necrosis simulating neoplasm in retroperitoneum, commonly from pancreatitis, however to our knowledge no case reports available describing spontaneous infiltrating nature of retroperitoneal fat necrosis^{4,5,6,7}. Differential diagnosis for infiltrating soft tissue density in retroperitoneal fat includes benign entities such as hemorrhage and urine leak and malignant entities such as liposarcoma and lymphoma⁸. Considering this case we feel that fat necrosis should be included in the differential diagnosis.

References

1. Scale PS, Compton MR. Side-effects of corticosteroid agents. *Med J Aust* 1986; 144: 139-142.
2. Rebuffe-Scrive M. Steroid hormones and distribution of adipose tissue. *Acta Med Scand Suppl* 1988; 723: 143-146.
3. Yeldandi AV, Kaufman DG, Reddy JK. Cell injury and cellular adaptations. In: Damjanov I, Linder J. *Anderson's Pathology*. 10th Edition. Mosby, 1996: 376.
4. Takao H, Yamahira K, Watanabe T. Encapsulated fat necrosis mimicking abdominal liposarcoma: computed tomography findings. *J Comput Assist Tomogr* 2004;28:193-194.
5. Andac N, Baltacioglu F, Cimsit NC, et al. Fat necrosis mimicking liposarcoma in a patient with pelvic lipomatosis. CT findings. *Clin Imaging* 2003;27:109-111.
6. Chen H, Tsang Y, Wu C, et al. Perirenal fat necrosis secondary to hemorrhagic pancreatitis, mimicking retroperitoneal liposarcoma: CT manifestation. *Abdom Imaging* 1996;21:546-548.
7. Haynes JW, Brewer WH, Walsh JW. Focal fat necrosis presenting as a palpable abdominal mass: CT evaluation. *J Comput Assist Tomogr* 1985;9:568-569.
8. Nishino M, Hayakawa K, Minami M, et al. Primary Retroperitoneal Neoplasms: CT and MR Imaging Findings with Anatomic and Pathologic Diagnostic Clues *Radiographics* 2003;23:45-57.

Author Information

Pramod Gupta, M.D.

Radiology Service, Dallas VA Medical Center

Manu Bhattatiry, M.D.

Radiology Service, Dallas VA Medical Center

Nahid Eshaghi, M.D.

Radiology Service, Dallas VA Medical Center

A. Temel Tirkes, M.D.

Radiology Service, Dallas VA Medical Center

Mithilesh Kumar, M.D.

Radiology Service, Dallas VA Medical Center