

# Intravascular Capillary Hemangioma of the Skin

S Repertinger, E Santos, M Chen, D Sarma

## Citation

S Repertinger, E Santos, M Chen, D Sarma. *Intravascular Capillary Hemangioma of the Skin*. The Internet Journal of Dermatology. 2008 Volume 7 Number 1.

## Abstract

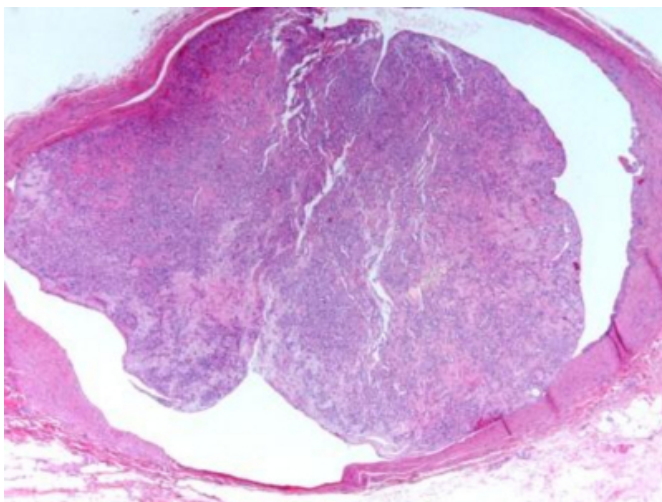
Capillary hemangiomas are very common benign vascular neoplasms which frequently occur in the skin and intraoral mucous membranes. The intravascular variant of this lesion, however, is distinctly uncommon and has been reported rarely in the English literature. Those reported cases describe this tumor as arising in veins in cutaneous and extracutaneous sites. Here we report two cases of intravascular capillary hemangioma arising in the skin.

## CASE 1

An excisional biopsy of a painless subcutaneous nodule that had been present for an unknown period of time in the right forearm of a 44-year-old woman was submitted.

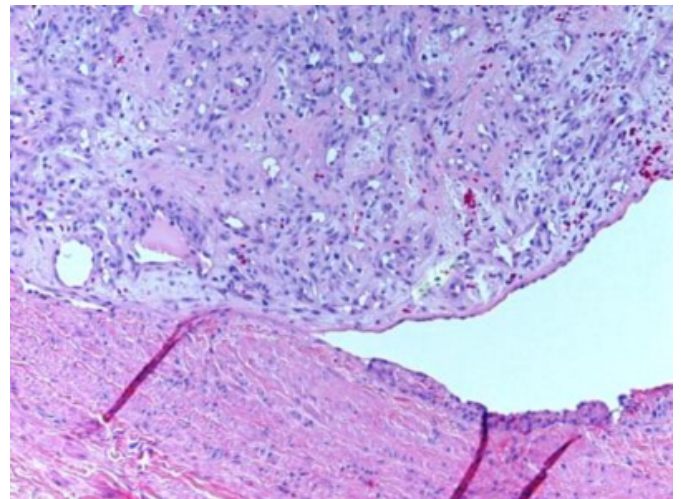
### Figure 1

Figure 1: Low power photomicrograph shows a vaguely lobular vascular tumor within a vein, focally attached to the intima.



### Figure 2

Figure 2: Higher magnification shows the tumor is composed of proliferating capillaries within a fibromyxoid stroma.



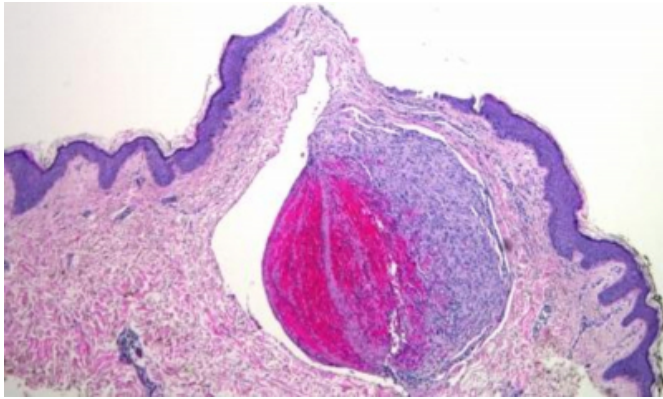
Diagnosis: Intravascular capillary hemangioma.

## CASE 2

An excisional biopsy of a red skin papule that had been present for an unknown period of time was taken from the left neck of a 42-year-old woman. There was no history of trauma or previous surgery in the neck.

### Figure 3

Figure 1: Low power photomicrograph shows a well-circumscribed vascular nodule in the dermis. The tumor is composed of proliferating capillaries. The entire hemangiomatous nodule is located within a thin-walled large vessel, consistent with a vein. The dermis around the vascular nodule is normal and does not show any evidence of previous trauma.



Diagnosis: Intravascular capillary hemangioma.

### COMMENT

Capillary hemangioma (CH) is a benign vascular tumor composed of capillary-sized vessels sometimes arranged in a lobular configuration. The term encompasses the entities, such as pyogenic granuloma and its variants, including acquired tufted angioma and glomeruloid hemangioma. In extravascular locations, the neoplasm occurs most often on the head, neck and gingiva as a red, polypoid, pedunculated nodule. The surface of the lesion easily becomes irritated. Capillary hemangioma can occur at any age and the sexes are affected equally. The intravascular variant is much rarer and has been reported in extracutaneous sites such as the ovary [1] and iliac veins [2]. Cutaneous variants of intravascular CH tend to arise in the upper half of the body [3, 4].

Histologically, cutaneous and extracutaneous forms of capillary hemangioma are similar, showing a well-circumscribed proliferation of capillary-sized vessels with variable lumen formation. The neoplasm is hypercellular and mitotic figures are occasionally seen. Inflammation can be marked. The proliferating capillaries are embedded within a fibrous or fibromyxoid stroma and may be separated by

fibrous septa. The overlying epidermis in the cutaneous form may be atrophic with surface ulceration. In the intravascular variant, CH appears as a single, polypoid mass projecting into the lumen of a vein [3,4,5]; a fibrovascular stalk usually connects the lesion to the intima.

Differential diagnosis includes other vascular lesions, including angiosarcoma, intravascular papillary endothelial hyperplasia, and deep vein thrombosis. Angiosarcoma is usually a distinctly malignant lesion with greater cellular pleomorphism than that seen in CH. In intravascular papillary endothelial hyperplasia, masses of papillary processes covered by a single layer of plump endothelial cells are seen within a vein.

Finally, capillary hemangioma of the skin, both extravascular and intravascular, is associated with trauma in approximately 25% of cases [6]. It should be pointed out, however, that association does not necessarily equate with cause. The skin, in particular, is subject to frequent trauma and capillary hemangiomas do not develop in the great majority of cases in which skin trauma is noted by the patient. Therefore, we believe that intravascular capillary hemangiomas arise from the venous intima independent of injury to the skin.

### CORRESPONDENCE TO

Deba P Sarma, MD

Department of Pathology

Creighton University Medical Center

Omaha, NE 68131, USA

### References

1. McKee, G.T., C.D. Fletcher, and P.H. McKee, Visceral intravascular capillary hemangioma. *Arch Pathol Lab Med*, 1987. 111(4): p. 390-2.
2. Pradhan, S., et al., Intravenous lobular capillary hemangioma originating in the iliac veins: a case report. *J Vasc Surg*, 2008. 47(6): p. 1346-9.
3. Cooper, P.H., H.A. McAllister, and E.B. Helwig, Intravenous pyogenic granuloma. A study of 18 cases. *Am J Surg Pathol*, 1979. 3(3): p. 221-8.
4. Song, M.G., H.J. Kim, and E.S. Lee, Intravenous pyogenic granuloma. *Int J Dermatol*, 2001. 40(1): p. 57-9.
5. Qian, L.H. and Y.Z. Hui, Intravenous pyogenic granuloma: immunohistochemical consideration--a case report. *Vasc Surg*, 2001. 35(4): p. 315-9.
6. Patrice, S.J., K. Wiss, and J.B. Mulliken, Pyogenic granuloma (lobular capillary hemangioma): a clinicopathologic study of 178 cases. *Pediatr Dermatol*, 1991. 8(4): p. 267-76.

**Author Information**

**Susan K. Repertinger, MD**

Creighton University Medical Center

**Eric E. Santos, MD**

St. Margaret's Hospital

**Mingkui Chen, MD**

Creighton University Medical Center

**Deba P. Sarma, MD**

Creighton University Medical Center