

Tuberculosis Cutis Orificialis (TBCO)/Lupus Vulgaris (LV): Simultaneous Occurrence And Review Of The Literature

O Fatusi, O Onayemi, K Adebisi, V Adetiloye, F Owotade, O Oninla

Citation

O Fatusi, O Onayemi, K Adebisi, V Adetiloye, F Owotade, O Oninla. *Tuberculosis Cutis Orificialis (TBCO)/Lupus Vulgaris (LV): Simultaneous Occurrence And Review Of The Literature*. The Internet Journal of Infectious Diseases. 2004 Volume 4 Number 2.

Abstract

Cutaneous tuberculosis may present in diverse forms. We report a case of a 21-year-old Nigerian female with a 2-year history of an extensive ulceration and crusts on the nose and lips with almost complete obliteration of the nasal apertures. The clinical diagnosis of cutaneous tuberculosis was confirmed by histopathological examination of the skin biopsy specimen. She showed a favourable and rapid response to anti-tuberculosis therapy although there was disfiguring scar formation with almost complete obliteration of her nasal apertures. The importance of early recognition, histopathological examination and a remarkable response to anti-tuberculosis drugs in the diagnosis of this rare presentation of cutaneous tuberculosis is highlighted.

INTRODUCTION

Tuberculosis is a world-wide chronic granulomatous infectious disease caused by *Mycobacteria bacilli*. The common modes of entry of the bacillus into the body are by inhalation, or more commonly these days through the ingestion of unpasteurized cow's milk. Tuberculosis has been and continues to be a health problem in many countries as there is a global increase in its incidence. This is attributable to the development of resistance to antituberculosis drugs and the increase in diseases and conditions associated with immunodeficiency have caused a resurgence of pulmonary tuberculosis. With the increasing prevalence of HIV/AIDS in Nigeria for instance, there has been an associated increase in the prevalence of pulmonary tuberculosis. Consequently, atypical presentation such as extrapulmonary or cutaneous forms of the disease may be on the increase as well.

We therefore undertook this review of the literature and case illustration of tuberculosis cutis orificialis and lupus vulgaris in order to stimulate awareness to these clinical presentations of cutaneous tuberculosis, the importance of histological examination and good response to anti-tuberculosis drugs in its clinical diagnosis especially in resource – limited settings.

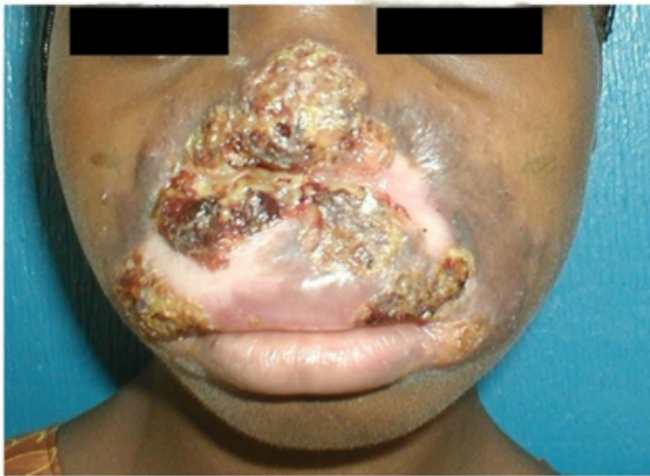
CASE REPORT

This 21-year-old Nigerian female initially presented at the Oral and Maxillofacial Surgery unit before she was referred

to the dermatology clinic of the Obafemi Awolowo University Teaching Hospitals Complex, Ile – Ife, Nigeria. She gave a 2-year history of a gradually progressive ulceration of the nose and lips. She had consulted various healing homes and physicians but her disease got worse. The ulcers were asymptomatic but psychologically hindered her from performing normal duties. She had no cough, no weight loss or fever and no history of diarrhoea. Physical examination revealed a depressed lady with extensive ulceration and crusts on the nose and lips. There was mucopurulent discharge from the ulcer and the skin on the malar area has erythematous papules and plaques that extended to the swollen lips. The nasal apertures were almost completely obliterated (Figure 1). She had no oral lesion and the draining submandibular lymph nodes were enlarged but not tender.

Figure 1

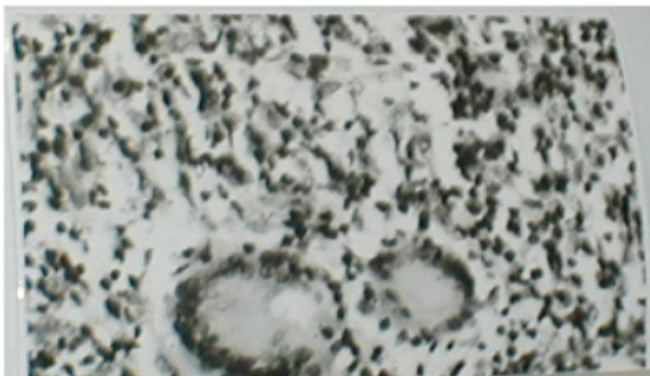
Figure 1: Tuberculosis cutis orificialis (TBCO)/lupus vulgaris (LV): Before treatment.



A clinical diagnosis of cutaneous tuberculosis was made. Laboratory tests, including complete blood cell count and routine chemistry tests were all within normal limits. Histopathological examination of the biopsy specimen showed granulomatous lesions with diffuse lymphocytic infiltrates and multinucleate Langhans' giant cells (Figure 2).

Figure 2

Figure 2: Histology of cutaneous tuberculosis: Note the Langhans' giant cells [H & E X 640].

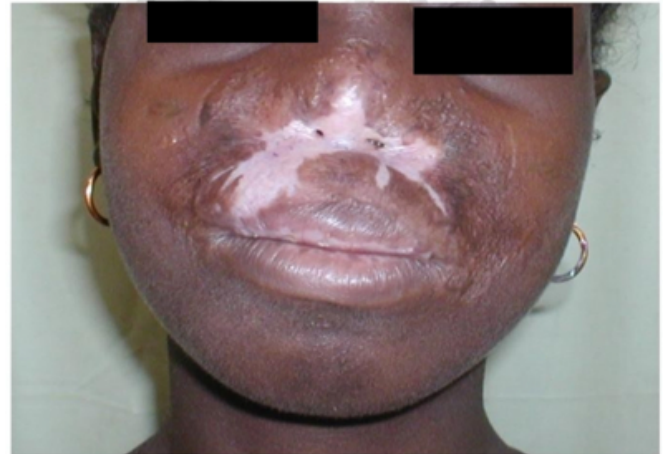

Polymerase chain reaction and culture could not be done on the tissue specimen because of limited resources. She was however commenced on a daily dose of ethambutol 800mg, pyrazinamide 1.5g, isoniazid 300mg and rifampicin 600mg for 2 months and subsequently followed with daily dose of isoniazid 300mg and thiacetazole 150mg for 6 months.² She demonstrated favorable and rapid response to the anti-tuberculosis therapy within 3 months (Figure 3) with a residual disfiguring scar formation at the end of therapy. She is presently awaiting plastic surgery to correct the stenosed

nasal apertures.

Figure 3

Figure 3: Tuberculosis cutis orificialis (TBCO)/lupus vulgaris (LV): After treatment.



DISCUSSION

Lupus vulgaris (LV) is the most common cutaneous manifestation of tuberculosis in industrialized countries, but nevertheless it remains rare. It may be suggestive of underlying pulmonary tuberculosis.³ Its incidence has steadily decreased during recent decades,⁴ but devaluation of socioeconomic level in any country can bring about its resurgence.⁵ The disease comes about as an infection of the skin in individuals with a moderate to a high degree of tuberculin sensitivity. The source of skin infection can be exogenous or endogenous in origin. Its clinical presentation and behavior depend on the patient's immunity and duration of the disease.⁶ Clinically, the lesions of LV are usually on the exposed parts, especially the face. They are asymptomatic and characterized by groups of firm papules and nodules which when blanched by diascopic pressure, have the characteristic "apple jelly" color.⁷ Early diagnosis and appropriate management may cure the disease with no life-threatening sequelae.⁶

Depending on the extent of the facial involvement in lupus vulgaris, the presentation may be extensive to involve the orifices and the patient may also have features indistinguishable from tuberculosis cutis orificialis (TBCO). This type of cutaneous tuberculosis though rare, occurs at mucocutaneous borders in patients who are usually young adults, having advanced visceral tuberculosis. It results from autoinoculation. There are nodules that rapidly breakdown to form painful, shallow ulcers.⁸ The presentation in our patient can justifiably be classified as TBCO and LV occurring

simultaneously. .

TBCO or LV remains either undiagnosed or misdiagnosed and inappropriately treated due to physicians' unawareness. For instance, our patient had developed the ulcerated lesion since 2 years and had consulted healing homes and medical practitioners with no rebate in the course of her disease. This delay could have been averted if there was a high index of clinical suspicion especially with her unexplained and progressive ulcerated and nodular facial lesions.

In resource-limited settings, clinical examination and histological examination of skin biopsy specimen could assist in the proper diagnosis of cutaneous tuberculosis. The dramatic response to anti-tubercular therapy as observed in our patient is another diagnostic support tool. Although the patient had a disfiguring scar formation, her response to appropriate therapy had a tremendous psychological impact on her as clinically evidenced by her physical and mental state.

CORRESPONDENCE TO

Olaniyi Onayemi FMCP Department of Dermatology &

Venereology, Faculty of Clinical Sciences, College of Health Sciences, Obafemi Awolowo University, Ile-Ife, Nigeria. E-mail: onayemi2002@yahoo.com

References

1. Kivanc-Altunay I, Baysal Z, Ekmekci TR, Koslu A. Incidence of cutaneous tuberculosis in patients with organ tuberculosis. *Int J Dermatol.* 2003; 42:197 - 200.
2. Erhabor GE, Aghanwa HS, Yusuf M, et al. Factors influencing compliance of patients with tuberculosis on directly observed therapy in Ile - Ife, Nigeria. *EAMJ.* 2000 ; 77: 1 - 5.
3. Barbareschi M, Denti F, Bottelli S, Greppi F. Pulmonary tuberculosis revealed by lupus vulgaris in an immunocompetent patient. *Eur J Dermatol.* 1999; 9: 43 - 44.
4. Abraham Z, Feuerman EJ. [Lupus vulgaris diagnosed after 71 years. *Harefuah.* 1991; 120: 720-722.
5. Makhoul E, Abadjian G, Bendaly-Halaby E, et al. Tuberculous lupus. Apropos of a case of tuberculous lupus tumidus: *J Med Liban.* 1997; 45: 43 - 45.
6. El-Ghatit AM, El-Deriny SM, Mahmoud AA, Ashi AS. Presumed periorbital lupus vulgaris with ocular extension. *Ophthalmology.* 1999; 106:1990-1993.
7. Arnold HL, Odom RB, James WD. Mycobacterial diseases. In: *Andrews' Diseases of the Skin.* Philadelphia; 1990, W.B. Saunders Co., pp. 375-388.
8. Fitzpatrick TB, Eisen AZ, Wolff K, et al. *Dermatology in General Medicine.* 3rd ed. New York; McGraw-Hill, 1987; 2152-2179.

Author Information

Olawunmi A. Fatusi, FMCDS

Department of Oral & Maxillofacial Surgery, Obafemi Awolowo University Teaching Hospitals Complex

Olaniyi Onayemi, FMCP

Department of Dermatology & Venereology, Obafemi Awolowo University Teaching Hospitals Complex

Kehinde E. Adebisi, WACS

Department of Oral & Maxillofacial Surgery, Obafemi Awolowo University Teaching Hospitals Complex

Victor A. Adetiloye, FMCR

Department of Radiology, Obafemi Awolowo University Teaching Hospitals Complex

Foluso J. Owotade, FWACS

Department of Oral & Maxillofacial Surgery, Obafemi Awolowo University Teaching Hospitals Complex

Olumayowa A. Oninla, MB, ChB

Department of Dermatology & Venereology, Obafemi Awolowo University Teaching Hospitals Complex