

Gangrenous Sigmoid Volvulus with Eventration of the Diaphragm

M Mulla, V Srivastava, L Walton, F Jackaman

Citation

M Mulla, V Srivastava, L Walton, F Jackaman. *Gangrenous Sigmoid Volvulus with Eventration of the Diaphragm*. The Internet Journal of Surgery. 2006 Volume 13 Number 1.

Abstract

A 46-year-old lady with learning disability was admitted with abdominal distension, tachypnoea and sepsis. Radiological investigations revealed an eventration of the left hemi-diaphragm and apparent dextrocardia caused by sigmoid volvulus. At laparotomy, a gangrenous sigmoid colon was reduced into the abdominal cavity from the thorax and the thin and membranous diaphragm (with no obvious defect) was plicated. The gangrenous sigmoid colon was resected and a Hartmann's procedure performed. With intraoperative intubation and positive pressure ventilation the left lung expanded and the diaphragm returned to an "anatomical" position. This was confirmed with further plain radiography. On return to the general ward a repeat chest X-ray showed partial collapse of the right lung base with possible right-sided eventration of the diaphragm; however, clinically the patient showed no evidence of respiratory compromise, made a full recovery and was discharged several days later with no complications.

CASE REPORT

A 46-year-old lady with learning disability was admitted with abdominal distension, tachypnoea and sepsis. Examination suggested generalized peritonitis. Serological investigations confirmed leucocytosis, acute renal failure and hypoxia with a metabolic acidosis. Radiological investigations revealed an eventration of the left hemi-diaphragm and apparent dextrocardia as shown in Figure 1 caused by sigmoid volvulus (Fig.2).

Figure 1

Figure 1: Chest X-Ray showing Sigmoid Colon within the left chest cavity, displaced cardia with compression of the left lung.

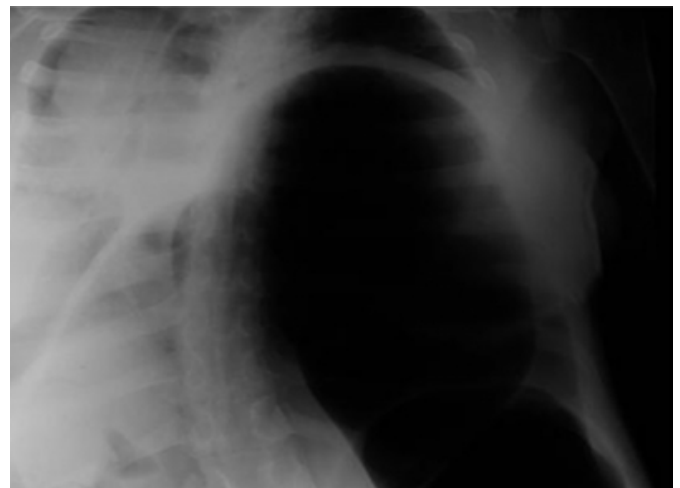
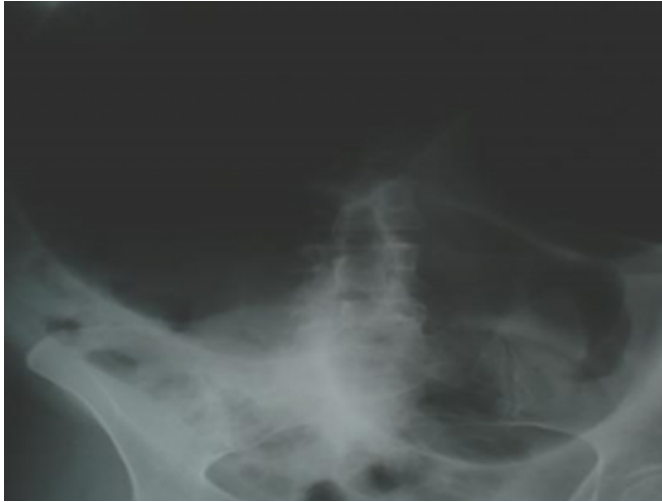

Figure 2

Figure 2: Plain abdominal X-ray confirms sigmoid volvulus



Initial sigmoid decompression with rigid sigmoidoscopy and flatus tube insertion alleviated the abdominal distension and improved ventilation but the patient remained unwell with a rising lactate. Further radiological imaging confirmed inadequate expansion of the right lung with persisting eventration. At laparotomy a gangrenous sigmoid colon was reduced into the abdominal cavity from the thorax and the thin and membranous diaphragm (with no obvious defect) was plicated.

The gangrenous sigmoid colon was resected and a Hartmann's procedure performed. With intraoperative intubation and positive pressure ventilation the left lung expanded and the diaphragm returned to an "anatomical" position. This was confirmed with further plain radiography.

On return to the general ward, a repeat chest X-ray showed partial collapse of the right lung base with possible right-sided eventration of the diaphragm; however, clinically the patient showed no evidence of respiratory compromise, made a full recovery and was discharged several days later with no complications. At three month follow-up the patient remained well and a repeat plain chest X-ray was unremarkable.

DISCUSSION

The combination of learning disability with sigmoid volvulus although uncommon is well described (_{1,2}) and fortunately rarer still must be the combination of learning disability with dextrocardia and diaphragmatic eventration

presenting with a gangrenous sigmoid volvulus. Since we are not aware of this lady's pre-morbid condition it is debatable as to whether the diaphragmatic eventration was congenital or acquired (_{4,5}) and it is reasonable to speculate that chronic constipation with long standing high pressures exerted by the distended sigmoid colon on the diaphragm may have caused this. It has been stipulated that the additional space made available by the aberrant diaphragm may allow gastric or sigmoid colonic volvuli to occur more easily (₃).

A similar case was described by Tsunoda et al. (₃); however, no comment was made regarding intraoperative management of the diaphragmatic eventration. Indeed, plication of the diaphragm (in the presence of a gastric rather than sigmoid volvulus) is well described but can require thoracotomy (_{4,6}).

In our case the diaphragm was plicated as the sigmoid volvulus and eventration was associated with considerable respiratory compromise despite sigmoid decompression.

This is indeed a rare occurrence and to the best of our knowledge its management has not been described in literature.

CORRESPONDENCE TO

Mr.MG Mulla Department of Surgery Derby City General Hospital Uttoxeter Road Derby. DE22 3NE. Email: m.mulla@nottingham.ac.uk Tel: +44 (1332) 724702 Fax: +44 (1332) 724697

References

1. Bhatnagar BN, Sharma CL, Gautam A, Kakar A, Reddy DC. Gangrenous sigmoid volvulus: a clinical study of 76 patients. *Int J Colorectal Diseases*. 2003 Sep;(epub)
2. Connolly S, Brannigan AE, Heffernan E, Hyland JM. Sigmoid Volvulus: A 10-year audit. *Ir J Med Sci*. 2002 Oct-Dec;171(4):216-7
3. Tsunoda A, Shibusawa M, Koike T. Volvulus of the sigmoid colon associated with eventration of the diaphragm. *Am J Gastroenterol*. 1992 Nov;87(11):1682-3
4. Raos M, Batinica S. Diaphragmatic Eventration. *Lijec Vjesn*. 2003 Jan-Feb;125(1-2):13-5
5. Donzeau-Gouge GP, Personne C, Lechien J, Colchen A, Leroy M, Seigneur F, Hertzog P, Toty L. Diaphragmatic eventration in adults.Apropos of 20 cases. *Sem Hop*. 1982 Oct 7;58(36):2065-8
6. Tanner NC. Chronic and recurrent volvulus of the stomach with late results of "colonic displacement". *Am J Surg* 1968;115:505-15

Author Information

M.G. Mulla

Department of General Surgery, Derby City General Hospital

V. Srivastava

Department of General Surgery, Derby City General Hospital

Laura Walton

Department of General Surgery, Derby City General Hospital

F.R. Jackaman

King's Mill Hospital