Combination Therapy Antimalarial Drugs Mefloquine And Artequin Induce Reactive Astrocytes Formation In The Hippocampus Of Rats

T Ekanem, E Salami, M Ekong, M Eluwa, A Akpantah

Citation

T Ekanem, E Salami, M Ekong, M Eluwa, A Akpantah. *Combination Therapy Antimalarial Drugs Mefloquine And Artequin Induce Reactive Astrocytes Formation In The Hippocampus Of Rats*. The Internet Journal of Health. 2008 Volume 9 Number 2.

Abstract

The normal adult vertebrate nervous system is a relative quiescent tissue in terms of cell proliferation. However, astrocytes in many region of the central nervous system (CNS) like hippocampus retain the capacity to undergo cell division. Understanding the growth of this glial cell is a key to repairing neurons in response to insult. We studied reaction of astrocytes in the hippocampus after a three day administration of antimalarial agent mefloquine and Artequin to forty-two Wistar rats. The rats received 1.07mg/kg, 2.14mg/kg, 4.28mg/kg of mefloquine and 0.86/1.07mg/kg, 171/2.14mg/kg and 3.24/4.28mg/kg of Artequin. Hippocampal sections of treated rats stained by Hortega's lithium carbonate method revealed astrocytes stained black as in the control, but hippocampal sections of rats treated with 2.14mg/kg, 4.28mg/kg of mefloquine, and 1.71/2.14mg/kg and 3.24/4.28mg/kg of Artequin showed large, numerous and some few paired astrocytes. We conclude that mefloquine and Artequin induced dose dependant reactive astrocytes formation in the hippocampus. This may impair uptake of neurotransmitters and alter neuronal environment, thus altering hippocampal functions like memory and learning.Key words: Artequin, Hippocampus, Mefloquine, Reactive Astrocytes.

The research was carried out in the Histology laboratory of the Department of Human Anatomy, Faculty of Basic Medical Sciences, University of Calabar, Calabar, Nigeria

INTRODUCTION

In most parts of Nigeria including Calabar, malaria has become a familiar sickness. Health centres are not often patronized rather home/self treatment is the first-line of treatment as antimalarial drugs are purchased at the open markets like other commodities. In addition, sales persons have little or no formal education on the various antimalarial therapies in use, knowledge of side effects of the drug or contradictions and appropriate dosages. The risk of toxicity this way is high mainly from over dose and misuse; this indiscriminate misuse of drug could endanger the life of the vast population [1] .

Antimalarial agents are drugs used in the treatment of malaria infections caused by the Plasmodium species; falciparum, vivax, ovale and malariae. Some of this antimalarial monotherapies include; chloroquine, amodiaquine, mefloquine and artesunate. Mefloquine is a 4-quinoline methanol derivative that has been the drug of choice in most regions of the world. Like chloroquine, it is a blood schizonticide, though has long acting half life than any known antimalarial [1] . Over the years, there has been global decline in the use of mefloquine regime due to its documented neurological adverse effects such as neuropsychiatric disorders, forgetfulness and seizure [2] . In 1980 mefloquine was withdrawn from the pharmaceutical market [1] .

The recent trend of malaria therapy with the artemisinin based combination therapy (ACT) such as artemether or artesunate combined with a more slowly eliminated drug has again re-introduced mefloquine combined with artesunate known as Artequin [3] for the treatment of resistant malaria. Though, artemisinin derivatives have little or no neurological adverse effects in humans [4] , there have been poor documentation on their morphological activity and that of Artequin as well [1,5] . However, it has been shown that antimalarial have caused damage to certain organs of the body thus influencing their activity [1] . Neurons in the central nervous system (CNS) are particularly susceptible owing to the wide range of neurological events documented on

antimalarial drugs which varies depending on the part of the CNS affected, with dizziness being the most frequently reported [1].

Astrocytes make up half of the cell population in the CNS apart from neurons, they are known to provide neurons with rich nutritional environment for survival. Understanding this glial activity is a clue to neuronal responses. Mefloquine presence in Artequin may indicate a possibility of danger because of the adverse events documented against mefloquine on the hippocampal functions like memory, learning and emotion [6].

Since self medication is especially common in developing countries. In Africa, this has resulted in indiscriminate use of drug and sometimes at dosage above the therapeutic dose. It becomes important to checkmate drug administration for human safety; this study determines the effect of these drugs on astrocytes in the hippocampus.

MATERIAL AND METHODS

ANIMAL CARE

Forty-two Wistar rats weighing 200g were purchased from the animal house of the Department of Anatomy, College of Medical Sciences, University of Calabar, Nigeria. The animals were maintained at temperatures of 30-36 ^{o} C and were fed with growers mash obtained from Pfizer Nigeria Limited, twice daily and allowed water ad-libitum. They were cared for in compliance with applicable guidelines for animal research study. The approval of animal study and experiment was obtained from the Ethics Committee of the University of Calabar, Calabar, Nigeria.

DRUG ADMINISTRATION

The mefloquine and Artequin used in this research study produced by Mepha Pharmaceutical Limited, Asch-basal, Switzerland was purchased from the University of Calabar Pharmacy Shop, Calabar, Nigeria. The mefloquine and Artequin were dissolved in 100ml distilled water separately. The drug suspensions was administered to animals based on body weight, the therapeutic dosages for the rats were determined against the therapeutic doses for humans, which is 750mg/kg of mefloquine and 600/750mg/kg of Artequin. These suspensions were administered orally with the aid of orogastric tubes. The rats were divided into groups as shown in Table 1 below.

The animals in all the groups were sacrificed on day four. The skulls was dissected and the whole brains were removed and preserved in neutral formal saline for seven days, thereafter the hippocampus were dissected by first removing the cerebellum and brainstem, then scrapping the inferior aspects of the dorsum of cerebrum on either side revealing the entire extent of the hippocampus. They were removed, processed and stained using the Hortega's lithium carbonate method for reactive astrocytes. Photomicrographs were taken using the research microscope.

Table 1: Administration Schedule

Figure 1

Groups (n=6)	Drugs	Weight (g)	Dosage/day
C	Water	200	
A1	MQ	"	1.07mg/kg
A2	MQ	"	2.14mg/kg
A3	MQ	"	4.28mg/kg
B1	Artequin	"	0.86/1.07/mg/kg
B2	Artequin	"	1.71/2.14mg/kg
B3	Artequin	"	3.42/4.28mg/kg

MQ - Mefloquine

RESULTS

In control sections, there were distinct astrocytes stained black. They were few in number and unpaired (Plate 1). The sections of the hippocampus of rats treated with 1.07mg/kg of mefloquine showed many astrocytes that were unpaired compared to the control (Plate 2). The sections of the hippocampus of rats treated with 2.14mg/kg of mefloquine revealed many unpaired astrocytes that were densely stained with few paired ones (Plate 3). Sections from the hippocampus of rats treated with 4.28mg/kg of mefloquine showed many paired astrocytes deeply stained (Plate 4).

The sections from the hippocampus of rats treated with 0.86/1.07mg/kg of Artequin revealed astrocytes that were numerous and unpaired (Plate 5). Sections of hippocampus of rats treated with 1.71/2.14mg/kg of Artequin revealed many paired astrocytes while the group that received 3.42/4.28mg/kg of Artequin showed highly numerous and few paired astrocytes (Plates 6-8).

PHOTOMICROGRAPHS

Figure 2

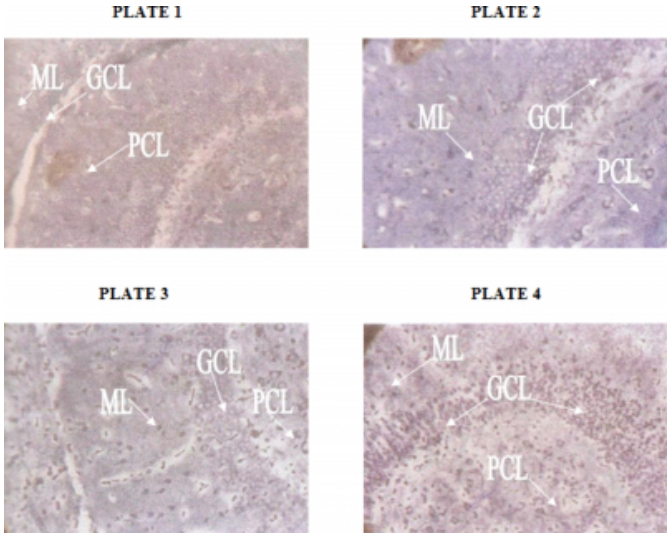

Photomicrographs of hippocampal section of rats given mefloquine and their control

Plate 1: Hippocampal section of control rats given distilled water showing normal astrocytes (single black)

Plate 2: Hippocampal section of rat treated with 1.07mg/kg of mefloquine showing astrocytes (single black)

Plate 3: Hippocampal section of rat treated with 2.14mg/kg of mefloquine showing paired astrocytes (black).

Plate 4: Hippocampal section of rat treated with 4.28mg/kg of mefloquine showing paired astrocytes (black).

Hortega's lithium carbonate method. Mag. x400. ML-Molecular layer; GCL-Granule cell layer; PCL-Pyramidal cell layer; Astrocytes stained black

Figure 3

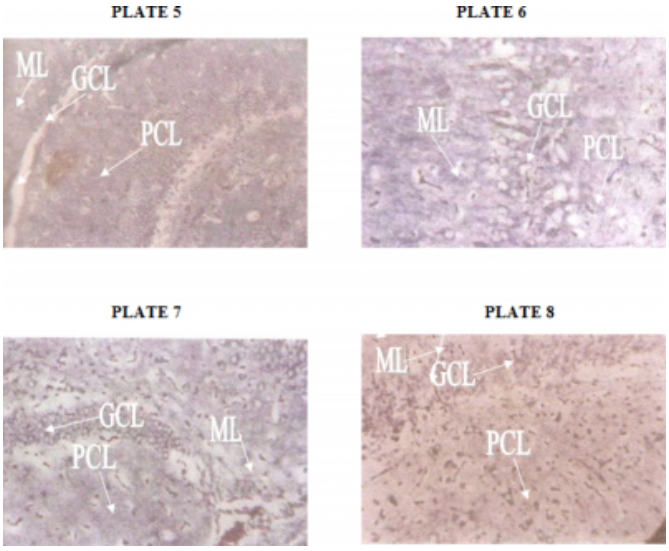

Photomicrographs of hippocampus of rats treated with Artequin and their control

Plate 5: Hippocampal section of control rats given distilled water showing normal astrocytes (single black)

Plate 6: Hippocampal section of rats treated with 0.86/1.07mg/kg of Artequin

Plate 7: Hippocampal section of rats treated with 1.71/2.14mg/kg of Artequin

Plate 8: Hippocampal section of rats treated with 3.42/4.28mg/kg of Artequin.

Hortega's lithium carbonate method. Mag. x400. ML-Molecular layer; GCL-Granule cell layer; PCL-Pyramidal cell layer; Astrocytes stained black

DISCUSSION

Astrocytes are star shaped glial cells in the CNS. Two forms of astrocytes exist in the mammalian brain, these are the fibrous astrocytes related to the white matter having small cell bodies with long processes and protoplasmic astrocytes that have more frequent processes which are shorter and thicker than the processes seen in the fibrous astrocytes. These astrocytes contain multitude of small, round, dark glycogen granules that make astrocytes appear dark when stained [7] . They provide metabolic support for neurons in the CNS and synaptic means of communication within the brain [8] .

They regulate ionic concentration, for tight junctions, blood-

brain barrier and serve as intermediary stations for converging nutrient, gases and removal of waste products between neuron [9] . Astrocytes exert strong influences on neurons during synaptic transmission through modulation of their volume, composition and concentration of neurotransmitter, glutamate and ATP receptor [8] .

Peter et al [8] documented that astrocytes are neuroprotective, involved in healing and recovering of neurons in various nervous system pathology. In this present study the hippocampus of rats treated with 1.07mg/kg, 2.14mg/kg and 4.28mg/kg of MQ showed increased number and size of astrocytes. Similar pattern of astrocytes morphology were seen in the groups treated with 0.86/1.07mg/kg, 1.71/2.14mg/kg and3.42/4.28mg/kg of Artequin per body weight when compared to the control indicating hyperplasia and hypertrophy. Peter et al [9] showed that in CNS injury astrocytes acts as neuroprotective sheath, they increase in number, fill injury zone, forming glial scar to fill defects left by loss of specialized nervous tissues. They help in healing and recovery of neurons such are called reactive astrocytes. Abbas and Nelson [10] reported that the presence of reactive astrocytes indicates early sign of cell loss and serve as indicator of pathologic process. Thus the activity of mefloquine and Artequin on astrocytes might suggest possible stages of neuronal deranged activity or loss, which could also explain the neurological effects of mefloquine therapy on the hippocampus such as forgetfulness and seizure.

In response to glutamate and adenosine receptor stimulation astrocytes could form swelling leading to increased size of the astrocytes [8] . In this study findings revealed large and paired astrocytes in rats treated with 2.14mg/kg, 4.28mg/kg of MQ and 3.24/4.28mg/kg of Artequin per body weight when compared to the control indicating hyperplasia and hypertrophy. Peter et al [8] showed that in CNS injury zone, forming glial scar to fill defects left by loss of specialized nervous tissues. They help in healing and recovery of neurons such astrocytes are called reactive astrocytes. Abbas and Nelson [10] reported that the presence of reactive astrocytes indicates early sign of cell loss and serve as indicator of pathologic process. Thus the activity of mefloquine and Artequin on astrocytes might suggest possible early sign of cell loss and serve as indicator of pathologic process. Thus the activity of mefloquine and Artequin on astrocytes might suggest possible early stages of neuronal deranged activity or loss, which could also, explain the neurological effects of mefloquine therapy on the hippocampus such as forgetfulness and seizure.

In respond to glutamate and adenosine receptor stimulation astrocytes could form swellings leading to increased size of the astrocytes [8] . In this study findings revealed large and paired astrocytes in the rats treated with 2.14m/kg, 4.28mg/kg of MQ and 1.71/2.214mg/kg and 3.24/4.28mg/kg of Artequin. Growing evidence indicate that trophic action of extracellular nucleotides are involved in CNS development, injury and repairs for example ATP released upon CNS injury contributed to the formation of reactive astrocytes [11] . Fibroblast growth factor (FGF) is also increased after injury can stimulate astrocytes proliferation [10] . This showed that proliferation is one of the features of reactive astrogliosis particularly in traumatic injury. They also confirmed that hypertrophy could be due to accumulation of intercellular substances. These changes in normal astrocytes morphology and population could impact new functional state which might impair astrocytes activity like uptake and metabolism of monoamine and amino acid neurotransmitters.

Hippocampal hypoxia have also caused astrocytes to become reactive and hypertrophied as seen in most mental disorders and spatial loss of memory during seizure, it is also implicated in epileptogenesis [12] . In addition apart from injury, cell death, mechanical alteration of tissue structure and components also stimulated cell proliferation while certain inhibitory or excitatory signal from the microenvironment have been indicated [8] .

CONCLUSION

Our findings showed a dose dependent pattern of alteration and pairing of astrocytes observed in rats treated with increased dosages of mefloquine and Artequin (2.14mg/kg, 4.28mg/kg of MQ and 1.71/2.214mg/kg and 3.24/4.28mg/kg of Artequin). Altered neuronal environment may be implicated in the effects of these drugs on the hippocampus whose main functions include memory, learning, spatial navigation and emotion. The increase population of reactive astrocytes formation is meant to protect neurons by providing nutritionally rich environment for neuronal survival following possible adverse effects produced by these drugs. The effects of these drugs on astrocytes appeared to be dose dependent and similar. We therefore conclude and recommend that Artequin which is a new artemisinin combination therapy (ACT) drug may affect the function of the hippocampus and should be administered

safely on medical prescription by a physician.

ACKNOWLEDGMENT

We give an especially high acknowledgment to all staff of the Histology section of the Department of Human Anatomy where this study was carried out for their valuable assistance.

References

1. World Health Organization. The use of antimalarial drugs; report of a World Health Organization Informal Consultation. Geneva. 2000: 43-100.
2. Dow G, Auman AB, Cardha D, Cabezas MFDU. Gomez-tobo R, Park M, Canard T. Mefloquine induced dose-related neurological effects in a rat model. Url: http;//aac.asm.org/egi/cont./full/50/3/1045. Assessed on January 13, 2006.
3. Mepha Pharmaceuticals Limited (2004). 40 Broadwaters road, Welwyn Garden City, Switzerland
4. Gordi T, Lepist EI. Artemisinin derivatives: toxic to laboratory animals, safe in humans? Toxicol Lett 2004; 147(2): 99-107.
5. Wilmer M., Maria H, Carlas C, Edwardo F, Cesor C, Ruben N, Trenton KR. Efficacy of mefloquine and mefloquine plus artesunate combination therapy for the treatment of uncomplicated Plasmodium falciparum malaria in the Amazon basin of Peru. Am J of Trop Med Hyg (2003); 68 (1): 107-110.
6. Osim EE. The limbic system. Textbook of Neurophysiology. 2nd ed. Calabar: El-Sapphire Ltd. 2003.
7. Singh I. Textbook of Human Neuroanatomy. 6th ed. Delhi: Jaypee Brothers. 2002.
8. Peter RL, Eva S, Andreas R, Glenn IH, Herbert B. Glial cells: Their roles in behavior. 1st ed. Cambridge University Press. 1998: 1-20, 315-332.
9. George JS, Bernard WA, Wayne RA, Stephen KF, Michael DU. Basic neurochemistry: molecular, cellular and medical aspects, (6th ed.). Philadelphia: Lippincott Williams and Wilkins. 1998.
10. Abbas A, Nelson FK. Robin and Cotran Pathologic Basis of Diseases. 7th ed. New Delhi: Elsevier. 2004.
11. Erickson PS, Pertilievva E, BjorkErickson T, Alborn AM, Nordberg C, Peterson DC, Gage FH. Neurogenesis in the adult human hippocampus. Nature Medicine. 1998; 4(11): 1313-1317.
12. Liu ZI, Xq RX, Yany ZJ, Bai YW, Luo CY, DU MX, Zou YX, Jiuny XY. Response of neurons and astrocytes in rats hippocampus to kainite acid induced seizure. Di Yi Da Xue Bua 2003; 23 (11): 1151-1155.

Author Information

Theresa B. Ekanem, PhD
Department of Human Anatomy, Faculty of Basic Medical Sciences University of Calabar Calabar, Nigeria

Elizabeth Salami, MSc
Department of Human Anatomy, Faculty of Basic Medical Sciences University of Calabar Calabar, Nigeria

Moses B. Ekong, Msc
Department of Human Anatomy, Faculty of Basic Medical Sciences University of Calabar Calabar, Nigeria

Mokutima A. Eluwa, MSc
Department of Human Anatomy, Faculty of Basic Medical Sciences University of Calabar Calabar, Nigeria

Amabe O. Akpantah, PhD
Department of Human Anatomy, Faculty of Basic Medical Sciences University of Calabar Calabar, Nigeria