

# Non-Anastomotic Aneurysm Of The Dacron® Graft

S Nachimuthu, M Abdelhamid, K Grant, R Awad

## Citation

S Nachimuthu, M Abdelhamid, K Grant, R Awad. *Non-Anastomotic Aneurysm Of The Dacron® Graft*. The Internet Journal of Surgery. 2006 Volume 13 Number 2.

## Abstract

Non-anastomotic aneurysms of the prosthetic grafts used for infrainguinal arterial reconstruction are very unusual. Very few cases have been reported in the literature. A 68-year-old gentleman presented to us with a non-anastomotic aneurysm of his Dacron® graft which was used to reconstruct his femoropopliteal segment 16 years ago. His Dacron® graft aneurysm was repaired with complete excision and replacement with another Dacron® graft. The probable causes of graft failure are manifold. All these patients require meticulous follow-up, at least annually, to identify graft failure at an early stage. Diagnosis of graft failure can be suspected on clinical grounds and should be confirmed by imaging. Patients presenting with this problem require early surgical intervention to replace the failed graft to prevent catastrophic complications like rupture.

## INTRODUCTION

Non-anastomotic aneurysms of the prosthetic grafts used for infrainguinal arterial reconstruction are very unusual. Very few cases have been reported in the literature. This complication can occur even many years after surgery. We report a case of late non-anastomotic aneurysm of a Polyethylene terephthalate graft (Dacron® graft) used in femoropopliteal reconstruction 16 years ago.

## CASE REPORT

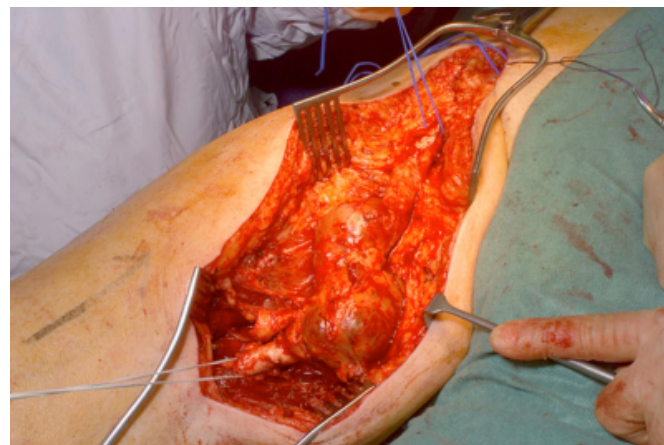
A 68-year-old Caucasian gentleman presented to our vascular clinic with a sausage-shaped pulsatile swelling in his right thigh. Of note, he had undergone elective left renal artery reconstruction for arterial stenosis and secondary hypertension in 1990 elsewhere. In the postoperative period he underwent emergency splenectomy for iatrogenic injury, and subsequently developed acute right lower limb ischaemia due to embolic disease. Femoral embolectomy was not successful at the time, and hence a right femoropopliteal bypass was performed using a Dacron® graft. At presentation, it was also noted that he had controlled chronic renal failure and hypertension.

Clinically, he was found to have a pulsatile mass in his right thigh, consistent with aneurysmal dilatation of the graft. This was evaluated by CT angiography, which confirmed non-anastomotic aneurysm of the mid-portion of the graft. Incidentally, he was also found to have a 6 cm infrarenal Abdominal Aortic Aneurysm (AAA). Following careful multidisciplinary assessment, he underwent an uneventful

elective open repair of AAA. In the routine follow-up, the graft aneurysm has dramatically increased in size and hence he underwent urgent exploration of his thigh which revealed a 10 x 4cm dumb-bell shaped non-anastomotic aneurysm of the mid portion of the graft.

## Figure 1

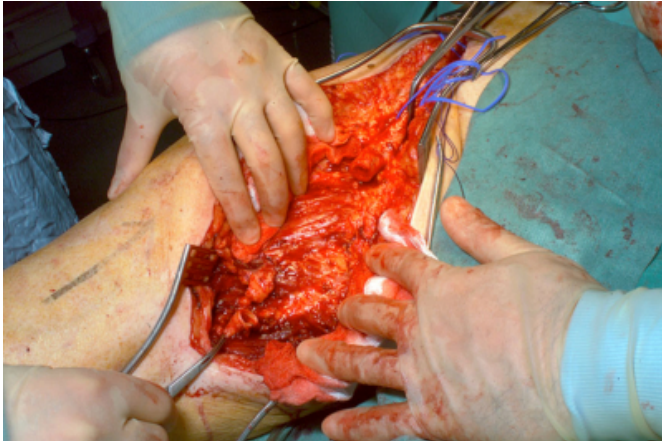
Figure 1: Dumb-bell shaped non-anastomotic aneurysm of the mid portion of the graft



Complete resection of the graft was performed and it was replaced with a 10mm woven Dacron® graft.

**Figure 2**

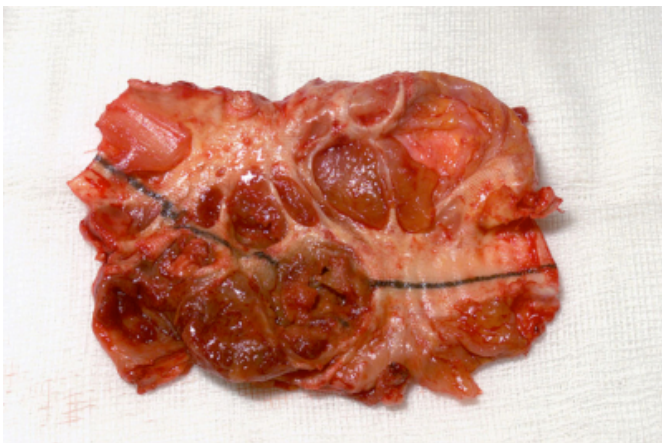
Figure 2: After complete resection of the graft aneurysm



Cut section of the specimen showed large amount of thrombus and complete breakdown of Dacron® graft was visible at several points. The patient made an uneventful recovery.

Figure 3: Complete breakdown of the graft at several points

**Figure 3**



## DISCUSSION

Dacron® grafts have proven to be a reliable arterial substitute, contributing significantly to the evolution of modern vascular surgery. Regardless of their widely acknowledged good performance throughout the years, structural defects have occasionally been noticed. The true incidence of graft failure is unknown, but it has been estimated to range from 0.5% to 3%<sub>1</sub>. Moreover, it can occur even many years after surgery. The average time from implantation to detection of graft failure is reported to be 77 months or 6.4 years.<sub>2</sub> This complication can occur in any type of Dacron® graft whether knitted, woven or double velour. But most cases have been reported with knitted

grafts.<sub>3</sub>

The probable causes of graft failure are manifold which includes material fatigue due to biodegradation, structural defects – round defects/longitudinal rents –, manufacturing defects, fabrication defects – knitted/woven/double-velour –, enzymatic degradation, immunological reactions – graft vs. host disease –, multiple sterilization, false storage, implantation trauma, chemical reactions due to bio-instability, infection and haematoma.

It is well known that knitted Dacron® grafts can dilate as much as 100% with an average of 15%-20%, a process which may continue over long periods after implantation.<sub>4</sub> Kim et al. postulated that grafts dilate in response to hydrostatic forces with most dilatation occurring in the first 30 days of graft placement.<sub>5</sub> In a small number of patients these factors possibly result in enough stretching or weakening of the graft wall with resultant dilatation to cause eventual graft rupture. Berger and Sauvage described that Dacron® failure is due to actual break down of Dacron® fibre or yarn. They postulated that graft failure was due to breakdown of individual Dacron® fibres with eventual disintegration of graft wall.<sub>1</sub> Localized areas of breakdown can be attributed to possible graft damage that has occurred during initial graft placement, perhaps due to traumatic instrumentation or may stem from manufacturing defects. Ultimately, graft dilatation and fibre breakdown leads to aneurysm formation and eventually rupture.

Grafts with excessive uncomplicated generalized dilatation should be carefully assessed at least annually. Non-uniform dilatations are more worrisome and decisions regarding management of that condition should be made on an individual basis. Surgical management is indicated for either a localized aneurysmal dilatation in the body of the graft or for graft rupture. At surgery, all dilated parts of the graft should be removed <sub>6</sub>, and if possible complete resection of the entire graft followed by total replacement with anastomosis on the native vessel has to be performed.

## CONCLUSION

Non-anastomotic aneurysm of Dacron® grafts used for infrainguinal arterial reconstruction, though unusual, can occur even many years after surgery. All these patients require meticulous follow-up, at least annually, to identify graft failure at an early stage before rupture. Diagnosis of graft failure can be suspected on clinical grounds and should be confirmed by imaging. Patients presenting with this problem require early surgical intervention to replace the

failed graft to prevent catastrophic complications like rupture.

### **References**

1. Berger K. Late fibre deterioration in Dacron Arterial Grafts. *Ann Surg* 1981; 193; 477-491
2. Aravanitis DP. Late Non-Anastomotic false aneurysm formation in Femoropopliteal PET grafts. *International*

*Angiology* 2001; 20; 348-350

3. Okabe T. A case of late non-anastomotic rupture of Dacron prosthesis. *Jpn J Vasc Surg* 1998; 7; 759-763

4. Nunn DB. Postoperative alterations in size of Dacron aortic grafts: an Ultrasonic evaluation. *Ann Surg* 1979; 189; 741-744

5. Kim GE. Dilation of synthetic grafts and junctional aneurysm. *Arch Surg* 1979; 114; 1293-1296

6. Shingu Y. Late rupture of knitted Dacron graft. *Ann Thorac Cardiovasc Surg* 2005; 11; 343-345

**Author Information**

**Senthil Nachimuthu**

Department of Surgery, Watford General Hospital

**M.F. Abdelhamid**

Department of Surgery, Watford General Hospital

**K. Grant**

Department of Surgery, Watford General Hospital

**R. Awad**

Department of Surgery, Watford General Hospital