

Avulsion-Fracture Of The Tibial Tuberosity During Osgood-Schlatter Disease In Adolescent: Case Report And Review Of The Literature

J Gaibor, D Sánchez, J Martillo, H Vinueza, K García, R Bobadilla

Citation

J Gaibor, D Sánchez, J Martillo, H Vinueza, K García, R Bobadilla. *Avulsion-Fracture Of The Tibial Tuberosity During Osgood-Schlatter Disease In Adolescent: Case Report And Review Of The Literature*. The Internet Journal of Orthopedic Surgery. 2005 Volume 3 Number 1.

Abstract

The Osgood-Schlatter disease (OSD) is generally benign and it appears frequently in adolescent men who make some type of sport activity. Avulsion-fracture of the tibial tuberosity during OSD is a rare variant in this group of patients.

We present the case of a 16-year old boy that sought medical consultation for presenting pain in the right tibial tuberosity with previous traumatic antecedent with an approximated evolution of 72 hours. The x-ray supported the OSD diagnosis.

Rest was indicated plus analgesics and cylinder cast immobilization for four weeks, then physiotherapy sessions began, presenting a spontaneous fracture-avulsion of the tuberosity. The fixation with screw solved the case. The patient returned sport activities after 10 months without presenting further complains.

The OSD handling is controversial, the presence of this type of complications causes that their treatment is strictly surgical.

INTRODUCTION

Avulsion-fracture of the tibial tuberosity in adolescent's patients during OSD is uncommon but not rare. The variant of osteochondritis of the tibial tuberosity (OSD) appears with relative frequency in adolescent young males people as an sport injury (1) the etiology is not defined but it thinks that the microtraumatic factors on their structure condition their presence. The avulsion-fracture of the tibial tuberosity is not common, represents less of 3 % of the epiphysiolisis and its origin is product of falls (jump) with the knee in full extension (2, 3) Pain located with edema and incapacity for the extension of the knee is the main manifestations. The projections in AP, lateral and in flexion of 30 degrees demonstrate their radiological characteristics. The ultrasound this winning acceptance like method diagnosis (4, 5)

The treatment of OSD without complication depends to the physiotherapy, while the avulsion-fracture with displacement needs sufficient anatomical surgical correction.

CASE REPORT

A 16-year old male patient that sought medical consultation for presenting pain located in the right tibial tuberosity secondary to trauma factor by sport of contact (soccer) approximately 72 hours. The physical examination did not

demonstrate coexisting injuries or additional symptomathology.

The laboratory tests were normal except by an increase of leukocytes (9000 xmm³). The AP and lateral x-ray of right knee showed to a suggestive pattern of OSD (to see fig 1) the left knee did not present evident alterations. With the OSD diagnosis oral analgesia was administered and cylinder cast immobilization by four weeks, thereafter begins physiotherapy sessions. During the second session with active and passive exercises, a spontaneous crackle with deformity at the right tibial tuberosity takes place that would be verified later with x-rays, like an avulsion-fracture of the same one, IIIa type according to the classification of Watson-Jones. It was continued with analgesic oral and its surgical resolution was purposed. The opened reduction with internal fixation with screw/washer and immobilization with plaster Paris during 6 weeks was its definitive treatment (to see fig 2)

Figure 1

Figure 1: Avulsion-fracture of the tibial tuberosity that extends whiles the joint. Type IIIa Watson-Jones classifications. (Gaibor J. J, 2004)

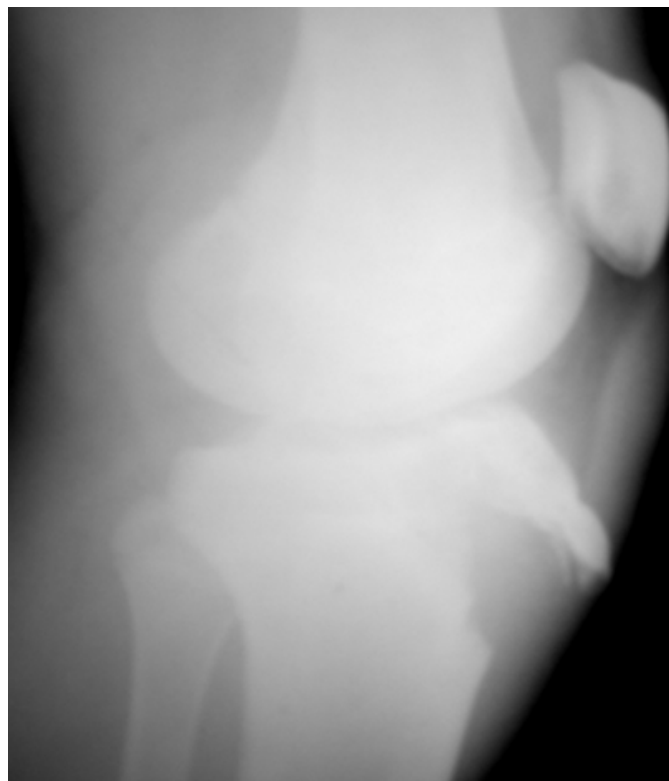
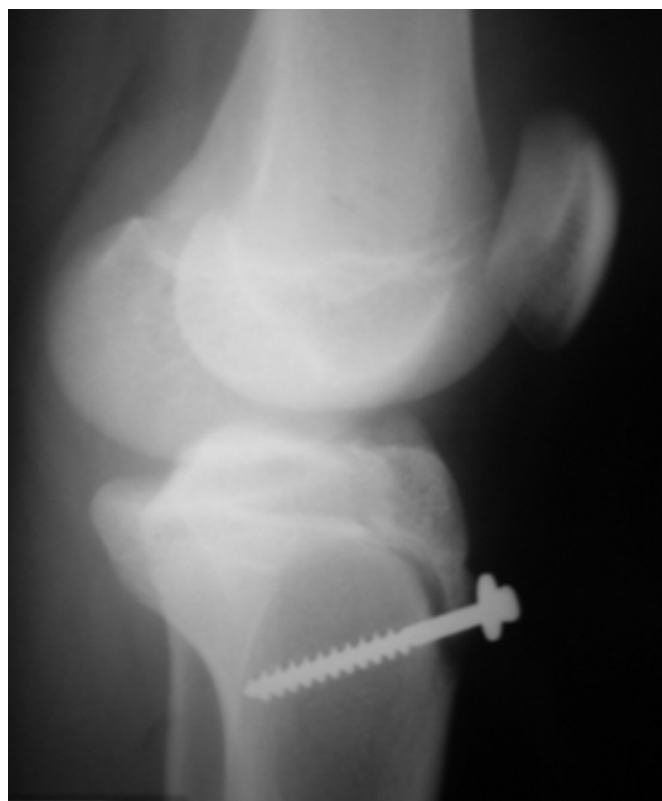

Figure 2

Figure 2: Post-operative. The fixation with screw solved the case. (Gaibor J. J, 2004)



The patient return to his daily and sport activities in complete normality after 10 months, without presenting further complains.

DISCUSSION

Robert Bayley Osgood and Carl Schlatter, described injuries concerning to the anterior tibial tuberosity in adolescents (₆) The Osgood-Schlatter disease can damage bone, cartilage, tendon and serous bursa, being the cartilage that is affected with more frequency followed of the avulsion of the tibial tuberosity (₇) The avulsion-fracture of the tibial tuberosity is infrequent. The informed average age is ± 13 years and 8 months. Rare time it happens after the closing of tibial epiphysis (_{8, 9}) OSD is a determining factor in the presentation of the avulsion-fracture of the tibial tuberosity. It's believed that the aseptic necrosis bone at the knee allows an area of greater sensitivity to the microtraumatic factors which would condition its loosening before a force correctly applied.

Nimityongskul et al, reported that 6 of their 8 patients with avulsion-fracture of the tibial tuberosity also presented previous symptomatic OSD (₁₀)

Also there is a strong association between OSD and a high position of the patella. This increase in the height of the patella would require an increase in the force that the quadriceps needed to obtain the full extension. This mechanism could be responsible for the injury for the tuberosity (11)

The sudden violent contraction of the quadriceps muscle is also implied in its pathogenesis (12)

On the basis of this has considered like group of risk to the young adolescents men between the 12 and 16 years and that specially practices one or more sports of contact or that they involve jump (soccer, basketball, volley, rugby, etc.) (7)

In our consultation from January of the 2000 to January of the 2005, 23 males patient with symptomatic OSD they were registered, corresponding an age average of +14 years and 3 months, and of these just one presented avulsion-fracture of the tibial tuberosity. Of the 22 conservative treated patients (analgesic, immobilization with plaster Paris and physiotherapy) 20 patients (90.9%) responded in a satisfactory way and 2 patients (9.09%) did not go to the programmed periodic controls. The traumatic antecedent is always present (13) Pain and inflammation on tibial epiphysis is absolute criteria, while the partial incapacity for the flexion-extension of the knee and it goes are relative. Fever can exist. The presence of a fracture-avulsion of the tibial tuberosity determines a marked degree of pain with incapacity for the extension, local edema and palpable deformity. The compartmental syndrome and the popliteal vascular injury are the variants more feared between their complications in addition to genu recurvatum, the calcification of the patellar tendon, diminution of the flexion amplitude and others (2, 14) The physical examination of the femoro-tibial-patellar joint and the radiographic study with sufficient projections are elementary at the time of emitting a diagnosis (15) Many authors propose the ultrasound like the first diagnosis option because it is a simple method, fast and economic and that would have the same exactitude that x-rays have (5, 16, 17)

The magnetic resonance also is a valid resource but its cost does not make (18) the diagnosis attractive.

The differential diagnosis should be done through other types of muscle-skeletal pain in adolescents (1) The avulsion-fracture of the tibial tuberosity was established by Ogden in 1980, complementing to Watson-Jones based on the

extension of the injury (2)

Type I: simple avulsion of the ossification center

Ia: without deviation

Ib: with deviation

Ic: with associated rupture of the patellar tendon

Type IIa: separation of the tibial tuberosity

IIb: separation with comminution of the ossification center of the tibial tuberosity

Type IIIa: extension of the outline of fracture to the joint of the knee

IIIb: extension of the outline of fracture to the joint of the knee with comminution of the ossification center of the tibial tuberosity.

Ryu in 1985 informed into the extension of an avulsion-fracture of the tibial epiphysis toward its posterior part, defining it as a fourth type (19)

The strategies of OSD treatment normally include analgesic and restrictions in physical activities that involve the knee (15)

The surgical treatment (excision of the tubercle, sequestrectomy) can be required in recurrent/chronic OSD or complications that determine distraction of the tuberosity or if the fracture outline compromises the joint of the knee (Types II and III) using for the effect screws, wire or Kirschner pins (2, 20, 21, 22, 23, 24, 25)

Literature reports a high frequency of presentation of type III the Watson-Jones classification. Buhari (26) in 1993 found this type of injury in 43% of the cases in comparison with 25 % of type I and 11 % of type II. The frequency of knee affection right/left is not significant with a light percentage in favor of the right handed people.

Our patient presented an injury of the anterior tibial tuberosity IIIa Type (Watson-Jones). The surgical reduction and fixation with screw and washer and immobilization with plaster Paris by 6 weeks marked to their definitive treatment and the return the daily activities in an established period of 10 months (to see fig. 2)

The anatomical reduction and sufficient physical therapy are the primary objectives in this type of injuries since it will depend on them the long term prognosis of the compromised joint and therefore the quality of life of the patient.

CORRESPONDENCE TO

J.J. Gaibor, MD. Phone: (593-4) 2680-460 Fax: (593-4) 2680-336 P.O. Box: 09-01-8415 E-mail: jerogaibormd@hotmail.com

References

1. Romero FJ, Hernandez C, Encinas A. Osgood-Schlatter disease in general practice. *Aten Primaria* 1990; 7(5):372-4.
2. Carvalho L, Almeida W, Salles F, et al. Fraturas da tuberosidade tibial em adolescentes. Relato de casos e revisao da literatura. *Rev Bras Ortop* 1995; 30(1-2): 87-90.
3. Baltaci G, Ozer H, Tunay VB. Rehabilitation of avulsion fracture of the tibial tuberosity following Osgood-Schlatter disease. *Knee Surg Sports Traumatol Arthrosc* 2004; 12(2):115-8.
4. Mahlfeld K, Kayser R, Franke J, et al. Ultrasonography of the Osgood-Schlatter disease. *Ultraschall Med* 2001; 22(4):182-5.
5. Lanning P, Heikkinen E. Ultrasonic features of the Osgood-Schlatter lesion. *J Pediatr Orthop* 1991; 11(4):538-40.
6. Nowinski RJ, Mehlman CT. Hyphenated history: Osgood-Schlatter disease. *Am J Orthop* 1998; 27(8):584-5.
7. Bergami G, Barbuti D, Pezzoli F. Ultrasonographic findings in Osgood-Schlatter disease. *Radiol Med (Torino)* 1994; 88(4):368-72.
8. Mosier S, Stanitski C. Acute Tibial Tubercle Avulsion Fractures. *Journal of Pediatric Orthopedics* 2004; 24(2):181-184.
9. Vainionpaa S, Bostman O, Patiala H, et al. Fracture of the tibial tuberosity in adolescents. *Arch Orthop Trauma Surg* 1985; 104(1):20-2.
10. Nimityongskul P, Montague WL, Anderson LD. Avulsion fracture of the tibial tuberosity in late adolescence. *J Trauma* 1988; 28(4):505-9.
11. Aparicio G, Abril JC, Calvo E, et al. Radiologic study of patellar height in Osgood-Schlatter disease. *J Pediatr Orthop* 1997; 17(1):63-6.
12. Nanninga AJ, Josaputra HA. Tibial tuberosity fracture in adolescents--report of a case and review of the literature. *Neth J Surg* 1987; 39(5):144-6.
13. Demirag B, Ozturk C, Yazici Z, et al. The pathophysiology of Osgood-Schlatter disease: a magnetic resonance investigation. *J Pediatr Orthop B* 2004; 13(6):379-82.
14. Zimble S, Merkow S. Genu recurvatum: a possible complication after Osgood-Schlatter disease. Case report. *J Bone Joint Surg Am* 1984; 66(7):1129-30.
15. Dunn JF. Osgood-Schlatter disease. *Am Fam Physician* 1991; 43(2):400, 402, 405.
16. Blankstein A, Cohen I, Heim M, et al. Ultrasonography as a diagnostic modality in Osgood-Schlatter disease. A clinical study and review of the literature. *Arch Orthop Trauma Surg* 2001; 121(9):536-9.
17. Delle C, Dell'Orso E, Manes L, et al. Echography compared with conventional radiology in Osgood-Schlatter disease. *Radiol Med (Torino)* 1989; 77(6):631-4.
18. Rosenberg ZS, Kawelblum M, Cheung YY, et al. Osgood-Schlatter lesion: fracture or tendinitis? Scintigraphic, CT, and MR imaging features. *Radiology* 1992; 185(3):853-8.
19. Ryu R, Dehenham J. An unusual avulsion fracture of the proximal tibial epiphysis. *Clin Orthop* 1985; 195: 181-184.
20. Orava S, Malinen L, Karpakka J, et al. Results of surgical treatment of unresolved Osgood-Schlatter lesion. *Ann Chir Gynaecol* 2000; 89(4):298-302.
21. Flowers MJ, Bhadreshwar DR. Tibial tuberosity excision for symptomatic Osgood-Schlatter disease. *J Pediatr Orthop* 1995; 15(3):292-7.
22. Trail IA. Tibial sequestrectomy in the management of Osgood-Schlatter disease. *J Pediatr Orthop* 1988; 8(5):554-7.
23. Windhager R, Engel A. Surgical treatment of Osgood-Schlatter disease. *Z Orthop Ihre Grenzgeb.* 1988 Mar-Apr;126(2):179-84.
24. Schwarzkopf W. Rupture of the tibial tuberosity in children and adolescents. *Zentralbl Chir.* 1983; 108(4):200-5.
25. Figueiredo G, Oliveira T, Oliveira L, et al. Tratamento cirúrgico da dor crônica na lesão de Osgood-Schlatter: relato de dois casos. *Rev Bras Ortop* 2003; 38(8): 491-496.
26. Buhari SA, Singh S, Wong HP, et al. Tibial tuberosity fractures in adolescents. *Singapore Med J* 1993; 34(5):421-4.

Author Information

Jerónimo J. Gaibor

Department of Traumatology, Surgery,, Clinic North Kennedy, Hospital Luis Vernaza

David J. Sánchez

Department of Surgery, Clinic North Kennedy

Julio C. Martillo

Department of Traumatology, Hospital Luis Vernaza

Harold R. Vinueza

Department of Traumatology, Hospital Luis Vernaza

Kléver M. García

Department of Traumatology, Hospital Luis Vernaza

Roberto F. Bobadilla

Department of Traumatology, Clinic North Kennedy, Hospital Luis Vernaza