

# Appendiceal Diverticulitis

H Kabiri

---

## Citation

H Kabiri. *Appendiceal Diverticulitis*. The Internet Journal of Surgery. 2004 Volume 7 Number 1.

## Abstract

The incidence of appendiceal diverticulitis in pathologic specimens is 0.004-2.1% and is unusual in younger patients. Despite being first described in 1893, this condition is commonly dismissed by surgeons and pathologists as a variant of true appendicitis. However, appendiceal diverticulitis is a discrete clinical process that must be considered in the appropriate setting because of the much higher risk of perforation. The average age is older, the pain is often intermittent, and while it can be localized in the right lower abdominal quadrant, it is of longer duration. Although no further treatment besides appendectomy is needed, it is important that surgeons be aware of this condition, as the clinical presentation can be different from classical acute appendicitis. Patients seek medical treatment much later than those with classic appendicitis and if there is a delay in establishing the correct diagnosis, perforation within the mesentery is found at the time of operation. Also, it is often mistakenly identified as carcinoma and it has a higher rate of perforation and a longer convalescence. We describe a case of a 42-year-old man and review the literature.

## INTRODUCTION

Appendiceal diverticulitis as the etiology of right lower quadrant pain is an uncommon entity in younger populations. Although infrequently encountered, this possibility must be entertained in the differential diagnosis of abdominal pain, especially in the adult patient. Since the clinical presentation can be different from classical acute appendicitis, it is important that surgeons be aware of this condition. As is shown in the clinical presentation of the case we describe, the classical right lower quadrant pain can be absent and in case of delay in establishing the correct diagnosis, those with appendiceal diverticulitis are 4 times more likely to have a perforation, which increases mortality 30-fold compared with simple appendicitis.<sup>4</sup>

However, generalized peritonitis is unusual since the inflammatory process is contained within the mesoappendix by surrounding adhesions. This "mass like" effect is often mistakenly identified as carcinoma.<sup>4</sup> Compared with patients who have simple appendicitis, those with appendiceal diverticulitis have a higher rate of perforation and a longer convalescence.<sup>7,9,12</sup> The disease was first described in 1893 by Kelynack,<sup>1</sup> as a "greatly distended appendix, totally shut off from the cecum, having two distinct diverticular processes directed between the folds of the mesentery." Since then, this disease process has been characterized as either congenital or acquired. The congenital form is exceedingly rare, and diverticularization

involves all layers of the appendiceal wall. The acquired form, which is more prevalent, results from mucosal herniations through a muscular defect on the mesenteric border of the appendix. Commonly dismissed by surgeons and pathologists as a variant of true appendicitis, appendiceal diverticulitis is actually a discrete clinical pathophysiological process that manifests differently than classic appendicitis in regard to age, onset of symptoms, operative findings, and histopathological examination.

While uncommon, Appendiceal diverticulitis is identified in up to 2% of appendectomy specimens.<sup>2,3,4</sup> Although specific causes are unknown, this disease is hypothesized to occur secondary to orifice obstruction where subsequent inflammation predisposes to the formation of false diverticula.<sup>5</sup> Treatment of symptomatic appendiceal diverticulitis is similar to that of acute appendicitis—that is, surgical resection. We describe appendiceal diverticulitis in a 42-year-old man and briefly review the literature on this uncommon condition.

## REPORT OF A CASE

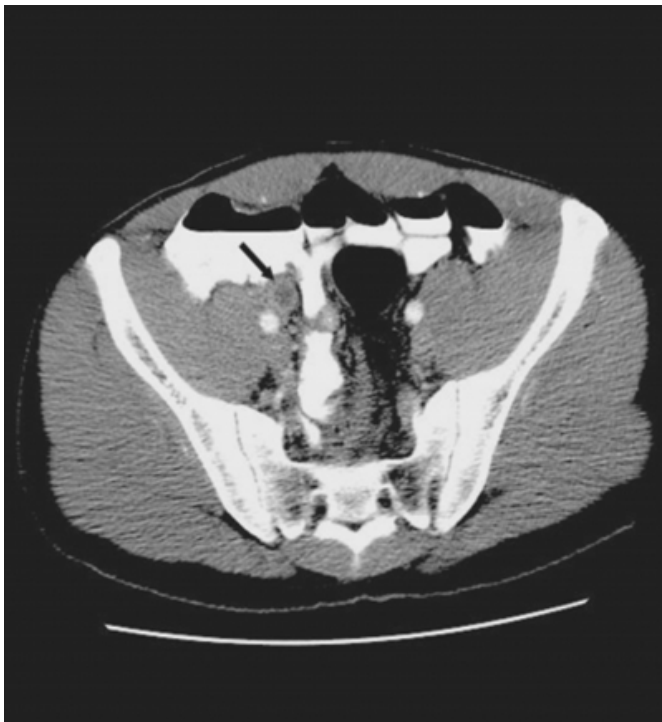A 42-year-old African man with past medical history of history of 15 years of diffuse abdominal pain and a negative extensive medical work-up presented to the emergency department because of a 2-day history of exacerbation of abdominal pain located in the epigastric area. The pain was progressive in severity and was associated with anorexia,

nausea, vomiting, subjective fever, and chills. Physical exam revealed a man in moderate distress with a temperature of 38.1°C. The abdomen was soft with epigastric tenderness in deep palpation. Voluntary guarding was noted, but rebound could not be elicited. The leukocyte count was  $14.7 \times 10^9/L$  with no left shift. Findings on plain x-ray films were non specific, but computed tomography (Figure 1 ) revealed thickening of sigmoid loop of the colon and 1.2 cm dilatation of appendix with rim enhancement compatible with acute appendicitis.

In the light of patient's symptoms and 2-day history of abdominal pain and imaging reports, patient was transferred to the operating room. Through a modified McBurney's incision a nodular, inflamed appendix was found. Other than nodularity of appendix no evidence of lymph node or malignancy was noted. Pathologic analysis demonstrated appendiceal diverticulitis (Figure 2 ). Histologically, multiple appendiceal diverticulae was identified with acute inflammation but no perforation. The patient was treated for two days with broad- spectrum intravenous antibiotic, and he recovered without complications at 2-year follow-up the patient was doing well.

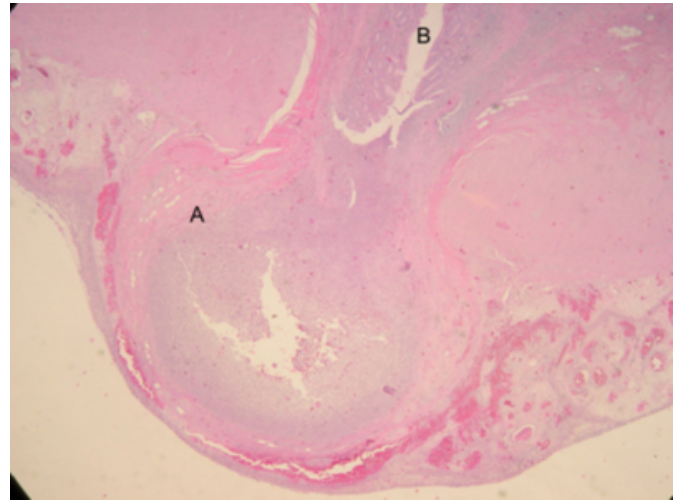
### Figure 1

Figure 1: Computerized tomography of appendiceal diverticulitis. As in this case, the radiologic picture is not different from regular appendicitis



### Figure 2

Figure 2: Pathologic picture of appendiceal diverticulitis. Inflamed Diverticulum is protruding through the muscularis mucosa (A). Appendiceal lumen (B) is full of inflammatory cells



## DISCUSSION

Diverticular disease of the vermiform appendix can mimic acute appendicitis, Crohn disease, or several other pathologic conditions. Both appendiceal diverticular disease and acute appendicitis can manifest with right lower quadrant pain, fever, tenderness at McBurney point, and leukocytosis. However, appendicitis classically manifests in patients before the third decade of life, with coexistent anorexia, nausea, and emesis; often, operative intervention is necessary within 24 hours. In contrast, appendiceal diverticulitis usually appears after the third decade of life with intermittent insidious pain occurring 1 to 14 days before presentation (Table-1) Occasionally, these 2 conditions can be distinguished with a thorough history and physical examination. With detailed questioning, some patients will report prior episodes of right lower quadrant pain (ie, “chronic appendicitis”). In the literature, few gastrointestinal symptoms are demonstrated with appendiceal diverticular disease. Possible risk factors for appendiceal diverticulitis include chronic appendicitis, cystic fibrosis, age greater than 30 years, and male sex.<sup>6,7</sup> Classically, there is a diverticulum with a cylindrical appearance, and macroscopically it may be associated with periappendicitis.<sup>9</sup> Ultrasonography has been used to identify peridiverticulitis, but its role in detecting appendiceal diverticulitis remains to be established.<sup>5</sup> Conventional surgical resection is the treatment of choice for symptomatic patients and should be done early to avoid the increased morbidity and mortality associated with perforation and

peritonitis.<sup>6,10,11</sup> However a recent report described uncomplicated laparoscopic removal of the vermiform appendix with a 7-mm inflamed diverticulum.<sup>10</sup> Laparoscopic or conventional resection of the incidentally discovered appendix with diverticulosis is indicated because two thirds of patients will experience an episode of acute inflammation. Once the diagnosis of appendiceal diverticular disease has been established, we recommend resection; however, some investigators doubt the potential benefit of a prophylactic appendectomy.<sup>6,11</sup>

Figure 3

Table 1: Presentation of Appendiceal Diverticulitis

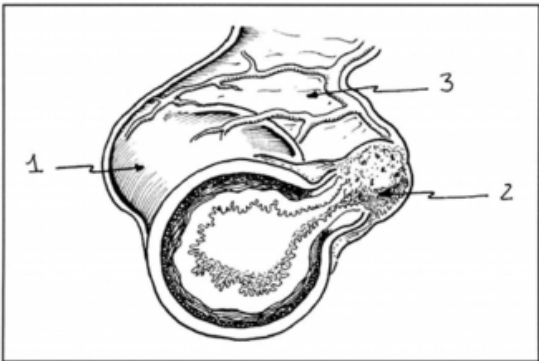
Symptom	Onset	Characteristics
Right lower quadrant abdominal pain	2-13 d	Insidious, intermittent, originates in right lower quadrant
Nausea, anorexia, emesis	Variable	Often absent
Fever	Variable	Temperature $\geq 38.4^{\circ}\text{C}$

From: Phillips: Mayo Clin Proc, Volume 74(9).September 1999.890-892

Appendiceal diverticulitis can be classified into 1 of 4 subtypes.<sup>4</sup> Type 1 is the classic form in which a normal-appearing appendix is found with an acutely inflamed diverticulum (Figure -1 ). Type 2 involves an acutely inflamed diverticulum with surrounding appendicitis, and type 3 is conventional appendicitis with an incidental, uninvolved diverticulum. Type 4 is an incidental appendiceal diverticulum with no evidence of appendicitis or diverticulitis. Although there are incidental reports of congenital diverticula (with possible linkage to a group D chromosomal trisomy 13-15),<sup>13,14</sup> symptomatic diverticula are classically pulsion in nature. These acquired lesions occur on the mesenteric border of the appendix, often in association with an arteriolar blood vessel and thinning of the muscularis propria.<sup>5,8,15</sup> Mucosa is thought to prolapse through the muscularis propria because of increased intraluminal pressure.<sup>4</sup> Another hypothesis is that appendiceal diverticula are the result of residual weakness in the appendiceal wall after an episode of appendicitis.<sup>8</sup> Microscopic examination of the appendiceal specimen often reveals a small lumen with increased thickness of the submucosa and muscular wall, as well as atrophy of the mucosal lymphoid tissue.<sup>9</sup> These findings are likely physiological responses to a chronically elevated luminal pressure. As demonstrated in our case, appendiceal diverticula occur in the absence of colonic diverticulosis.<sup>13</sup>

Figure 4

Figure 3: Acute diverticulitis of the vermiform appendix (cross-section). 1, Normal-appearing appendix; 2, inflamed diverticulum; 3, mesoappendix.



From: Phillips: Mayo Clin Proc, Volume 74(9).September 1999.890-892

Although treatment is similar to that for appendicitis, diverticular disease of the vermiform appendix is distinctly different and should be considered separately in the differential diagnosis of right lower quadrant pain, especially in the elderly population and those with compromised immune system. Because of an insidious onset, patients with appendiceal diverticulitis seek medical treatment much later than those with classic appendicitis

References

1. Kelyack TN. A Contribution to the Pathology of the Vermiform Appendix. London, England: HK Lewis; 1893:60.

2. Stout AP. A study of diverticular formation in the appendix. Arch Surg. 1923;6:793-829.

3. Spriggs EI, Marxer OA. Intestinal diverticula. BMJ. 1926;1:130-134.

4. Lipton S, Estrin J, Glasser I. Diverticular disease of the appendix. Surg Gynecol Obstet. 1989;168:13-16.

5. Skaane P, Strom EH. Peridiverticulitis of the appendix: an unusual ultrasonic "target lesion." J Clin Gastroenterol. 1990;12:353-356.

6. Lock JH, Wheeler WE. Diverticular disease of the appendix. South Med J. 1990;83:350.

7. Fitzer PM, Rao KG, Bundrick TJ. Diverticulosis of the appendix: radiographic and clinical features. South Med J. 1985;78:1512-1514.

8. Esparza AR, Pan CM. Diverticulosis of the appendix. Surgery. 1970;67:922-928.

9. Deschenes L, Couture J, Garneau R. Diverticulitis of the appendix: report of sixty-one cases. Am J Surg. 1971;121:706-709.

10. BirdSong D, Kolachalam RB. Laparoscopic appendectomy for diverticular disease of the appendix. Surg Rounds. 1998;21:281-282.

11. Lenz TR. Diverticulitis of the appendix: report of a case. Rocky Mt Med J. April 1968;65:31-32.

12. Delikaris P, Stubbe Teglbjaerg P, Fisker-Sorensen P, Balsley I. Diverticula of the vermiform appendix: alternatives of clinical presentation and significance. Dis Colon Rectum. 1983;26:374-376.

13. Trollope ML, Lindenauer SM. Diverticulosis of the appendix: a collective review. Dis Colon Rectum.

1974;17:200-218.

14. Wilson RR. Diverticula of the appendix and certain

factors in their development. Br J Surg. 1950;38:65-81.

15. Edwards HC. Diverticula of vermiform appendix. Br J Surg. 1934;22:88-107.

**Author Information**

**Hamed Kabiri, M.D.**

Department of Surgery, Mercy Catholic Medical Center