

Verrucous Carcinoma Arising In A Chronic Non-Healing Ulcer Of The Foot Of A Diabetic Patient

D Sarma, J Wang, C Bewtra, L Lee

Citation

D Sarma, J Wang, C Bewtra, L Lee. *Verrucous Carcinoma Arising In A Chronic Non-Healing Ulcer Of The Foot Of A Diabetic Patient*. The Internet Journal of Dermatology. 2006 Volume 5 Number 1.

Abstract

We report a case of a verrucous carcinoma arising in a chronic non-healing ulcer of the plantar skin in a diabetic patient. A brief review of the verrucous carcinoma of foot is presented.

SOURCE OF SUPPORT

None

INTRODUCTION

Verrucous carcinoma is an uncommon, well-differentiated variant of squamous cell carcinoma that is regarded as a low grade locally invasive malignant tumor with rare potential for distant metastasis. These tumors show a clinical and pathologic similarity to condylomata acuminata, but they are usually larger, indolent and locally destructive. Verrucous carcinoma is usually seen in oral cavity, genitoanal region, and plantar surface of foot. They are known to arise in chronic ulcers, in skin after radiation therapy, old scars, and rarely in the amputation stump [1].

CASE REPORT

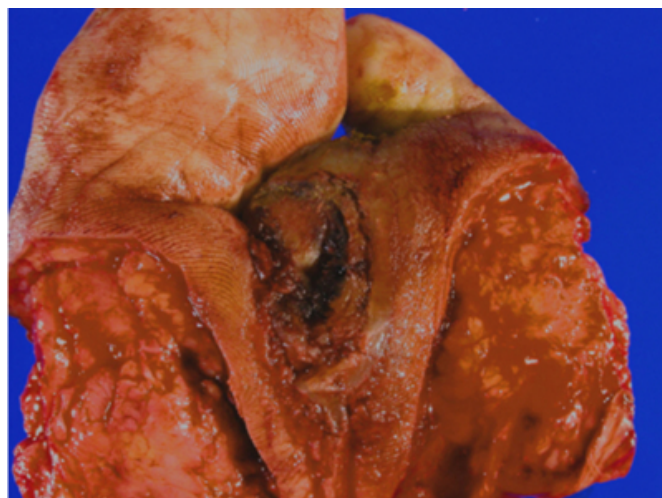A 63-year-old man with a 20-year history of diabetes mellitus, peripheral vascular disease and hypertension presented with a non-healing ulcer of left foot. Approximately 18 months prior, the patient developed dry gangrene of his toes of the same foot. He underwent amputation of the 2nd, 3rd, and 4th toes during that period. In addition to the gangrenous toes, a hyperkeratotic, focally ulcerated lesion over the anterior plantar surface was also identified. This was thought to be a callus. He underwent multiple debridement of the plantar lesion followed by regular wound care over this period. The lesion recurred and grew much larger with central ulceration. Subsequently, a distal amputation of the foot was performed.

On gross examination, the left distal foot measured 9.0x8.0x4.0 cm. There were only two toes (small and great) attached with the left foot. There was one somewhat ill-

defined, markedly hyperkeratotic and centrally ulcerated lesion measuring 3.0 x 1.7 on the plantar surface of the left foot (Figure 1). The lesion was separated from the well-healed sites of the previous toe amputation by normal skin.

Figure 1

Figure 1: Ulcerated verrucous carcinoma of the plantar foot.



On microscopic examination, there was marked hyperkeratosis, papillomatosis, acanthosis, irregular elongation of the rete ridges with pushing type of invasion with bulbous proliferation of well-differentiated keratinocytes (Figs.2 and 3). A diagnosis of a well differentiated verrucous squamous epithelial lesion suggestive of verrucous carcinoma was made. Surgical margins were clear.

Figure 2

Figure 2: Verrucous carcinoma, low magnification.

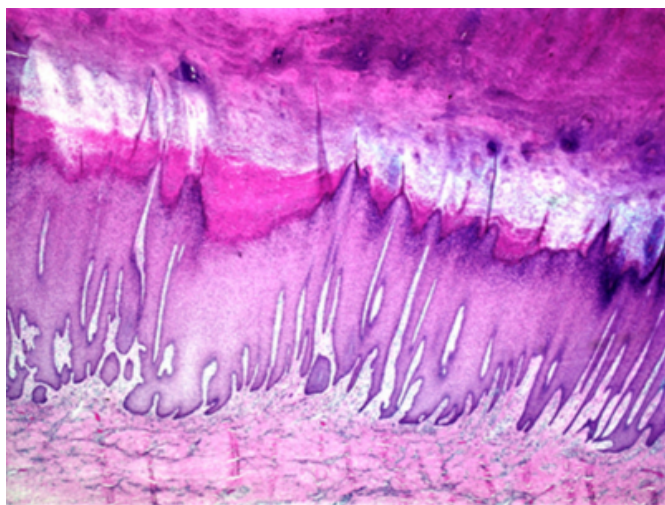
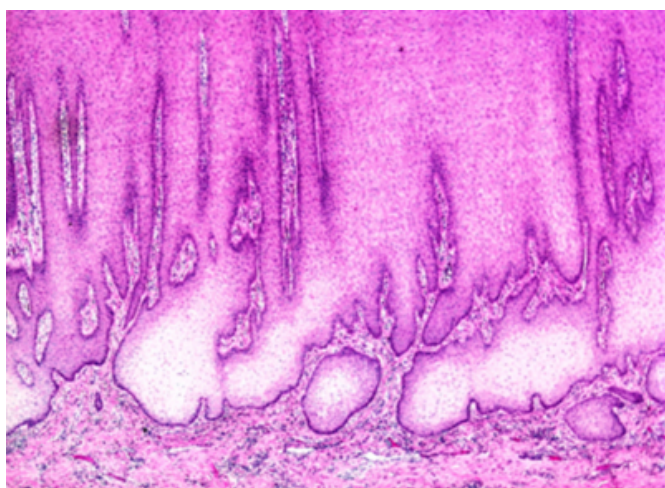


Figure 3

Figure 3: Burrowing invasion of the dermis by bulbous broad columns of well differentiated squamous epithelium.



COMMENT

Verrucous carcinoma is a low-grade squamous cell carcinoma that can be classified into three major groups based on the sites of origin: verrucous carcinoma of oral cavity, verrucous carcinoma of genitoanal region, and plantar verrucous carcinoma. Verrucous carcinoma of the oral cavity shows white, cauliflower-like lesions that can involve large areas of oral mucosa. Verrucous carcinoma of the genitoanal region, most commonly involving the glans penis, vulva, and the anal region, consists of papillomatous proliferations that ultimately may penetrate the urethra and adjacent structures.

Plantar verrucous carcinoma, also called epithelioma cuniculatum, was first described by Aird in 1954 [2]. The

lesion initially shows a striking resemblance to an intractable plantar wart. As the exophytic mass grows, it shows a great tendency toward deep, penetrating growth, resulting in numerous deep crypts resembling the burrows of rabbits, hence the name cuniculatum. Although the tumor grows slowly, it will eventually invade the plantar fascia, may destroy metatarsal bones, and may invade the skin of the dorsum of the foot.

Multiple etiological factors have been implicated in plantar verrucous carcinoma including history of trauma, thorn prick, chronic application of some pharmaceutical agents and chronic scarring and rarely a late complication of leg amputation [1]. Occurrences of this tumor are also reported in chronic ulcers of the foot [3], especially in diabetic patients [4]. In diabetic patients with both neuropathy and significant peripheral vascular disease, altered wound healing and inflammatory responses to necrotic tissue and disturbed angiogenesis have been reported. The diabetic patients with chronic ulcer or verrucous skin lesion on the feet should have deep biopsy to rule out verrucous carcinoma. Histological features favoring the diagnosis of verrucous carcinoma include: (1) deep invasion, (2) branching tunnels and keratin-filled clefts, (3) large pale keratinocytes with large nuclei, and (4) edematous stroma with chronic inflammatory cells. Histologic differentiation from pseudoepitheliomatous hyperplasia or benign verrucous hyperplasia remains a difficult problem. Clinical history of non-healing verrucous lesion over a long period along with the histologic finding of bulbous pushing-type of invasion by pale well-differentiated keratinocytes in the dermis will be highly suggestive of a verrucous carcinoma. In our case, verrucous carcinoma of the plantar skin was diagnosed after examining the amputated foot. The patient had long-term history of diabetes mellitus and has had multiple debridements in the past, but a cancer diagnosis was not established because of the superficial nature of the debrided tissue showing only keratinous material. A deep biopsy may establish a diagnosis of a verrucous carcinoma in a non-healing chronic ulcer.

A possible viral origin of verrucous carcinoma has been suggested because of a close relationship with plantar warts. Virus-like particles were demonstrated in a few cases of plantar verrucous carcinoma. Recently, HPV type 2 and 16 were reported in several cases of plantar verrucous carcinoma by using PCR [5, 6]. It was stipulated that HPV virus altered the genes of c-ki-ras, p53, and Rb genes eventually leading malignant changes.

ACKNOWLEDGMENTS

We thank Bette Gibilisco and Erick Tidiane for the photography.

CORRESPONDENCE TO

Deba P Sarma, MD Department of Pathology Creighton University Medical Center Omaha, NE 68131 E-mail: debasarma@creighton.edu

References

1. Sarma D, Hansen TP, Adickes, ED: Carcinoma arising in the leg amputation stump; The Internet Journal of Dermatology. 2006; Volume 4, Number 1.
2. Aird I, Johnson HD, Lennox B, Stansfeld AG. Epithelioma cuniculatum: a variety of squamous carcinoma peculiar to the foot. Br J Surg. 1954; 42:245-250.
3. Ho J, Diven DG, Butler PJ, Tying SK. An ulcerating verrucous plaque on the foot. Verucous carcinoma (epithelioma cuniculatum). Arch Dermatol. 2000; 136(4): 547-8, 550-1.
4. Rosales MA, Martin BR, Armstrong DG, Nixon BP, Hall HR. Verrucous hyperplasia. A common and problematic finding in the high-risk diabetic foot. J Am Podiatr Med Assoc. 2006; 96(4):348-350.
5. Noel JC, Peny MO, Detremmerie O, Verhest A, Heenen M, Thiry L, De Dobbeleer G. Demonstration of human papillomavirus type2 in a verrucous carcinoma of the foot. Dermatology. 1993; 187(1): 58-61.
6. Schell BJ, Rosen T, Rady P, Arany I, Tschen JA, Mack MF, Tying SK. Verrucous carcinoma of the foot associated with human papillomavirus type 16. J Am Acad Dermatol. 2001; 45(1): 49-55.

Author Information

Deba P. Sarma, M.D.

Department of Pathology, Creighton University Medical Center

Jeff F. Wang, M.D.

Department of Pathology, Creighton University Medical Center

Chhanda Bewtra, M.D.

Department of Pathology, Creighton University Medical Center

Lisa M. J. Lee, Ph.D.

Department of Pathology, Creighton University Medical Center