

Brachial Plexus: Our Anatomical Findings. (Part I)

G Milanes-Ruges, H Foyaca-Sibat, L Ibañez-Valdés, M Rodriguez-Neyra

Citation

G Milanes-Ruges, H Foyaca-Sibat, L Ibañez-Valdés, M Rodriguez-Neyra. *Brachial Plexus: Our Anatomical Findings. (Part I)*. The Internet Journal of Neurology. 2007 Volume 9 Number 2.

Abstract

A retrospective review from our previous anatomical dissections looking for anatomical variations of the brachial plexus is made. All those dissections were made for teaching purposes at the Laboratory of Anatomy from Walter Sisulu University between January 2000 and January 2008 and the commonest findings are reported in this study. Its correlations with expected clinical manifestations in nerves injury are established.

INTRODUCTION

The brachial plexus is usually formed by the fusion of the anterior primary rami of the C5-8 and the T1 spinal nerves. It supplies the muscles of the back and the upper limb. The C5 and C6 fuse to form the upper trunk, the C7 continues as the middle trunk and the C8 and T1 join to form the lower trunk. Each trunk, soon after its formation, divides into anterior and posterior divisions. The anterior divisions of the upper and middle trunks form the lateral cord; the anterior division of the lower trunk continues as the medial cord and the posterior divisions of all three forms the posterior cord. The cords then give rise to various branches that form the peripheral nerves of the upper limb. The anterior divisions supply the flexor compartments of upper limb and the posterior divisions, the extensor compartments. Since the brachial plexus is a complex structure, variations in formation of roots, trunks, divisions and cords are common. The present study deals with some of the common variations and some hitherto unknown variations of the brachial plexus. [1]

Axillary artery passes between the lateral and medial cords of the plexus. The medial root of median nerve crosses the axillary artery to unite with the lateral root to form the median nerve which is lateral and anterior to the axillary artery. [1]

Lesions on brachial plexus is a challenger for general practitioner and in some cases even for experienced neurologist, orthopedist surgeons and neurosurgeons because anatomical variations of the brachial plexus can cause a broad spectrum of clinical manifestations, therefore to consider those anatomical variations for clinical reasoning is

recommended. However, because is not possible to memorize each clinical picture for every anatomical change we decide to show the commonest anatomical presentation of brachial plexus and to propose its clinical manifestations in nerve injuries based on those findings.

MATERIAL AND METHOD

The study was done in the Department of Anatomy, Faculty of Health Sciences, Walter Sisulu University, and Mthatha, South Africa. On routine dissection on embalmed African cadavers, variations in the formation of the brachial plexus were found. The clavicle and the scalenus anterior were cut to expose the roots and trunks of the plexus. The divisions and their branches were followed to the muscle they supplied for confirmation.

RESULTS AND COMMENTS

Brachial Plexus innervates the upper limb. As it is the point of formation of many nerves, variations are common. Knowledge of these is important to anatomists, radiologists, anesthesiologists and surgeons. The presence of anatomical variations of the peripheral nervous system is often used to explain unexpected clinical signs and symptoms.

In some cases the brachial plexus were formed from roots C5, C6, C7, C8 and T1 (Figure 1) and the upper trunk was formed by the union of C5 and C6. Before joining the C6, the C5 gave a direct branch to the Subclavius Muscle and the Dorsal Scapular Nerve. Similarly the C6 gave two small direct branches to Pectoralis Minor and a large branch to the Latissimus Dorsi Muscle (Thoracodorsal Nerve).

As is well known, the brachial plexus is a somatic nerve

plexus formed by intercommunications among the ventral rami of the lower four cervical nerves (C 5 - C 8) and most of the anterior ramus of the first thoracic nerve (T 1). The plexus is responsible for the motor innervations to all of the muscles of the upper limb with the exception of the trapezius and levator scapula. It supplies all of the cutaneous innervations of the upper limb with the exception of the area of the axilla (armpit) (supplied by the intercostobrachial nerve), an area just above the point of the shoulder (supplied by supraclavicular nerves) and the dorsal scapular area which is supplied by cutaneous branches of dorsal rami. The brachial plexus communicates with the sympathetic trunk by gray rami communicates that join all the roots of the plexus and are derived from the middle and inferior cervical sympathetic ganglia and the first thoracic sympathetic ganglion.

This plexus is very common injured, the knowledge of the pathway follow by its branches and the muscles innervated by it, are very important for the clinician in order to identify the exact location of any lesion.

It is composed of: roots, trunks, divisions and cords

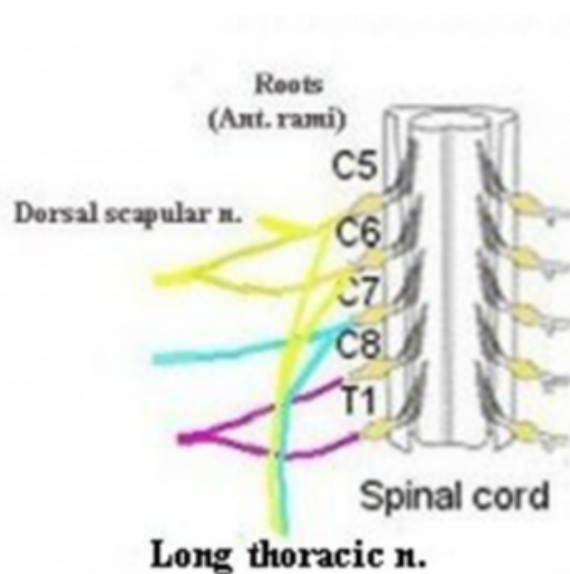
Roots: The roots are the anterior rami of C5 to C8 and most of T1.

Branches of the roots:

Dorsal scapular n.

Long thoracic n.

Figure 1



Long thoracic n: (Picture 1)

Originates from the anterior rami of C5, C6 and C7. Lies on the superficial aspect of the serratus anterior muscle.

Injury of the long thoracic nerve:

It can be injured by blow or pressure of the posterior triangle of the neck or during surgical procedure of radical mastectomy.

Serratus anterior palsy is also seen after carrying loads in the shoulder and toxoid injections.

Consequences:

- 1- Paralysis of the serratus anterior resulting in the inability to rotate the scapula during the movement of abduction of the arm.
- 2- The vertebral border and inferior angle of the scapula will not longer be kept closely applied to the chest wall and will protrude posterior, a condition known as "Winged scapula"

Normally the long thoracic nerve is formed from the contribution of the C5, C6 and C7 [2]. Horwartz and Tocantins have found that in 8% of the cases, C7 may fail to contribute and some times failure from contributions from C5 have been observed in dissecting laboratories [3,4].

Trunks: (See picture 2)

- 1- The superior trunk is formed by the union of C5 and C6 roots.
- 2- The middle trunk is the continuation of the C7 root.
- 3- The inferior trunk is formed by the union of the C8 and T1 roots.

Branches of the trunks:

- 1- The suprascapular n.
- 2- The subclavius n.

The suprascapular nerve: It runs through the suprascapular notch to supply the supra and infraspinatus muscle.

Injuries of the suprascapular n.

It may be injured in fractures of the clavicle or scapula or carrying heavy loads over the shoulder.

Consequences: 1- Pain in the suprascapular region or at the

back of the shoulder.

2- Weakness of shoulder abduction and external rotation.

Wasting of the supraspinatus.

Divisions:

Each of the three trunks divides into anterior and posterior division.

The three anterior divisions give rise to peripheral nerves that supply the anterior compartment of the arm and forearm. (Flexor muscles)

The three posterior divisions combine and give rise to peripheral nerves that supply the posterior compartment of the arm and forearm. (Extensor muscles)

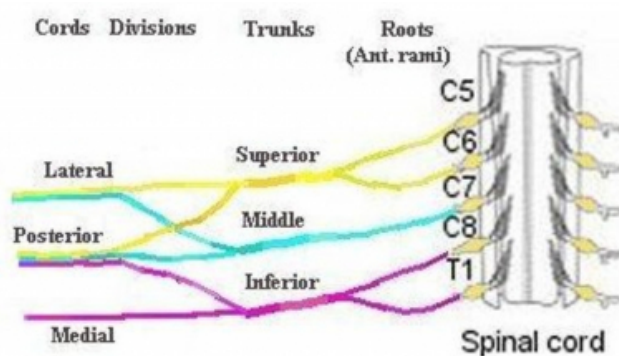
Cords: The three cords originate from the divisions and are related to the second part of the axillary's artery.

The lateral cord results from the union of the anterior division of the upper and middle trunks. It has contribution from C5 to C7.

The medial cord is the continuation of the anterior division of the inferior trunk. It has contribution from C8 to T1.

The posterior cord is from the union of all three posterior divisions. It has contribution from C5 to T1.

Figure 2



(Branches of the lateral cord. (Picture 2))

1- Lateral pectoral n.

2- Musculocutaneous n.

3- Lateral root of the median nerve

Many authors have described that the lateral pectoral nerve may arise by one root from the lateral cord or by two roots

from the anterior divisions of upper and middle trunks [4,5,6].

The nerve to coracobrachialis is a direct branch from the lateral cord. High origin of nerve to coracobrachialis from Lateral cord is not an uncommon finding [2,7,8]

The musculocutaneous n. (C5,C6,C7)

Penetrate the coracobrachialis muscle. In the arm passes between the Biceps brachii and brachialis m. Innervates all three flexor muscles of the anterior compartment of the arm.

It terminates as the lateral cutaneous nerve of the forearm. This branch supplies the skin over the front and lateral aspect of the forearm.

Injury to the musculocutaneous n:

It is rarely injured because of its protected position between biceps brachii and brachialis m.

If it is injured high up in the arm:

Motor problem: It is minimum because flexion of the forearm is still done by the brachialis muscle (that is supplied also by the radial n) and the flexors of the forearm.

Sensory problem: There is a sensory loss along the lateral side of the forearm. (Lateral cutaneous n of the forearm.)

The Lateral root of the median nerve passes medially to join with similar root from the medial cord to form the Median nerve

Branches of the medial cord

1- The medial pectoral n.

The medial pectoral nerve in our study is a direct branch of the sixth cervical root. It is seen to give numerous branches to the pectoralis minor as it is supplying it. We were unable to study communications between the medial and lateral pectoral nerves. A case has been described wherein the medial pectoral nerve was a direct branch of the anterior division of the middle trunk [10]. We have not found findings similar to us in literature.

2- The medial cutaneous n. of the arm.

3- The medial cutaneous n of the forearm.

4- The median root of median n.

5- The ulnar n.

The medial root of the median nerve passes laterally to joint with similar root from the lateral cord to form the Median nerve.

The Median nerve : (C5,C6,C7,C8,T1), it is originate from the medial and lateral cords of the brachial plexus. It passes into the arm anterior to the brachial artery, then into the forearm behind the flexor digitorum superficialis. In the forearm innervates most of the muscle of the anterior compartment (except flexor carpi ulnaris m and the medial half of the flexor digitorum profundus m. It also gives the palmar cutaneous branch that supplies the skin over the lateral surface of the palm. At the wrist, it emerges from the lateral border of the flexor digitorum superficialis muscle and lies behind the tendon of the palmaris longus muscle. It enters the palm by passing behind the flexor retinaculum. In the hand it supplies the short muscle of the thumb except the adductor pollicis that is supplies by the ulnar nerve and the first and second lumbricals muscles. It is the most important sensory nerve in the hand because it innervates skin of the thumb, index and middle finger, and the lateral side of the ring finger.

Communications between musculocutaneous nerves and median nerves are the most frequent of all the variations observed in the brachial plexus [9].

Injury of the median nerve:

It is most commonly injured near the wrist or high up in the forearm

Low lesions may be caused by cuts in front of the wrist or by carpal dislocation.

Consequences: 1- the patient is unable to abduct the thumb.

2- Sensation is lost over the radial three and a half digits

3- In long- standing cases the thenar eminence is wasted and trophic changes may be seen. The hand looks flattened and “apple like”

The nerve can be also compress in the carpal tunnel: Compression of the median n. at this level produced the Carpal tunnel syndrome. Clinically this syndrome is characterized by: A burning pain or “pin and needles” along of the distribution of the median n. to the lateral three and one half fingers and weakness of the thenar muscles. There is not paresthesia over the tenar region because the palmar cutaneous branch of the median n passes superficially to the flexor retinaculum. High lesions are generally due to forearm fractures or elbow dislocation.

Consequences: The signs are the same as those of low lesions but, in addition, all the pronator muscles of the arm and the long flexor of the wrist and fingers are paralyzed(except flexor carpi ulnaris and medial half of flexor digitorum profundus), then the patient also exhibit the following signs:

a- the forearm is kept in the supine position;

b- Wrist flexion is weak and accompanied by adduction.

c- No flexion is possible at the interphalangeal joints of the index and middle fingers. (When the patient tries to make a fist, the index and to a lesser extend the middle finger tends to remain straight, while the ring and little fingers flexes). Typically the hand is held with the ulnar fingers flexed and the index straight (the 'pointing sign').

d- flexion of the terminal phalanx of the thumb is lost. (Paralysis of the flexor pollicis longus)

The Ulnar nerve