

# Inflammatory Fibrosarcoma: A Rare Tumour Entity Involving Retroperitoneum And Colon

B Murthy, D Mathur, P Hamal, V Modgill

## Citation

B Murthy, D Mathur, P Hamal, V Modgill. *Inflammatory Fibrosarcoma: A Rare Tumour Entity Involving Retroperitoneum And Colon*. The Internet Journal of Oncology. 2004 Volume 2 Number 2.

## Abstract

An inflammatory fibrosarcoma is a rare tumour with a varied biological behaviour, from benign to locally aggressive and occasionally malignant. It generally involves mesentery and retroperitoneal structures, but it rarely can involve the hollow viscera and commonly affects children and young adults.

We report a case of inflammatory fibrosarcoma affecting an unusual age group, involving the ileo-caecal junction and ascending colon (a rare site) causing sub-acute intestinal obstruction. We also discuss its surgical management, differential diagnosis and review of current literature. Only a handful of cases have been reported and to the best of our knowledge none of these were from UK.

## INTRODUCTION

The inflammatory fibrosarcoma entity was first described by Meis & Enzinger in 1991. Tumours of the mesentery, retroperitoneum, and omentum histologically contain fibroblasts, plasma cells, and histiocytes have been reported under different names in the past, including inflammatory pseudotumour, plasma cell granuloma, myofibroblastoma and inflammatory myofibroblastoma. These previous histological reports of intra abdominal lesions have been compared to inflammatory pseudotumour of the lung and their apparent benign behaviour. The similarity extends to the relief of systemic symptoms, including fever, weight loss, and anaemia following surgical removal of the mass<sub>1</sub>. In fact inflammatory fibrosarcomas are locally aggressive, potentially metastasising lesions<sub>2</sub> that may lead to the patient's death and therefore should be designated as sarcomas rather than as cellular inflammatory pseudotumours.

## CASE REPORT

A 72 years old gentleman presented with a 2-day history of generalised pain in the abdomen localized mainly in the right iliac fossa.

He was previously fit and healthy and started with generalised feeling of being unwell for four months, recurrent pain abdomen, bloating sensation, loss of weight

over half a stone and loss of appetite. There was no history of bladder or bowel disturbance, fever, jaundice or vomiting. His pain was worse in the last 2 days associated with nausea.

On clinical examination he appeared anxious and sweaty with mild dehydration. Abdominal examination showed tenderness and guarding in the right iliac fossa with the rest of the abdomen soft and there were no masses palpable. Rectal examination was unremarkable. A possible diagnosis of appendicitis was made.

Haematology showed a white cell count of 17.8 and biochemical investigations were within the normal limits. Chest X-Ray was normal with the abdomen plain film showing stones in the gall bladder and a few dilated small bowel loops. Urgent ultrasound scan of abdomen confirmed a small collection of fluid in the right iliac fossa and gallstones with no gas in the biliary tree.

In view of the uncertain diagnosis a laparotomy was carried out. This revealed a large mass in the right iliac fossa at the ileo-caecal junction. The distal ileum was adhered to caecum and adjacent mesentery with thick pus between the loops of small bowel. Right hemicolectomy and an end to side ileo-transverse anastomosis was fashioned. The postoperative recovery of the patient was uneventful.

The histopathology was initially reported as highly cellular

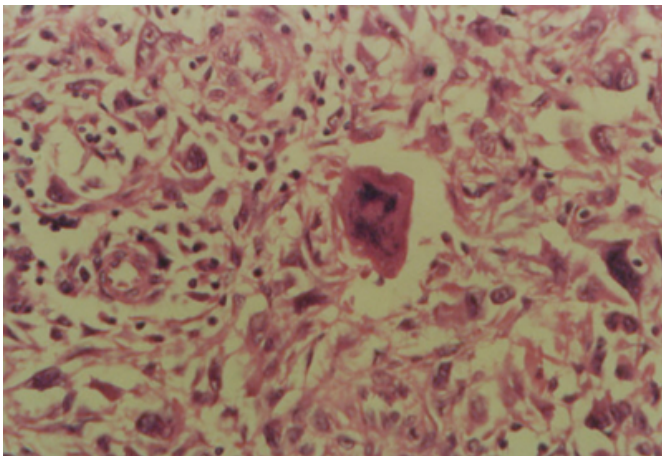
spindle cell tumour, with frequent mitotic activity with the most likely site of origin of tumour being bowel wall and spreading in to the surrounding areas including the mesentery.

Tumour markers SMA, desmin and vimentin (indicative of smooth muscle origin) were positive there by indicating leiomyosarcoma. In view of the positive cytokeratin immunostaining (indicates epithelial origin), a second opinion was sought by pathologists.

A further histological report showed the tumour to have resemblance to an inflammatory pseudo tumour, however the pleomorphism was against. This on final review they concluded infact, was an “Inflammatory fibrosarcoma of the colon” a rare tumour. At this stage the patient was referred to the soft tissue sarcoma team and oncologists.

### Figure 1

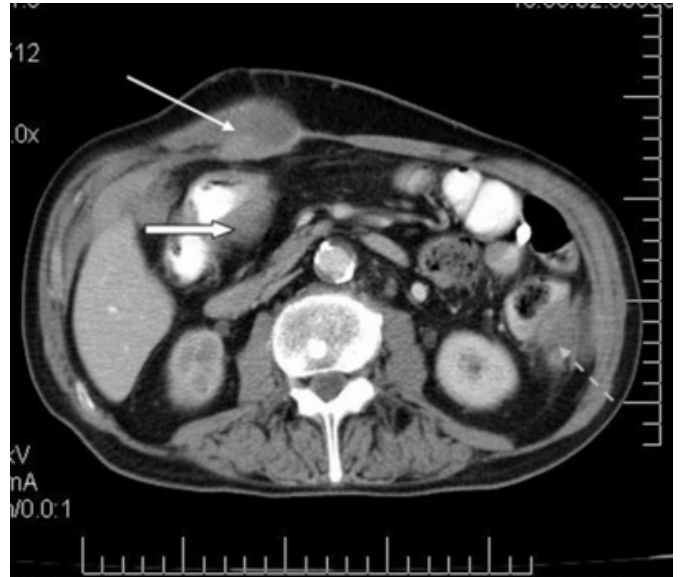Figure 1: This photomicrograph is the true representation of Inflammatory fibrosarcoma with pleomorphic fibroblastic cells including bizarre giant cells and inflammatory cell component (Magnification 10x40).



At 6-weeks a postoperative C T scan showed a small bowel related mass in the pelvis. Further scan after 10 weeks showed increase in the size of the tumour with 3 more masses related to the small bowel, left iliac fossa and right rectus muscle. Liver spleen and pancreas were normal. A small bowel meal performed did not show any bowel tumour or extrinsic compression of the bowel. Patient required further admission with anaemia and needed blood transfusion and eventually succumbed to cachexia 6 months after the initial presentation.

### Figure 2

Figure 2: CT scan of the abdomen taken at 6 weeks postoperatively showing recurrence of the tumour in the right rectus muscle (white arrow), small bowel (solid arrow) and in the left iliac fossa (broken arrow).



### DISCUSSION

Inflammatory fibro sarcoma is generally seen in children and adolescents,(in a retrospective study over 45 years, in the largest series of 38, patients 30 were younger than 21 years). Patients commonly present with non specific symptoms like abdominal pain, anaemia, fever, night sweats, weight loss, mass, abdominal distension, and diarrhoea. Duration of the symptoms can be highly variable ranging from acute onset to years. (In our case it was 4 months)

Most of the tumours involve the mesentery with only a few closely related to gastro intestinal tract and involving transmurally (as in our case). Retro peritoneum is the site of involvement in 87% of cases though the mediastinum and omentum can also be involved. Oesophagus<sub>3</sub> and bone<sub>4</sub> have also been reported as other rare sites. Only two more cases have been reported to involve the colon other than our case in English literature. The biological behaviour of these tumours varies and it is reported that 37% recur locally with 11% multiple local recurrences and 11% distant metastases<sub>1</sub>. It is possible that benign metastasising or multicentric tumours can behave like this however in view of inflammatory fibrosarcoma's potential for local invasiveness and occasional ability to metastasise with consequent mortality it is unlikely that they are similar. Children may have better prognosis than adults, as the biological behaviour is borderline or intermediate.

Histologically immunohistochemical stains for keratin, vimentin, desmin, muscle-specific actin, smooth muscle actin, S-100protein, and KP1 (as in our case) are positive. Differential diagnoses of inflammatory fibrosarcoma are inflammatory pseudotumour, xanthogranuloma, and malignant fibrous histiocytoma. Leiomyosarcoma also closely resembles inflammatory fibrosarcoma, but are easily differentiated by abundant eosinophilic fibrillary cytoplasm, less heavy collagenation, and also by lacking an intense chronic inflammatory component. Inflammatory myofibroblastic tumour and inflammatory fibrosarcoma have many overlapping clinical and pathological features and differ very little, forming different ends of same spectrum.

Suggested treatment for these tumours is complete surgical excision with removal of multiple nodules, if feasible, and close follow up, as several of these tumours do not recur. Invasion or metastases to other sites should be treated by chemo or radiotherapy especially where complete excision is not feasible. Chemo and radiotherapy can also give palliation in dysphagia in oesophageal involvement. Alpha-Interferon has been tried and shown to improve the quality of life in one child.

### **CONCLUSION**

We conclude that inflammatory fibrosarcoma is a very rare tumour affecting all ages and various organs of the body. The clinical presentation and biological behaviour are varied

and pose diagnostic and therapeutic challenge. There is no common agreement on the modality of treatment though surgical excision is the treatment of choice where possible with chemo- radiotherapy or Alpha-Interferon being other options. Each case should be individualised.

### **CORRESPONDENCE TO**

Mr Murthy BL C/o Mr Mathur D, Consultant Surgeon  
Grantham & District Hospital Grantham NG31 8DG Phone:  
01476 565232 bleep 247 e-mail: blmurthy@hotmail.com

### **References**

1. Jeanne M. Meis and Franz M. Enzinger Inflammatory fibrosarcoma of the mesentery and retro peritoneum. The American journal of surgical pathology 15(12): 1146-1156, 1991
2. Coffin CM, Dehner LP and Meis-kindblom JM. Inflammatory myofibroblastic tumour, inflammatory fibrosarcoma and related lesions: an historic review with differential diagnostic considerations seminars in diagnostic pathology. 15 (2): 102-110, 1998 May.
3. Christopher J. Magovern, Charles A. Mack, Mai Gu, Syed Hoda and Nasser K. Altorki. Primary inflammatory fibrosarcoma of the oesophagus. Ann. thorac. surg 1996; 62:1848-50
4. Watanabe K, Tajino T, Sekiguchi M, Suzuki T. Inflammatory myofibroblastic tumour (inflammatory fibrosarcoma) of the bone. Archives of Pathology & Laboratory medicine. 124(10): 1514-7, 2000 Oct.
5. Caroline M Hamm, Allan Pyesmany and Lothar Resh; Congenital retroperitoneal fibrosarcoma. Medical & Paediatric oncology. 28: 65-68. 1997
6. Conte M, Milanaccio C, Nantron M, Castgnola E. Multiple inflammatory fibrosarcoma of the abdominal cavity in a child Medical & Paediatric Oncology. 27 (3): 198-201, 1996 Sep.

**Author Information**

**B.L. Murthy**

Departments of Surgery and Pathology, Grantham & District Hospital

**D. Mathur**

Departments of Surgery and Pathology, Grantham & District Hospital

**P.B. Hamal**

Departments of Surgery and Pathology, Calderdale Royal Hospital

**V.K. Modgill**

Departments of Surgery and Pathology, Calderdale Royal Hospital