

Congenital Chylous Ascites: A Diagnostic Dilemma For The Obstetrician

N Malhotra, C Chanana, S Kumar, P Gupta

Citation

N Malhotra, C Chanana, S Kumar, P Gupta. *Congenital Chylous Ascites: A Diagnostic Dilemma For The Obstetrician*. The Internet Journal of Gynecology and Obstetrics. 2005 Volume 6 Number 1.

Abstract

Congenital chylous ascites is a rare but vexing clinical problem. Antenatal diagnosis is difficult due to the non-specific nature of presentation namely abdominal distension. Congenital chylous ascites is caused by disruption of abdominal lymphatics. Treatment modalities may be medical or surgical. We present a case of congenital chylous ascites with successful management.

INTRODUCTION

Chylous ascites is an uncommon but vexing clinical problem associated with the disruption of abdominal lymphatics. It has a wide spectrum of etiologies including abdominal surgeries, neoplasms and trauma. Congenital chylous ascites in the neonatal period is primarily related to congenital abnormalities of lymphatics. A condition called 'leaky lymphatics' was suggested and delayed maturation of the lacteals was thought to be the underlying mechanism. A fairly well-defined algorithm for the treatment of chylous ascites has evolved over the last several decades. These treatment methods include high protein, low fat diets with medium chain triglycerides, diuretics, use of total parenteral nutrition (TPN), repeated paracentesis, surgical exploration and internal shunting. However, none of these techniques have resulted in uniform success, and there are still mortalities from the condition. We present a case of congenital chylous ascites with successful antenatal, intrapartum and postnatal management.

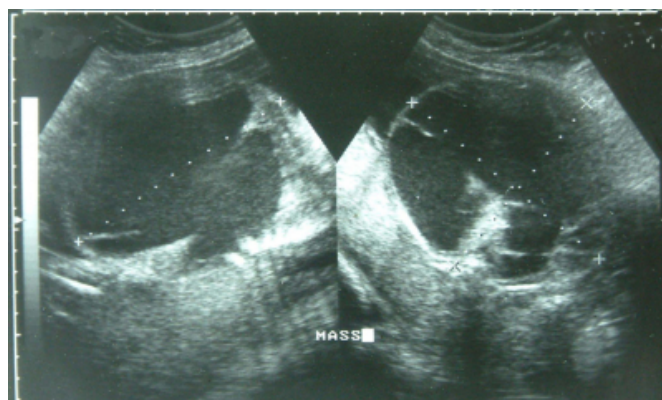
CASE REPORT

Mrs. X, a 29 years old third gravida with spontaneous conception was referred to us at 22 weeks gestation after an ultrasound scan suggesting an intra-abdominal cystic collection in the fetus. Her previous two pregnancies were uncomplicated, both resulting in healthy babies aged 4 and 2 years. A detailed anomaly scan was repeated by us. It revealed a single live fetus with a normal spine and intracranial details. The stomach and bladder shadows were visualized and limbs appeared normal. The only abnormality detected was a huge homogenous mass with uniform echo

texture occupying almost the entire fetal abdomen (Fig1).

Figure 1

Figure 1: Antenatal ultrasound showing massive collection in fetal abdomen



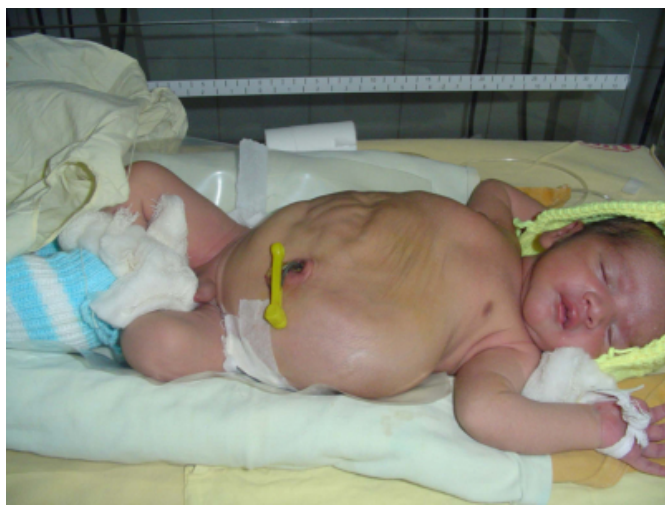There were no other features suggestive of hydrops. Since the fetus was a male the possibility of an ovarian cyst was excluded from the diagnosis. A differential diagnosis of mesenteric cyst, retroperitoneal collection, distended bladder, hydroureteronephrosis and loculated ascites were considered. The patient was then subjected to investigations, namely TORCH, VDRL, Parvovirus screening and GTT which were all normal. Fetal echo revealed a normal 4-chamber heart. A paracentesis was performed and the aspirated fluid was sent for biochemical examination and cytology. This revealed the fluid to be of a nonspecific nature. The patient was followed up with serial ultrasounds and the fetal abdomen was found to fill up again. A repeat paracentesis was planned and 1.5 l of fluid was drained. The patient was then 30 weeks. With the aim to prevent

pulmonary hypoplasia and ensure expansion of lungs at birth, fluid was drained from fetal abdomen once again at 34 weeks and 1 l of fluid was removed.

The patient went into spontaneous labour in the 37th week. During the intrapartum period 1 l of fluid was drained from the fetal peritoneal cavity to prevent difficult/obstructed labour. The course of labour was otherwise uneventful and a male baby of 3 kilograms with a massively distended abdomen and an Apgar score of 8 & 9 at 1&5 minutes respectively was born. (Fig. 2)

Figure 2

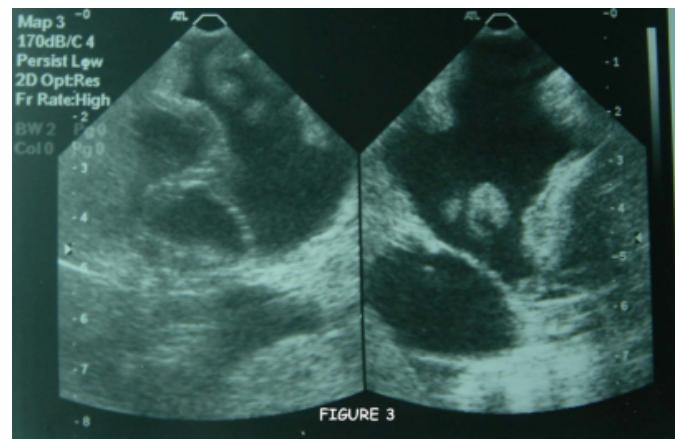
Figure 2: Picture of baby at birth showing abdominal distension



In the postnatal period the baby underwent ultrasound (Fig. 3) and CT scans and a diagnosis of “mesenteric cyst or retroperitoneal cyst or loculated ascites” was made. An aspiration was also done and report of which was non-specific. However, when a repeat paracentesis was done after starting the baby on oral feeds a white colored fluid was obtained. Biochemical examination revealed triglyceride levels of 957mg/dl. Finally a diagnosis of congenital chylous ascites was made. The baby was started on high protein, medium chain triglyceride and underwent paracentesis twice thereafter. The ascites began to resolve spontaneously and disappeared in 6 weeks. The baby has been on follow-up for 1 year and there has been no recurrence. He has a normal growth pattern and is on a normal diet.

Figure 3

Figure 3: Postnatal ultrasound of the baby



DISCUSSION

Chylous ascites is not a primary process but rather a manifestation of an underlying disorder. These pre-disposing disorders can be divided into three basic categories: trauma, obstruction and lymphatic abnormalities. Congenital abnormalities of the lymphatic channels are the main cause of chylous ascites in infancy (1, 2). In about 50% of case in neonates, no known causes such as trauma, lymphatic obstruction, lymphangiomatosis or atresia of the lymphatic system can be documented. For such situation the term “leaky lymphatic” has been used (3). In this syndrome ascites is thought to be due to delayed maturation of the lacteals such that chyle which may leak into the peritoneal cavity. Another theory suggests that hypoplasia of a portion of the lymphatic vessels creates an obstruction and permits chyle leakage. With time, collaterals develop or there is maturation of the lacteals, and leakage resolves.

Congenital chylous ascites has a slight predilection for males. The male to female ratio being 1.08:1. The presenting symptoms of chylous ascites are related primarily to abdominal distension. Respiratory distress can also occur during the course of disease as can vomiting and diarrhea. Our case was unique in its presentation as our patient has massive ascites before birth which did not resolve despite repeated paracentesis. Lymphopenia thought to be secondary to sequestration of lymphocytes in the chylous fluid and hypo-proteinemia due to third space losses are the most frequently encountered laboratory abnormalities.

Due to the non-specific nature of presentation-abdominal distension a wide variety of differential diagnosis were considered both in the antenatal and postnatal period. The diagnosis of a mesenteric cyst, loculated ascites, distended

bladder, hydronephrosis, retroperitoneal mass were all considered. Congenital chylous ascites was finally diagnosed when after about 5 days of oral feeding a paracentesis showed an increased triglyceride level.

Treatment of such infants comprises strategies to

- improve and/or maintain nutritional status. A malnutrition often ensues due to early satiety, vomiting from abdominal distension and sequestration of fatty acids and proteins.
- decrease the rate of formation of chyle
- correct the underlying disorder.

Before resorting to surgical line of management a more conservative approach is advocated. The use of medium chain triglycerides has been attempted because they can be absorbed directly in the portal system rather than lymphatics (⁴). Alliet & colleagues (⁵) have advocated the use of medium chain triglycerides till at least 10 weeks before labeling therapy as ineffective. Another treatment modality is total parenteral nutrition (TPN) (^{6, 7}) which allows the patient to be nil per oral to decrease the rate of chyle formation while not compromising nutrition.

Our patient also responded to this conservative approach. The baby received special high protein, medium TG feeds for 6 weeks and underwent paracentesis as a consequence of which he developed peritonitis for which he received antibiotics. The baby has been on follow-up for 1 year and there has been no recurrent ascites.

We would like to point out that congenital chylous ascites though rare should be kept in mind as a possibility if the fetus presents with isolated distension of the abdomen with nonspecific results on cytology and biochemical examination. Repeat paracentesis of fetal ascites may help in reducing maternal respiratory distress and may also enhance fetal lung maturity as lungs may expand better. Also aspiration of fluid from fetal abdomen reduces the risk of preterm labour. A definite diagnosis can be made only after birth when the baby has been started on oral feeds.

CORRESPONDENCE TO

Dr Charu Chanana 91, pocket B, Sukhdev Vihar, New Delhi, India e-mail: charuchanana@rediffmail.com
Phone-91+9810482629

References

1. McKendry JBJ, Lindsay WK, Gerstein MC Congenital defects of the lymphatics in infancy. *Pediatrics* 1957; 19:21-34
2. Smeltzer DM, Stickler GB, Fleming RE Primary lymphatic dysplasia in children: Chylothorax, chylous ascites and generalized lymphatic dysplasia. *Eur J Pediatr* 1986;145:286-292
3. Strumer FC Infantile chylous ascites: review of literature and case report. *Am Surg* 1965; 31:281-284
4. Cochran WJ, Klish WJ, Brown MR, Lyons JM, Curtis T Chylous ascites in infants and children: a case report and literature review. *J Pediatr Gastroenterol Nutr* 1985;4: 668-673
5. Alliet P, Young C, Lebenhol E. Chylous ascites: total parenteral nutrition as a primary therapeutic modality. *Eur J Pediatr* 1992;151:213-214
6. Asch MJ, Sherman NJ. Management of refractory chylous ascites by total parenteral nutrition. *J Pediatr* 1979;94:260-262
7. Bach AC, Babayan VK. Medium chain triglycerides :an update. *Am J Clin Nutr* 1982;36:950-962

Author Information

Neena Malhotra

Associate Professor, Department of Gynecology and Obstetrics, All India Institute of Medical Sciences

Charu Chanana

Registrar, Department of Gynecology and Obstetrics, All India Institute of Medical Sciences

Sunesh Kumar

Professor, Department of Gynecology and Obstetrics, All India Institute of Medical Sciences

Prerna Gupta

Junior Resident, Department of Gynecology and Obstetrics, All India Institute of Medical Sciences