

Adult Aural Foreign Bodies

C Ryan, A Ghosh, D Smit, B Wilson-Boyd, S O'Leary

Citation

C Ryan, A Ghosh, D Smit, B Wilson-Boyd, S O'Leary. *Adult Aural Foreign Bodies*. The Internet Journal of Otorhinolaryngology. 2005 Volume 4 Number 2.

Abstract

Objective: To compare types of aural foreign objects between adults and children presenting at two Australian Emergency Departments.

Methods: Retrospective chart review of 194 patients attending a tertiary ENT centre and 136 patients at a General Emergency Department in Victoria, Australia with aural foreign bodies was conducted.

Results: Three hundred and thirty patients were included. The commoner foreign bodies in children were beads, cotton tips, insects and paper, and in adults cotton tips, insects and silicone ear plugs. Flying insects were more common than cockroaches in Australia. Children were significantly more likely to have initially been seen by their family doctor than adults ($p < 0.01$) and to have required general anaesthetic for removal of the object(s) ($p < 0.001$).

Conclusions: Aural foreign bodies are frequent. Recognizing patients requiring early specialist review is important. Adults aural foreign bodies differ from children. Cotton tips and silicone ear plugs are not harmless.

INTRODUCTION

Foreign bodies in the external auditory canal are a frequent and challenging presentation to emergency departments and often require referral to an otorhinolaryngology unit. The profile of foreign bodies in children's ears has been reported from a number of countries, however the adult experience is not well documented ^{1,2,3,4,5,6,7,8,9}.

The Royal Victorian Eye and Ear Hospital (RVEEH) offers a 24 hour Otorhinolaryngology Head and Neck and Ophthalmology emergency department which is open to the general public and provides immediate specialist care.

The Emergency Department of the Bendigo Health Care Group (BHCG) is a major regional referral organization in rural Victoria (The Loddon Campaspe Region) with a current annual attendance of 32000 per annum (20% paediatric) that provides a 24 hour service to the general public and availability of out of hours otolaryngological specialist care.

This study compares the paediatric and adult experience over a period of nine years and describes the immediate evaluation and further management of aural foreign bodies.

METHODS

Patients presenting to the emergency department with the complaint of aural foreign body during 2003 at the RVEEH and between 1996 and 2004 at the BHCG were included in this study.

Their charts were retrospectively reviewed and the quality of data collated ensured by strictly adhering to the Australian College of Emergency Medicine guidelines on chart reviewing.¹⁰

The study group was identified using Pickware Software, Nested Database to list all ED presentations with ICD 10 codes H60 – H62 from 1/1/1996 to 31/12/2004 at the The Bendigo Hospital (TBH). Patients attending the RVEEH in 2003 were identified using data collected using iSOFT PiMS and coded as foreign body removal from ear (VMD Code 116).

A preliminary review of 30 charts from each hospital was undertaken to determine if the desired data was being obtained and to identify any potential difficulties. A data collection form was then developed. As the amount of variables were minimal and the study was simple, charts

were not assigned to external abstractors and were kept to the two principal authors.

The age of 18 years (age of consent) was used as the division between paediatric and adult populations. Statistics were performed using Chi-square and t-tests with $p < 0.05$ considered statistically significant.

RESULTS

Three hundred and thirty patients presented to the two Emergency Departments with a foreign body in the external ear canal. This included 113 (34%) children and 217 (66%) adults. Patient demographics are shown in Table 1.

Figure 1

Table 1: Patient demographics (% in brackets)

		RVEEH	TBH	TOTAL
Paediatric:		70	43	113
Age		2 – 17 yrs mean 7.5	0.25 - 17 yrs mean 6.9	
Sex	Male	42 (60)	18 (42)	60(53)
	Female	28 (40)	25 (58)	53(47)
Side	Right	38 (54)	19(44)	57(50)
	Left	29 (42)	22(51)	51(46)
	Bilateral	3 (4)	2 (5)	5 (4)
		RVEEH	BHCG	TOTAL
Adult:		124	93	217
Age		18 – 90 yrs mean 42.9	18 - 86 yrs mean 41.7	
Sex	Male	75 (60)	53 (57)	128(60)
	Female	49 (40)	40 (43)	89 (40)
Side	Right	58 (47)	48 (52)	106(49)
	Left	61 (49)	39 (42)	100(46)
	Bilateral	5 (4)	6 (6)	11 (5)

The most common foreign bodies in children were beads, cotton tips, insects and paper, compared with adults where cotton tips, insects and silicone ear plugs predominated (Table 2). Inner city and rural populations showed similar patterns of presentation. Teenagers demonstrated a similar profile to the adult population rather than to that of younger children. All insects were flying species (eg moth, flies, flying beetles) other than one adult patient with a small cockroach in the ear.

Figure 2

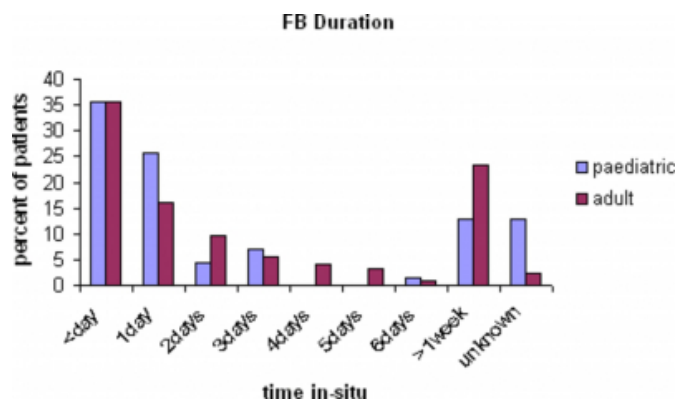
Table 2: (% in brackets)

Paediatric	RVEEH	TBH	TOTAL	Adult	RVEEH	TBH	TOTAL
Bead	19(27)	3 (7)	22 (19)	Cotton tip	54 (44)	22 (24)	76 (35)
Cotton tip	5 (7)	9(21)	14 (12)	Insect	20 (23)	26 (28)	46 (21)
Insect	6 (9)	6(14)	12 (9)	Silicone plug	15 (12)	5 (5)	20 (9)
Paper	8 (11)	1(2)	9 (8)	Cotton wool	7 (6)	12 (13)	19 (9)
Crayon	5 (7)	1(2)	6 (5)	Paper	5 (4)	6 (6)	11 (5)
Wood	2(3)	4 (9)	6 (5)	Plastic	8 (6)	3 (3)	11 (5)
Silicone plug	5 (7)	0	5 (4)	Hair	3 (2)	4 (4)	7 (3)
Stone	3 (4)	2(5)	5 (4)	Wood	3 (2)	3 (3)	6 (3)
Vegetable	5 (7)	0	5 (4)	Metal	1 (1)	5 (5)	6 (6)
Metal	3 (4)	1(2)	4 (4)	Grass seed	4 (3)	1 (1)	5 (2)
Plastic	2 (3)	2 (5)	4 (4)	Rubber	1 (1)	2 (2)	3 (1)
Putty	3 (4)	0	3 (3)	Pencil lead	0	2 (2)	2 (1)
Sweet	1 (1)	1(2)	2 (2)	Stone	1 (1)	1 (1)	2 (1)
Pencil lead	1 (1)	1(2)	2 (2)	Candle wax	1 (1)	0	1 (0.5)
Sponge	1 (1)	0	1 (1)	Sponge	0	1 (1)	1 (0.5)
Shell	1 (1)	0	1 (1)	Sweet	1 (1)	0	1 (0.5)

Most patients were seen on the same day as the foreign body insertion, however adults tended to leave the objects longer than children, some being present for many months (Figure 1).

Figure 3

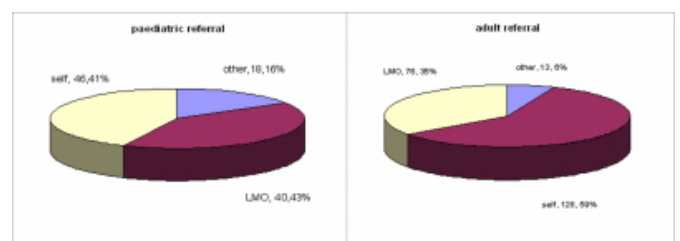
Figure 1



Children were more likely to have been taken to their Local Medical Officer (LMO) prior to attending casualty whereas adults were more often seen as self referrals ($p < 0.01$) (Figure 2). Other referral sources included other hospital emergency departments, private otorhinolaryngology specialists and audiologists.

Figure 4

Figure 2



Most adults required no anaesthesia for removal of the foreign body. In contrast children were frequently unable or unwilling to cooperate with removal awake and needed

general anaesthesia ($p<0.001$). Local anaesthetic was infrequently used and sedation without anaesthesia was never employed (Table 3).

Figure 5

Table 3: Type of anaesthesia for FB removal

	General			Local			Nil		
	REEVH	TBH	TOTAL	REEVH	TBH	TOTAL	REEVH	TBH	TOTAL
Paed	22(31%)	15(39%)	37 (33%)	0	3 (7%)	3 (3%)	48 (69%)	25(58%)	73 (65%)
Adult	2 (2%)	1 (1%)	3 (1%)	3 (2%)	2 (2%)	5 (2%)	119(96%)	90 (97%)	209 (96%)

$P<0.001$

The time taken to proceed from initial presentation to general anaesthetic (GA) removal in children was 5 days or less except in one case. This child waited a month due to family circumstances. Of the 2 adults needing GA, one occurred after 2 days and the other after 16 days. No adverse outcomes could be attributed to a delay in removal. The age of children requiring GA was 2-17 years with a mean of 5.7 years. This was not significantly different from the overall paediatric population ($p>0.05$).

No significant complications of foreign body presence or removal (eg tympanic membrane perforation or ossicular chain disruption) were encountered in this series. Those seen included minor tympanic membrane or external canal lacerations and mild otitis externa or canal wall inflammation (Table 4).

Figure 6

Table 4: Complications of FB insertion and/or removal

Paediatric:		REEVH	TBH	TOTAL
	Nil	55 (79%)	28(65%)	83 (73%)
	TM laceration	4	2	6
	EAC laceration	6	10	16
	Otitis externa	5	3	8
Adult:				
	Nil	100 (81%)	57(61%)	157(72%)
	TM laceration	2	1	3
	EAC laceration	7	15	22
	Otitis externa	15	20	35

DISCUSSION

Aural foreign bodies are usually perceived as primarily a paediatric emergency presentation. The Royal Victorian Eye and Ear Hospital and The Bendigo Base Hospital treat patients of any age, however the majority are adults and this is reflected in the age range seen in this series. It is important to consider the possibility of a foreign body in the adult ear particularly in the setting of blockage, pain and otorrhoea.

The type of foreign body found in the paediatric ear canal has been variously reported around the world. The most common findings include those by Ijaduola et al 1986

(Nigeria)₁ with equal prevalence of vegetable and inorganic matter, Baker 1987 (US)₂ cockroaches and paper, Bressler et al 1993 (US)₃ cockroaches, Ansley et al 1998 (US)₄ beads, plastic toys, pebbles and insects including cockroaches, Balbani et al 1998 (Brazil)₅ beans and small round objects, Mishra et al 2000 (India)₆ inanimate non-vegetative foreign bodies, Hon et al 2001 (Malaysia)₇ wooden beads, DiMuzio et al 2002 (US)₈ beads and Schulze et al 2002 (US)₉ beads, paper, popcorn kernels and insects. The current series confirms that a wide variety of objects may be found in a child's ear particularly beads, paper and insects. It is, however, unusual in Victoria, Australia to encounter cockroaches in the external ear. Insects of a flying variety were found in the vast majority of cases.

Most reports of foreign bodies in the ears of adults have consisted of isolated, interesting cases. Unpublished data from the John Hopkins emergency department (US) 1987 found that the most common aetiology in adults (85% in 106 patients) was accidental entry of insects, 50% of these being cockroaches₁₁. Bressler et al (US) 1993 also found cockroaches to be the most common foreign body amongst 98 patients, although they did not differentiate between adult and paediatric groups₃. Antonelli et al (US) similarly report beads and insects, particularly cockroaches, to be the commonest foreign bodies in the external auditory canal from 273 combined paediatric and adult patients₁₂. Our experience was different from these series. We found the majority of foreign bodies in adult patients to be the cotton wool tips of cotton buds. These are frequently used by the general population for cleaning or itching of the external ear canal. Das 1984 reported that the commonest aetiological factor for foreign body insertion into the ear in a paediatric population was irritation, such as caused by otitis externa, chronic suppurative otitis media or wax in the meatus₁₃. This would also appear to play a major role in adults. Although no significant complications were observed in this series, the use of cotton buds in the external auditory canal should be discouraged and this warning can now be found on some brands of cotton buds.

In the Australian population we frequently observe retained silicone ear plugs, either in their entirety or part thereof. This is most often seen in teenagers or adults. These plugs are readily available for purchase and are primarily used to prevent water entering the canal during swimming or bathing. Unfortunately their removal can be problematic. Patients can find that the plug has embedded itself too deep in the canal for digital removal or that the plug breaks on

attempted removal leaving some retained material. The plugs are clear and sometimes not recognised by untrained eyes. Their consistency is soft particularly after multiple attempts at syringing the ear or if the plug has been left in the canal for a long period of time. This makes suction, forceps, hooks and curettes all less than ideal instruments and often necessitates piecemeal removal which is both time consuming and uncomfortable for the patient. Fortunately general anaesthesia is rarely required in the age range concerned. Of further note is the fact that silicone putty ear plugs were the only form of commercial plugs to present as an aural foreign body suggesting that the use of alternative varieties may be more desirable.

There was a high requirement for general anaesthesia amongst our paediatric patients (37/113, 33%). To some extent this reflects the fact that adults are more commonly seen particularly at RVEEH and the lack of trained staff for the administration of paediatric sedation. Parent and physician tolerance for child restraint is also likely to differ from other areas of the world. Reported rates for removal under GA in paediatric series of aural foreign bodies include Schulze 2002 10.3%, Mishra 2000 13.1%, Balbani 1998 8.6%, Ansley 1998 30%, and Baker 1987 0.7%. Only two adults required general anaesthesia. One was a 33 year old woman with learning difficulties who had melted candle wax throughout the canal. Numerous attempts at softening and piecemeal removal failed and the decision was made to proceed to GA. The other was a 50 year old woman with the plastic end of her glasses embedded in the canal wall. This may well have been removed using local anaesthetic techniques and we have tended to underutilise this excellent aid to removal.

Most aural foreign bodies are seen within twenty four hours of insertion both in cases of self referral and when sent from other sources. However it is not unusual for an object which is not causing significant symptoms to remain in the canal for a long period of time. Unless observed at the time of onset children may not notice the foreign body or fear reprisal and adults are often embarrassed or unconcerned about the object. This did not result in complications in this series however it can make removal more difficult. Patients should be encouraged to attend for medical removal at an early stage, particularly in the case of vegetative or animate foreign body. The urgency for removal can then be tailored according to the object present.

It was not possible from this review to ascertain the exact method of foreign body removal for each case. Syringing of

the external auditory canal by the referring practitioner had frequently occurred prior to presentation to our departments. This technique is not practised in the specialist setting with the availability of magnified direct vision, microscopy, suction and specialised instrumentation. Although often successful for inorganic material, syringing must be practised cautiously, particularly in the presence of irregular objects which may harm the tympanic membrane or organic material which may expand, irritating the canal and making later extraction difficult. We did not observe any complications from syringing with water in this series other than occasional mild otitis externa. Insects are usually killed prior to removal, using mineral oil or aqueous lignocaine¹¹. This relieves patient symptoms and facilitates removal. All patients referred from an external source had had the insect rapidly and successfully killed prior to presentation although this was frequently not the case in self referred patients. Although not seen in this review, alkaline batteries present a special case requiring urgent referral. Liquifactive necrosis may result from irrigation or bleeding and rapid removal under ideal conditions is needed⁴. Also not encountered in this series were substances such as superglue or chewing gum. These are not urgent presentations but are frequently difficult to remove without causing trauma and significant patient discomfort. The successful use of acetone and hydrogen peroxide has been reported in these situations^{14,15}.

CONCLUSION

Foreign bodies are common in both the paediatric and adult external auditory canal, with the nature of the objects differing between the two groups and between countries. They can potentially be associated with significant complications and at times require skilled recognition and removal. The majority can be extracted in the emergency or outpatient setting, with very few adults requiring general anaesthesia. Silicone ear plugs embedded in the external ear canal will usually require referral to ENT for removal.

CORRESPONDENCE TO

Dr A. N. Ghosh 5/14 Michelsen Street Bendigo Victoria
3550 Australia angaj2004@yahoo.co.nz Tel: +61 3 5444
0516 Fax: +61 3 54548111 (FAO Dr Angaj Ghosh)

References

1. Ijaduola TA, Okeowo PA. Foreign body in the ear and its importance: the Nigerian experience. *Journal of Tropical Pediatrics*. 1986; 32: 4-6
2. Baker MD. Foreign bodies of the ears and nose in childhood. *Pediatric Emergency Care*. 1987; 3: 67-70
3. Bressler K, Shelton C. Ear foreign-body removal: A review of 98 consecutive cases. *Laryngoscope*. 1993; 103:

367-370

4. Ansley JF, Cunningham MJ. Treatment of aural foreign bodies in children. *Pediatrics*. 1998; 101: 638-641
5. Balbani APS, Sanchez TG, Butugan O, Kii MA, Angelico FV, Ikino W, D'Antonio WEP. Ear and nose foreign body removal in children. *International Journal of Pediatric Otorhinolaryngology*. 1998; 46: 37-42
6. Mishra A, Shukla GK, Bhatia N. Aural foreign bodies. *Indian Journal of Pediatrics*. 2000; 67: 267-269
7. Hon SK, Izam TM, Koay CB, Razi A. A prospective evaluation of foreign bodies presenting to the Ear, Nose and Throat Clinic, Hospital Kuala Lumpur. *Med J Malaysia*. 2001; 56: 463-470
8. DiMuzio J, Deschler DG. Emergency department management of foreign bodies of the external auditory canal in children. *Otology and Neurotology*. 2002; 23: 473-475
9. Schulze SL, Kerschner J, Beste D. Pediatric external auditory canal foreign bodies: A review of 698 cases. *Otolaryngol Head Neck Surg* 2002; 127: 73-78
10. Training and Examination Handbook, Australasian College for Emergency Medicine. Chart Reviews - Improving the quality of data. January 2005; 65 -66
11. Fritz S, Kelen GD, Sivertson KT. Foreign bodies of the external auditory canal. *Emergency Medicine Clinics of North America*. 1987; 5(2): 183-192
12. Antonelli PJ, Ahmadi A, Prevatt A. Insecticidal activity of common reagents for insect foreign bodies of the ear. *Laryngoscope*. 2001; 111: 15-20
13. Das SK. Aetiological evaluation of foreign bodies in the ear and nose. (A clinical study). *Journal of Laryngology and Otology*. 1984; 98: 989-991
14. Persaud R. A novel approach to the removal of superglue from the ear. *Journal of Laryngology and Otology*. 2001; 115: 901-902
15. Chisholm EJ, Barber-Craig H, Farrell R. Chewing gum removal from the ear using acetone. *Journal of Laryngology and Otology*. 2003; 117: 325.

Author Information

Caroline Ryan, MRCS

The Royal Victorian Eye and Ear Hospital

Angajendra Ghosh, MRCS

ACEM Trainee, The Bendigo Hospital

De Villiers Smit, FACEM

Director of Emergency Training, The Bendigo Hospital

Brian Wilson-Boyd, FRACS

The Royal Victorian Eye and Ear Hospital

Stephen O'Leary, FRACS

The Royal Victorian Eye and Ear Hospital