

# Remifentanyl For A High Risk Patient

M Mirkov

## Citation

M Mirkov. *Remifentanyl For A High Risk Patient*. The Internet Journal of Anesthesiology. 2001 Volume 6 Number 1.

## Abstract

The commonly used opiates have limitations like accumulation, unpredictable metabolism, active metabolites and unwanted side effects, like vasodilation, respiratory depression, GI-motility depression and confusion. Their clearance from the body is organ dependent - morphine clearance depends on kidney and that of fentanyl on liver function, respectively. Remifentanyl, a new and novel opiate is a selective  $\mu$  agonist with uniquely predictable effects and organ independent metabolism [ 1, 2 ]. Generally there is no accumulation of drug or metabolites after it's use. It's major metabolite G1 90291, around 4000 times weaker than the parental drug, did accumulated after prolonged use in a group of patients with severe renal failure, but without clinical implications [ 3 ]. Remifentanyl is considered a potent tool in the operating theatre and recently in ICU setting as well [ 3, 4 ]. We would like to present the use of Remifentanyl as a component of total intravenous anesthetic technique for a high-risk patient.

## CASE REPORT

A forty-five year old gentleman was presented for left lower limb above knee amputation and extensive surgical debridement of scrotal and penile skin gangrene. He had a body weight of around 60 kilograms and was diabetic on insulin treatment since 25 years. He was also hypertensive on treatment for the last 15 years. He had ischemic heart disease. In January of 2001, he survived an acute antero-septal myocardial infarction. According to the transthoracic echocardiography performed in September of 2001 he had antero-septal hypokinesia and systolic ejection fraction of 40%. His chronic renal impairment progressed to anuria requiring introduction of regular continuous peritoneal dialysis since January of 2001. He had diffuse micro and macroangiopathy with big vessel hypercalcinosis. The angiography, magnetic resonance imaging and Doppler studies found 50% stenosis of his right deep femoral artery and 40% stenosis of his left iliac arterial trifurcation. He underwent surgical brachio-cubital bypass for severe right arm ischemia a year before the presentation. His right third and forth fingers were already amputated. The patient had undergone left lower fore foot amputation, followed by below knee amputation, 3 weeks before the presentation.

Unfortunately the stump developed wet gangrene. He had progressing skin necrosis over his scrotum and penis, which unfortunately led to wet gangrene. The rest of his fingers and the toes of his right leg were gangrenous as well. He had bedsores over the sacral area. In the past he had laser

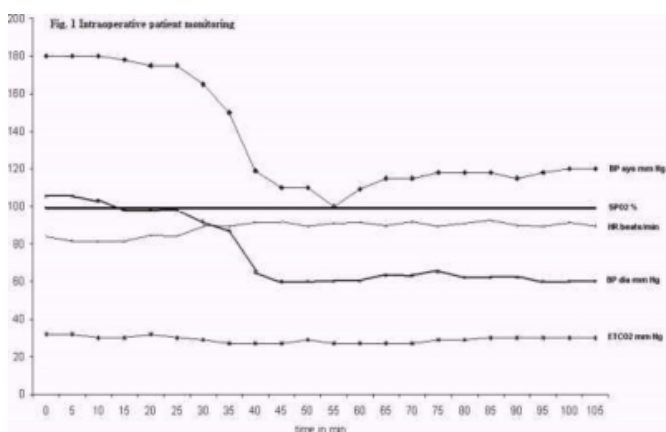
photocoagulation for diabetic retinopathy led to severe reduction of his visual acuity. He had been inpatient for the last five months. Three days before the procedure he was admitted from the nephrology unit to our intensive care unit for treating his sepsis complicated by acute left ventricular failure and relative fluid overload. When presented for surgery, the patient was bedridden and in poor general condition. He was conscious but drowsy, looking older than his age. His skin was gray in color with multiple lesions. The laboratory results showed hemoglobin level of  $11.7 \text{ g.dl}^{-1}$ ; increased white cells count –  $17.29 \times 10^3$ ; high serum urea –  $18.5 \text{ mmol.l}^{-1}$  and creatinine –  $483 \mu\text{mol.l}^{-1}$  levels; slightly prolonged INR – 1.2 and APTT – 50/31 seconds. He had low total serum protein –  $43 \text{ g.l}^{-1}$  and albumin  $13 \text{ g.l}^{-1}$  levels. The serum levels of alkaline phosphatase – 472 IU and glutamyl transpeptidase – 197 IU were increased. Considered to be ASA V, he had no premedication and a high-risk consent for the proposed procedure and anesthesia was taken.

Upon arrival in the theatre a central venous line was initially inserted. After preoxygenation, the patient was induced by intravenous infusions of Propofol  $4 \text{ mg.kg}^{-1}.\text{h}^{-1}$  to a total of 60 mg. and Remifentanyl  $0.1 \mu\text{g. kg}^{-1}.\text{min}^{-1}$  to a total of 30  $\mu\text{g}$ . Cisatracurium 10 mg was used to facilitate the endotracheal intubation. A nasogastric tube was inserted. Anesthesia was maintained by intravenous infusions of Propofol  $3 \text{ mg.kg}^{-1}.\text{h}^{-1}$  to a total dose of 380 mg, and Remifentanyl  $0.2 \mu\text{g. kg}^{-1}.\text{min}^{-1}$  to a total dose of 1320  $\mu\text{g}$ .

The patient was ventilated with 50% oxygen in air, via circle circuit with carbon dioxide absorption and 3 l.min<sup>-1</sup> fresh gas flow. Thirty minutes from the start of the anesthesia he received 50 mg Tramadol intravenously for eventual postoperative pain control. The procedure lasted around 110 minutes. We didn't use more Cisatracurium and didn't reverse it at the end. Around 200 ml of 0.9% normal saline and 250 ml of colloid - Haessteril 6%, were infused as intravenous fluid replacement throughout. Our monitoring included noninvasive blood pressure, ECG, pulse oximetry, central venous pressure. The end tidal concentration of carbon dioxide, the tidal and minute volumes and the respiratory rate were also monitored continuously (Fig. 1). His heart rate remained between 80 – 90 beats.min<sup>-1</sup> throughout. There was no change in the ST segment continuously monitored on the ECG monitor. Although measured 120/60 mm Hg in the ward, his blood pressure upon arrival in the theatre and before the induction was 180/100 mm Hg and remained in the same range for the next 30 minutes. Afterwards it started to decrease and stabilized at a level of 115/60 to 120/60 mm Hg for the rest of the procedure. Two separate intravenous doses of Ephedrine 9 mg were used. His oxygen saturation remained 100% and the end tidal carbon dioxide level was between 30 – 32 mm Hg throughout. The central venous pressure checked twice was 13 cm of water ( 9.5 mm Hg ).

### Figure 1

Figure 1: Intraoperative hemodynamics



The patient had smooth recovery and 10-12 minutes after the discontinuation of Propofol and Remifentanil infusions he was extubated and shifted to our high dependency unit ( HDU ) for postoperative monitoring and care. There he received another 250 ml of Haessteril 6%. Six hours later the laboratory report showed hemoglobin level of 8.6 g.dl<sup>-1</sup> and a pint of packed red blood cells was transfused. The patient

didn't show signs of new myocardial ischemia. His electrocardiogram and the serum levels of “cardiac enzymes” – lactate dehydrogenase, creatinphosphokynase myocardial band and troponin didn't change, when followed for 72 hours postoperatively. He didn't require any more pain control until the next morning, almost 20 hours postoperatively, when he was feeling pain from the scrotal and penile wounds. After 24 hours in the HDU without change in the general condition, with adequate oxygenation and stable circulation he was discharged to a surgical ward.

There he continued to be on regular peritoneal dialysis, his regular medications and wound dressings. His wounds showed poor healing. He remained very tired, bedridden, suffering of pain and discomfort. Unfortunately, 20 days later the patient expired on his bed, presenting a picture of acute left ventricular failure not responding to the treatment and the eventual resuscitation, when he arrested.

## DISCUSSION

To deal with septic patients presented for surgery is always a challenge. Our patient was a case with a history of long lasting diabetes, end stage renal failure, ischemic heart disease, impaired left ventricular function and autonomic neuropathy. His liver function was also impaired as shown by the high levels of liver enzymes, low albumin level and prolonged APTT. Drug selection in such cases is very important. The new hypnotics and neuro-muscular relaxants, which entered into our practice in the last 10-15 years made the perioperative period more predictable. The perioperative pain control, however is not always an easy solution. A good choice could be neuroaxial blockade. Another alternative is non opiate based sedation or light general anesthesia together with peripheral nerve blocks or infiltration with local anaesthetics. In our case, these options were not considered because of patient's sacral bed sores and skin lesions. Remifentanil looked as an attractive choice, because of: it's potency; fast onset/offset features, thus an easy titration; and it's organ independent metabolism.

A single dose of Tramadol was satisfactory for immediate postoperative pain control. Possible explanation could be the reduced pain sensitivity because of poor general condition and the diabetic neuropathy. Such patients often require only sedation and/or local nerve blocks when presented for surgical treatment of necrotic or infective foot lesions. We used rather small doses of Propofol and Remifentanil, because a careful titration of potent drugs in critically ill patients avoids inadvertent side effects like severe

bradycardia and systemic hypotension. Avoiding the latter preserves the blood supply to vital organs like brain, heart, kidney, liver etc. Our patient showed reduction of the blood pressure around thirty minutes after the induction. It could be related to the intravenous application of Tramadol. Another factor could have been a relatively insufficient volume replacement. We were very careful not to overload him having in mind the compromised left ventricle, his septic state and non-functioning kidneys. Moreover just 3 days before the procedure he was overloaded.

The team of our nephrology unit considered him not able to stand hemodialysis or hemofiltration due to the impaired left ventricular performance. Therefore in case of overload an option would have been artificial ventilation and the slow effect of the peritoneal dialysis. On the other hand, there were no signs of deficient perfusion to the vital organs, like ST segment depression/elevation intraoperatively or changes in the postoperative ECG and "cardiac enzymes" levels.

### CONCLUSION

In our opinion the new more predictable hypnotics,

analgesics, and muscle relaxants give more choice when dealing with critically ill patients. Invasive approaches like postoperative artificial ventilation, after a delayed recovery for instance, would be less required. Remifentanil could be safely used in critically ill patients presented for surgical procedures.

### CORRESPONDENCE TO

Miroslav Iordanov Mirkov MD Consultant in Anesthesia & ICU Department Al Amiri Hospital , MOH, Kuwait E-mail to: mmirkov@yahoo.com

### References

1. Glass PSA, Gan TJ, Howell S. A Review of Pharmacokinetics and Pharmacodynamics of Remifentanil. *Anesth. Analg.* 1999; 89: S 7-14
2. Egan TD. Pharmacokinetics and Pharmacodynamics of Remifentanil: an update in the year 2000. *Current Opinion in Anesthesiology.* 2000; 13: 449-455
3. Kirkham AJ, Fisher GR, Kessler P. A dosing algorithm for the use of Remifentanil in providing optimal sedation and analgesia in ICU patients.
4. *Intensive Care Medicine.* 2001; 27: S238 - abstract 405
5. Camu F, Royston D. Inpatient experience with Remifentanil. *Anesth. Analg.* 1999; 89: S 15 - 21

**Author Information**

**Miroslav Iordanov Mirkov, MD**

Consultant in Anesthesia & ICU , Department of Anesthesiology, Anesthesiology and Critical Care, Al Amiri Hospital