

# An Autopsy Proved A Case Of Creutzfeldt-Jakob Disease Presenting With Depression And Catatonia

M Nikanfar, M Halimi, R Mohammadian, M Arami

## Citation

M Nikanfar, M Halimi, R Mohammadian, M Arami. *An Autopsy Proved A Case Of Creutzfeldt-Jakob Disease Presenting With Depression And Catatonia*. The Internet Journal of Neurology. 2003 Volume 3 Number 1.

## Abstract

Creutzfeldt-Jakob disease (CJD) is increasingly being reported over the last three decades as a result of heightened awareness for the disease. Various studies have reported an annual incidence of 0.5-1.5 cases of CJD per million of general population. However, in our country, like other developing countries the disease is still underreported. Here, we describe our clinical experience with an autopsy proved case of CJD.

## INTRODUCTION

Prion diseases, or transmissible spongiform encephalopathies, are a group of fatal neurodegenerative brain diseases, which include scrapie and bovine spongiform encephalopathy (BSE) in animals and kuru and Creutzfeldt-Jacob disease in human. Prion diseases are generally characterised by progressive dementia and ataxia. At the time of death, the brain shows spongiform degeneration due to loss of neurons accumulation of the abnormal protease-resistant form (PrP<sup>RES</sup>) of the normal protease-sensitive cellular glyco-protein (PrP<sup>SEN</sup>).

CJD may have three different origins: sporadic, familial, due to mutations in the prion gene, or infectious, due to iatrogenic exposure to infectious brain material.

This paper describes the clinical experience with an autopsy proved case of CJD managed at the Department of Neurology, Razi Hospital.

This paper describes the clinical experience with an autopsy proved case of CJD managed at the Department of Neurology, at the Razi Hospital in Iran.

## CASE REPORT

A 56 years old woman was referred to our Hospital in October 2003 with a 2 months history of depressive symptoms accompanied by confusion and disorientation. In the past three months, her family members noted her insomnia, loss of appetite and periodic agitation. She was anxious in some days and had some delusions especially in the form of guilt and jealousy. Her interest and pleasure in

almost all activities diminished remarkably.

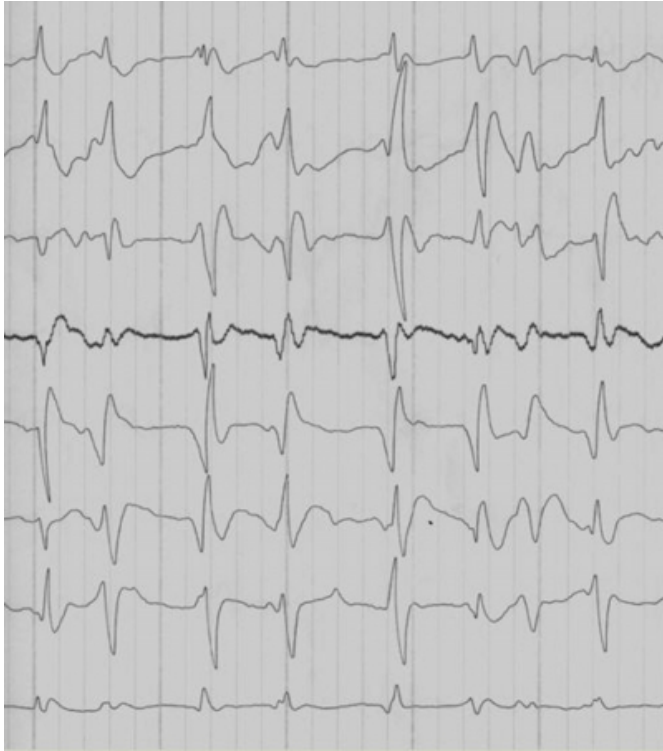She referred to a psychiatrist and the diagnosis of depression was made and treatment with antidepressants (Nortriptylin 75mg /day and haloperidol 0.5mg/day ) was prescribed. Some improvement in the symptoms was seen but after a few weeks her problems were more complicated. Her speech and responsiveness became less and less and eventually she developed complete muteness.

During examination, she was in catatonic stupor state. There was lack of spontaneous speech or movement, absence of goal-directed behavior, stiffness and rigidity in all body movements. The family history and her past medical history were negative for similar disorder, surgery and any other medical problems. The CT scan and MRI were normal. The EEG showed generalized background slowing with a few irregular sharp waves. Biochemical and microbiological studies of CSF were normal. Routine blood counts and chemistries were normal.

Psychiatric consultation was requested and a diagnosis of "bipolar catatonia" was made and electroconvulsive therapy (ECT) was started. After three ECTs the patient's state became deteriorated and she intubated for airway support. During last days of admission some brief and localized myoclonus was noticed in her hand but there was no gross polymyoclonus in history and serial examinations of patient. In the final stage of the disease, the patient lost all her mental and physical functions. The serial EEGs showed generalized periodic sharp waves, 0.5 to 1 cycles per second, typical for Creutzfeldt-Jakob disease (Figure 1).

**Figure 1**

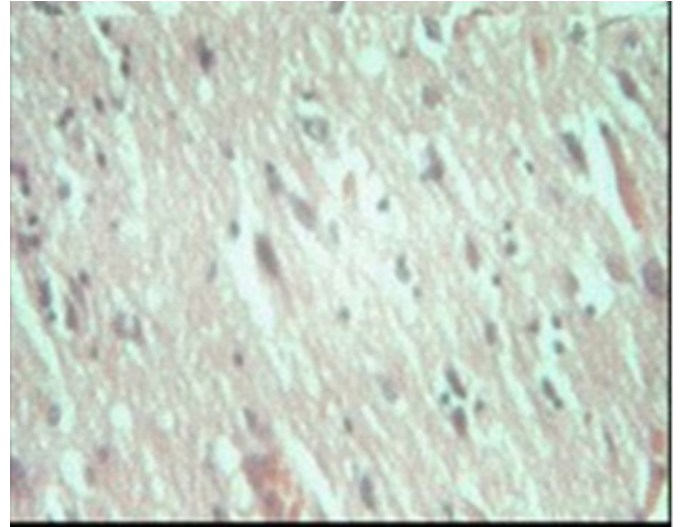
Figure 1



The patient lapsed into coma and died in 4 November 2003 from an infection like pneumonia precipitated by the bedridden and unconscious state. Pathologic study of the brain was done by our colleague. There were no abnormal macroscopic changes at brain autopsy. Histologic examination revealed spongiform transformation of the cerebral cortex with many variable sized vacuoles within the neurophil and sometimes in the perikaryon of neurons, and occasional expansion of the vacuolated areas (microcyst like spaces). No inflammatory infiltrate was present. (Fig.2)

**Figure 2**

Figure 2



## DISCUSSION

Human CJD can be sporadic, infectious or genetic; 80% to 90% of cases are sporadic (those cases in which there is no known infectious source and no evidence of the disease in the prior or subsequent generations of the patient's family).<sup>(1)</sup>

A diagnosis of CJD should be considered when an adult patient develops a rapid dementia and myoclonus. Unfortunately, confirming a diagnosis of CJD has historically been difficult as traditional laboratory tests have been ineffective in detecting CJD. The disease does not induce a fever or other systemic manifestations. Presently, there is no single test for diagnosing CJD. If CJD is suspected, the first step is usually to exclude the possibility that other treatable illnesses are causing the troubling symptoms.

According to WHO criteria, suspicious diagnosis of CJD require: progressive dementia; existence of 2 of following criteria: myoclonus, visual or cerebellar disorders, pyramidal or extrapyramidal signs, akinetic mutism; special electroencephalogram; and absence of any other signs indicating other disease. For definite diagnosis, in addition to above criteria, one of the two followings should be found: characteristic pathologic changes in brain or positive Western blot for confirming PRPsc. (perion protein)<sup>(2)</sup>

In typical cases (dementia, myoclonus, periodic EEG), the diagnosis can be made clinically. However, the diagnosis is difficult to make in atypical cases (no myoclonus, absence of periodic EEG).<sup>(3)</sup> In the study of brown prevalence of

myoclonus at onset of disease was 1% and in later stages was 78% (1). Infrequently, the myoclonus may not appear for weeks or even months after the initial mental changes (as observed in our patient). Also the pathognomonic EEG was seen only in middle and late stages of the disease.

Patients with sporadic Creutzfeldt–Jakob disease may have abnormal patterns of hyper intensity in the basal ganglia on diffusion-weighted MRI sequences, but the specificity and sensitivity of these patterns remain uncertain. Many patients with sporadic Creutzfeldt–Jakob disease have abnormal proteins in their cerebrospinal fluid, most notably the 14-3-3 protein. The specificity of this finding may be as high as 95 percent, but the sensitivity ranges vary from 45 up to 85 percent. (4)

A definitive diagnosis of CJD has traditionally required a brain biopsy or autopsy which can detect the characteristic changes in the brain tissue caused by the disease. Because these procedures are very expensive and pose risks to those handling the brain tissue, they are not always performed. We think this is one of the important reasons for rare case reports of such disease from our country.

The difficulties involved in diagnosing CJD may have prevented the identification of the disease in some cases. Since the disease progresses rapidly, the patient may die before a diagnosis can be made. Furthermore, some physicians may not even consider the possibility of a CJD diagnosis because the disease is deemed to be rare and the clinical symptoms of CJD can often be attributed to other ailments. Consequently, CJD may be mistaken for a variety of psychological illnesses because the behavioral changes were seen in 30% of patients at onset of disease and in 57% of patients in later stages. (1) Five of the 8 cases of Yen et al. with CJD had psychiatric symptoms including changes of mood, thought, behavior and perception during their course of illness. Four cases had been sent to the psychiatric unit and received treatment under several kinds of psychiatric diagnoses. (5) Like our cases, it is likely that it is psychiatrists who will meet CJD patients first in the early stages of disease. Many times there is a positive history of neuroleptic use and in those times the neuroleptic malignant

syndrome (NMS) may be diagnosed and managed. In the other hand, presence of the behavioral and mood abnormalities, like in our case, may result to diagnosis of catatonia of affective disorders or schizophrenia but an abnormal EEG is a point against these disorders (6). We agree with Yen et al that, if the cognitive functions of the patients with unusual neurological symptoms deteriorate quickly and their psychiatric symptoms fail to respond to any treatment, CJD should be kept in mind and EEGs with detailed neurological checkups should be completed. (5) Other neurological disorders like Alzheimer's disease, Pick's Disease, Huntington's disease, cerebral hematomas and vascular irregularities are in the differential diagnosis. The extent of such misdiagnosis is unknown as yet.

The disease is fatal within 1 year in 90% of cases. In 10 reported cases from North India, the mean duration of symptoms from the onset of disease to death was 6.6 months. (7) Our patient had a rapid course, near 3 months.

In conclusion, our experience with this patient showed that in any adult patient with catatonic state even in a course similar to a bipolar mood disorder, CJD must be considered. In such cases ,EEG has very important role and must be done. The characteristic EEG findings of CJD are rarely seen in other disease.

## References

1. Brown P, Gibbs CJ, Rodgers-Johnson P, et al. Human spongiform encephalopathy: the NIH series of 300 cases of experimentally transmitted disease. *Ann Neurol* 1994; 35:513-529.
2. WHO infection control guidelines for transmissible spongiform encephalopathies. Geneva, Switzerland, 23-26 march 1999, WHO/CDS/CSR/APH/2000.3.
3. Burk J: Perion Disease. In: Lewis P. Prowland (editor), *MERRITT'S NEUROLOGY*. Tenth edition. Williams& Wilkins, Philadelphia , 2000:206-209..
4. Kenneth L: Creutzfeldt-Jakob Disease. *NEJM*, 2003, 348(8):681-682.
5. Yen CF, Lin RT, Liu CK, et al. The psychiatric manifestation of Creutzfeldt-Jakob disease. *Kaohsiung J Med Sci*. 1997, 13(4):263-7.
6. Maurice V, Allan H.Ropper. *Adams and Victor's Principles of Neurology*. McGraw-Hill, 2001: 34.
7. Mehndiratta MM, Bajaj BK, Gupta M, et al. Creutzfeldt-Jakob disease: report of 10 cases from North India. *Neurol India*. 2001, 49(4):338-41.

**Author Information**

**M. Nikanfar, M.D.**

Department of Neurology, Razi Hospital, Tabriz University of Medical Science

**M. Halimi, M.D.**

Department of Pathology, Imam Khomini Hospital, Tabriz University of Medical Science

**R. Mohammadian, M.D.**

Department of Pathology, Imam Khomini Hospital, Tabriz University of Medical Science

**M.A. Arami, M.D.**

Department of Pathology, Imam Khomini Hospital, Tabriz University of Medical Science