

Schwannoma of Accessory Nerve: A Case Report

C Ahmadi-Yazdi, S Habashi

Citation

C Ahmadi-Yazdi, S Habashi. *Schwannoma of Accessory Nerve: A Case Report*. The Internet Journal of Otorhinolaryngology. 2005 Volume 4 Number 2.

Abstract

Schwannomas are benign neural tumours which arise from the nerve sheath and consist of Schwann cells in a collagenous matrix. Schwannomas of the accessory nerve are rare lesions. A case of Schwannoma originating from the spinal accessory nerve in the posterior triangle of the neck is described.

Accessory nerve Schwannoma usually presents with nerve palsy. Unusually, our patient presented with a lump in the neck. Location of such neoplasms in this region is exceptional.

This report describes the clinical features of a rare extracranial accessory nerve Schwannoma. The authors emphasize the importance of accurately enucleating the mass; when it is impossible to preserve the continuity of the neural pathway, nerve repair should be considered.

INTRODUCTION

Schwannomas arise from the nerve sheath and consist of Schwann cells in a collagenous matrix. Schwannomas account for 6-8% of intracranial neoplasms. A Study of patients undergoing MRI for indications other than the evaluation of Schwannoma revealed an estimated prevalence of 0.07%. (1)

Vestibular Schwannomas or so called "Acoustic Neuromas" are the most common Cranial Nerve Schwannomas, followed by trigeminal and facial Schwannomas and then glossopharyngeal, vagus (2), and spinal accessory nerve Schwannomas. Schwannomas involving the oculomotor, trochlear, abducens and hypoglossal nerves are the most rare. The clinical presentation of cranial nerve XI Schwannomas relates to their location and extent: intracranial, jugular foramen, upper neck, or cervical spine. Schwannomas in the jugular foramen that arise from the glossopharyngeal, vagus, or accessory nerves, can present with variable cerebellar and acoustic symptoms, depending on the extent of the intracranial growth of the mass. They also can cause glossopharyngeal dysfunction (e.g., difficulty swallowing) and/or spinal accessory symptoms (e.g., trapezius atrophy). Morbidity resulting from Schwannomas includes nerve dysfunction and brainstem compression. Mortality can result from mass effect with brainstem compression. No racial or sexual predilection has been

described in Schwannomas. (1) MRI with the use of gadolinium-based contrast medium is the technique of choice for imaging the Cranial Nerves. MRI provides the highest degree of soft tissue resolution, it can provide images in multiple planes, and it is not encumbered by bone artefact from the skull base. CT is ideal for evaluating the secondary effects on the neural foramina. (3,4,5,6)

CASE REPORT

A 40 year old lady was referred by her GP with a lump in the right side of her neck for a year. She had not noticed any change in the size of the lump during that time. She was also complaining of frequent sore throats, though these usually lasted only for about a day. There were no other associated ENT symptoms. She had a history of hypothyroidism for which she was on Thyroxin 125 mcgs once daily. Examination confirmed a 1.5/1.5 cm firm, mobile, non tender lump at the anterior border of the Sternocleidomastoid muscle.

Flexible nasendoscopy revealed no abnormality. Fine Needle Aspiration (FNA) for cytology was inconclusive. Chest X Ray was normal. Head and Neck CT scan was reported as showing evidence of right deep cervical lymphadenopathy with no other abnormality. (Fig 1)

Figure 1

Figure 1: Neck CT Scan showing Right deep cervical lymphadenopathy

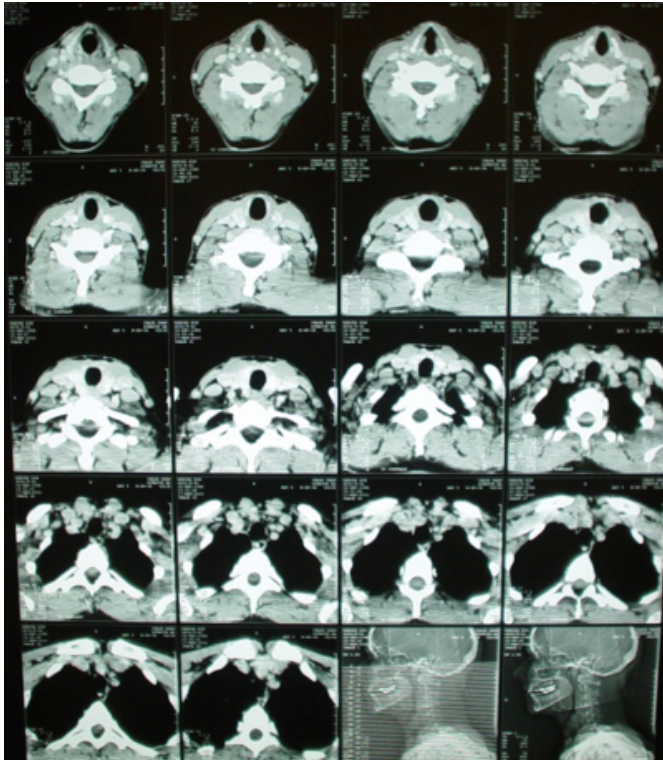
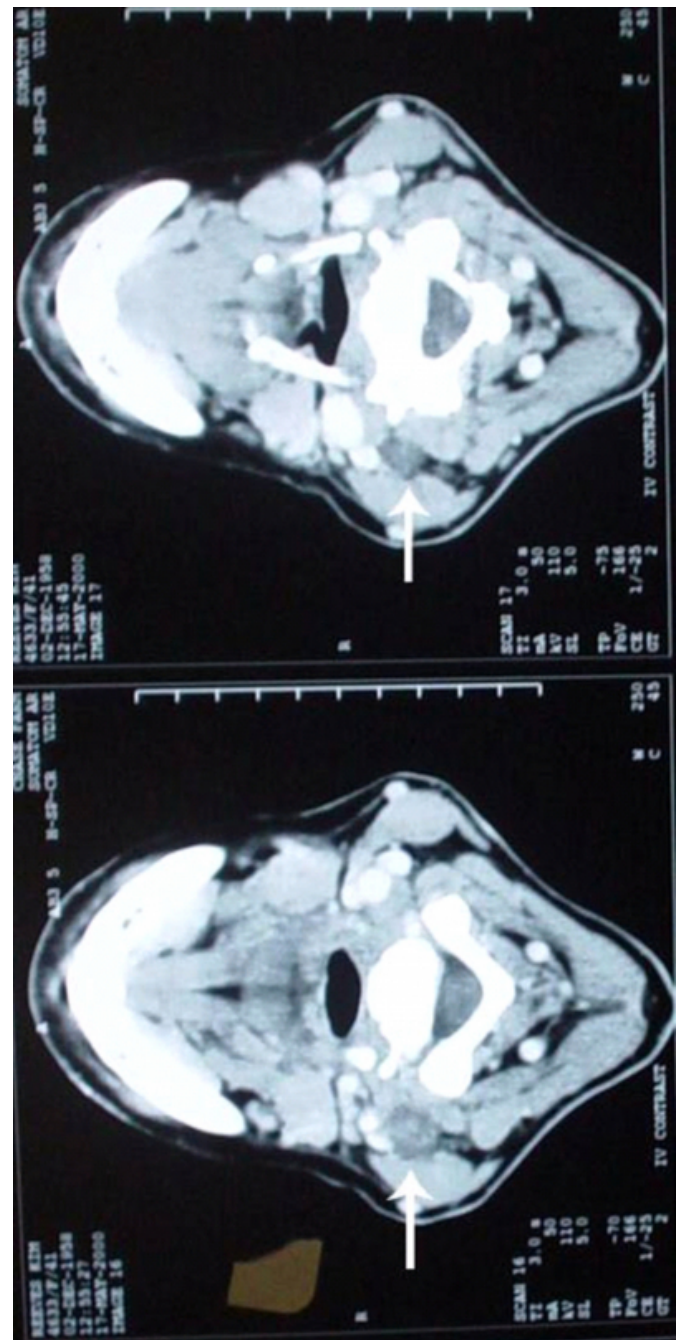


Figure 2



At operation, she was found to have a tumour arising from the Accessory Nerve which was shelled out maintaining continuity of the nerve. Histological analysis showed this to be schwannoma with no evidence of malignancy. She made an uneventful recovery apart from some stiffness of her shoulder and numbness of the cervical skin. The movement of her shoulder recovered completely following physiotherapy and numbness over the skin became unnoticeable by 5 months following surgery.

PATHOLOGY

Schwannomas characteristically arise focally from the sheath of a nerve fascicle forming a well-demarcated, eccentric mass that deflects the parent nerve. The neoplasms are encapsulated with a smooth, sometimes lobulated, external surface. Secondary degenerative changes commonly are present in large lesions and include yellow fatty areas and cysts of varying sizes. Red or maroon discoloration may be present, signifying recent or remote haemorrhage.

DISCUSSION

Schwannomas of cranial nerve XI represent a rare form of all cranial nerve Schwannomas. These tumours are defined as arising specifically from or encasing cranial nerve XI. The extent of cranial nerve involvement may include the cisternal, foraminal, and extracranial (Spinal or intra Sternocleidomastoid) segments of the spinal accessory nerve (Which the extracranial form is the least common ones been reported).^(7,8) (Table1)

Figure 3

Table 1: Accessory nerve Schwannoma

Author (Year)	Reference	Age, y/Sex	Tumour Location
Ruberti and Carteri (1961)	(7)	31/M	JF
Pluchino et al (1975)	(7)	42/F	JF
Pou-Serradell (1978)	(14)	56/F	JF
Christoferson (1982)	(15)	24/F	C
Tsuchiya et al (1982)	(16)	18/M	C
Tohyama et al (1982)	(16)	52/M	C, JF, EC (C-2 level)
Julow (1983)	(16)	50/F	C
Matsushima et al (1985)	(17)	51/M	JF
Kawaguchi et al (1987)	(16)	38/F	EC (C-2 level)
Nakashima et al (1988)	(8)	67/M	JF
Lanzieri (1990)	(5)	45/M	C, JF, EC

Note.—C indicates cisternal; JF, jugular foramen; and EC, extracranial.

The characteristic physical examination finding is denervation atrophy of the trapezius and Sternocleidomastoid muscles ⁽⁹⁾. Of the remaining lower cranial nerves, cranial nerve VIII is most often compromised, and cranial nerve XII is infrequently affected ⁽¹⁰⁾. Hypoglossal nerve dysfunction tends to occur with large intraforaminal masses. When a prominent intracranial component of tumour is present, signs and symptoms referable to brain stem and cerebellar

dysfunction may be identified ⁽¹⁰⁾.

MRI with the use of gadolinium-based contrast medium is the technique of choice for imaging the cranial nerves which has not been done in our case because it was not suspected. The CT and MR appearance of cranial nerve XI Schwannomas parallels that of cranial nerve VIII Schwannomas. On CT, these tumours are hypointense or isodense relative to brain parenchyma. They may contain cystic or necrotic foci but do not manifest a calcified component. On conventional spin-echo MR, Schwannomas are hypointense or isointense to brain on T1- weighted images and variably intense on proton- density and T2- weighted images ⁽⁶⁾. Areas of necrosis or cyst formation appear hypodense on CT, hypointense on T1-weighted spin-echo MR, and hyperintense on T2-weighted sequences. After intravenous contrast administration, these Schwannomas will demonstrate moderate enhancement of solid components on both CT and MR. Early scans reveal slightly heterogeneous enhancement, whereas delayed scanning shows a more homogeneous pattern. ^(11,12,13)

The purpose of this manuscript is to take into consideration the slim possibility of cranial nerve tumor presenting as a lump in the neck.

References

- Patel MR, Davies L. Schwannoma, Cranial Nerve. E Medicine online Journal. 2002 July 19.
- Gilmer-Hill HS, Kline DG: Neurogenic tumors of the cervical vagus nerve: report of four cases and review of the literature. *Neurosurgery* 2000 Jun; 46(6): 1498-503.
- Eldevik OP, Gabrielsen TO, Jacobsen EA. Imaging findings in Schwannomas of the jugular foramen. *AJNR Am Journal of Neuroradiology* 2000 Jun-Jul; 21(6): 1139-44.
- Lo WW. Tumours of the temporal bone and the cerebellopontine angle. In: Som PM, Bergeron RT, eds. *Head and Neck Imaging*. St Louis: Mosby; 1991:1046-1108.
- Lanzieri CF. MR imaging of the cranial nerves. *AJR Am J Roentgenol* 1990; 154: 1263-1267.
- Bilaniuk LT. Adult infratentorial tumors. *Semin Roentgenol* 1990; 25(2):155-173.
- Hakuba A, Hashi K, Fujitani K, Ikuno H, Nakamura T, Inoue Y. Jugular foramen neurinomas. *Surg Neurol* 1979; 11:83-94.
- Nakashima T, Tomita K, Uemura T, Matsushima T, Fukui M. Accessory nerve Schwannoma extending extracranially to the second cervical level of vertebra. *J Laryngol Otol* 1988;102:959-961.
- Noyek AM, Chapnik JS, Wortzman G, Kandel R. Schwannoma of the intrasternomastoid portion of the spinal accessory nerve: sophisticated pre-operative MRI diagnosis and appropriate surgical management. *J Otolaryngol* 1992; 21:286-289.
- Gomez Beldarrain M, Fernandez Canton G, Garcia-Monco JC: Hypoglossal schwannoma: an uncommon cause of twelfth-nerve palsy. *Neurologia* 2000 Apr; 15(4): 182-3.
- Schmalbrock P, Chakeres DW, Monroe JW, et al:

Assessment of internal auditory canal tumors: a comparison of contrast-enhanced T1-weighted and steady-state T2-weighted gradient-echo MR imaging. *AJNR Am J Neuroradiol* 1999 Aug; 20(7): 1207-13.

12. Colreavy MP, Lacy PD, Hughes J, et al: Head and neck schwannomas--a 10 year review. *J Laryngol Otol* 2000 Feb; 114(2): 119-24.

13. Wilson-Pauwels L, Akesson EJ, Stewart PA: Cranial Nerves: Anatomy and Clinical Comments. Decker BC; 1998.

14. Pou-Serradell A, Llovet-Tapies J, Galito E, Pascual J. Neurinome . intracranien du nerf spinal. *Rev Neurol (Paris)*

1978;134:803-805.

15. Christoferson LA, Leech RW, Grossman M. Intracranial neurilemoma of the spinal accessory nerve. *Surg Neurol* 1982;18:18-20.

16. Kawaguchi S, Ohnishi H, Yuasa T, Hashimoto H. Spinal accessory nerve neurinoma in the C2 spinal canal. *Neurologia Medico-Chirurgica* 1987;27:1190-1194.

17. Matsushima T, Fukui M, Matsunaga M, Kitamura K, Hasuo K. Accessory nerve neurinoma mimicking a brain stem tumor on angiography: report of a case. *Neurosurgery* 1985;16: 839-842.

Author Information

Cyrus Ahmadi-Yazdi, M.D.

Senior House Officer, ENT, ENT Department, Chase Farm Hospital, Barnet and Chase Farm Hospitals NHS Trust

Sherif Habashi, MA FRCS

Consultant Otolaryngologist /Head & Neck Surgeon, ENT Department, Chase Farm Hospital, Barnet and Chase Farm Hospitals NHS Trust