

# Vertebra Plana

R Chahal, S Acharya

## Citation

R Chahal, S Acharya. *Vertebra Plana*. The Internet Journal of Spine Surgery. 2006 Volume 4 Number 1.

## Abstract

It is not uncommon for orthopedic surgeons to be called upon to evaluate a child with musculoskeletal manifestations of Langerhans cell histiocytosis (LCH). LCH is a disease that primarily affects bone but can be associated with a clinical spectrum that ranges from a solitary bone lesion with a favorable natural history to a multisystem, life-threatening disease process. Bone involvement with or without other associated sites is the most common manifestation of LCH and has been observed in 80-100% of cases. Despite the preference for bone, the disease may demonstrate extraosseous manifestations as well. While uncommon, this may complicate the clinical picture, occurring most commonly in infants and children with multisystem disease. Although the described triad of diabetes insipidus (DI), exophthalmos, and eosinophilic granuloma does occur occasionally in children, multisystem disease may present in a variety of ways and may be life threatening. The microscopic examination is critical for the diagnosis. Immunohistochemistry using CD1a is now used routinely as a diagnostic tool. Although a positive CD1a immunohistochemical stain in the setting of appropriate histology is usually considered adequate for diagnosis, demonstrating Birbeck granules in the abnormally proliferating Langerhans cells using electron microscopy (EM) is the most specific diagnostic test.

**Key Message:** Carries may be a widely prevalent disease in India, but before making a diagnosis of carries it is important to rule out other causes also, as patient may be subjected to unnecessary long treatment without any benefit

## INTRODUCTION

Eosinophilic Granuloma is not a common pathological process in the spine. The thoracic and lumbar regions are affected more. It can present in a moderate form like Hand-Schuller-Christian Disease to the severe form as Letterer-Seiwe Disease. Sometimes it is difficult to diagnose it on clinical and radiological grounds. Histopathological examination confirms the diagnosis, however in some of the patients that too is difficult<sup>1</sup>. The annual incidence of LCH is reported at 5.4 million children per year<sup>2</sup>. Males are affected to a slightly greater degree than females<sup>3, 4</sup>. It is predominantly a disease of childhood, with more than 50% of cases diagnosed between the ages of 1 and 15. There is a peak in the incidence between the ages of 1 and 4<sup>2</sup>.

Here, we present a patient of Eosinophilic Granuloma; in the body of L1 vertebra

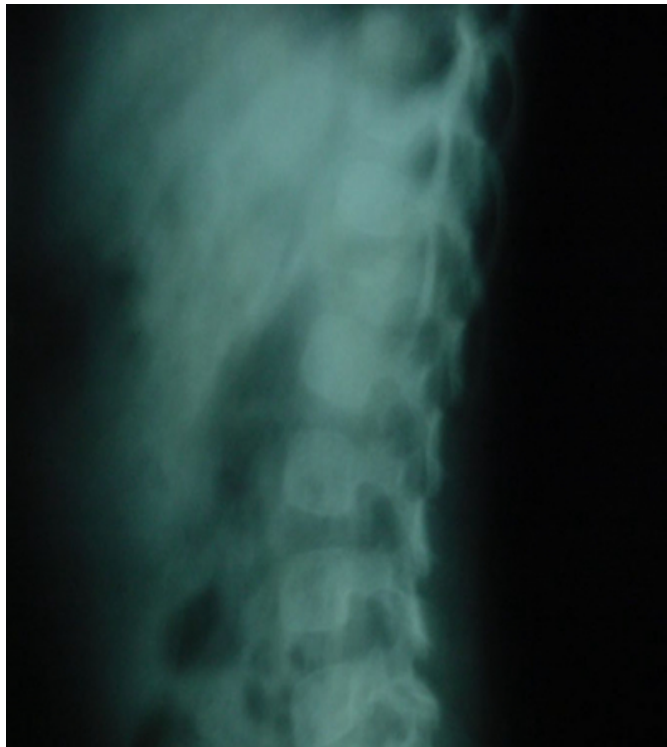## CASE HISTORY

A 2-year-old male LK was brought to OPD with complaints of that child doesn't bend forward to pick objects for one month and pain back for 15 days. There was a history of

trivial fall while playing no major trauma. No history of any other systemic illness, normal birth history, normal milestones. The child was being treated by a local orthopedic surgeon who got X-ray spine done which showed collapse of L1 vertebrae with preservation of adjacent disc spaces, blood count were normal except raised eosinophil count and mildly raised ESR. CRP, CPK all normal and was diagnosed as traumatic fracture L1 vertebrae and put on analgesics, then pt. was seen by a pediatrician and was diagnosed as carries spine, before being referred to us for opinion. We clinically examined the child-Normal built co operative child, no spinal deformity, mild tenderness over dorsolumbar region, no motor sensory deficit in any limb. The child was reluctant to bend down and complained of pain in doing so. We got a MRI done for dorsolumbar region and repeated the blood counts, MRI reported, Post traumatic compression, collapse and posterior projection of L1 vertebrae with evidence of bone edema.

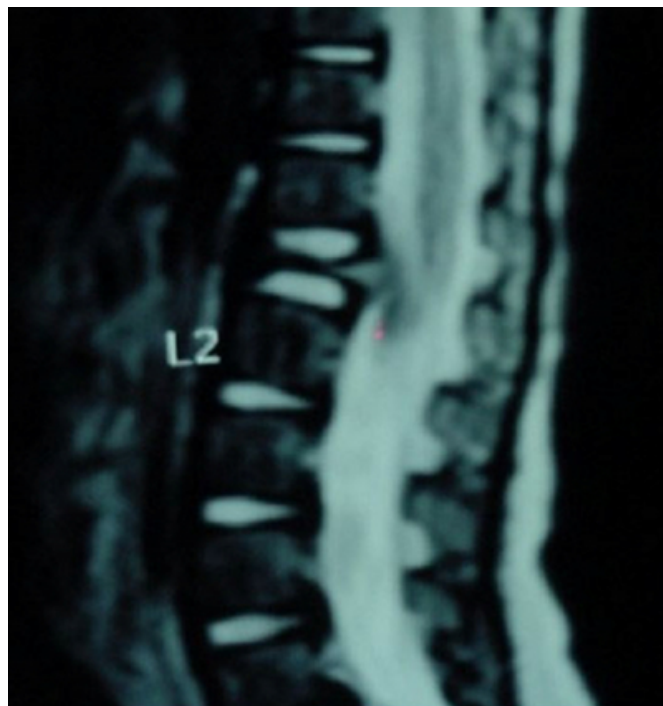
**Figure 1**

Figure 1: Uniform collapse of vertebral body into flat thin disc, increased density of vertebra,neural arches not affected ,disc spaces are normal with normal intervertebral disc space,intervertebral vacuum cleft sign (pathognomonic) ,no kyphosis



**Figure 2**

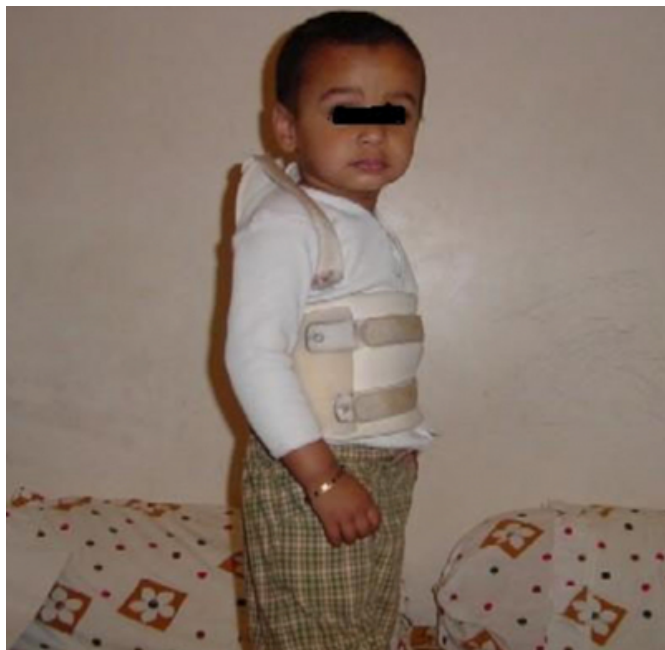Figure 2: MRI reported: Post traumatic compression, collapse and posterior projection of L1 vertebrae with evidence of bone edema



Blood count was normal except raised Eosinophil count. Since child did not have any other symptoms and was neurologically stable, MRI showed normal disc spaces, and Eosinophil count was raised with normal ESR and CRP we clinically made a diagnosis of EOSINOPHILIC GANULOMA and decided to treat child with conservatively. We put him on Syrup Hetrazan ( Diethylcarbamazine) 5ml three times a day for 3 weeks and prescribed a dorsolumbar corset,

### Figure 3

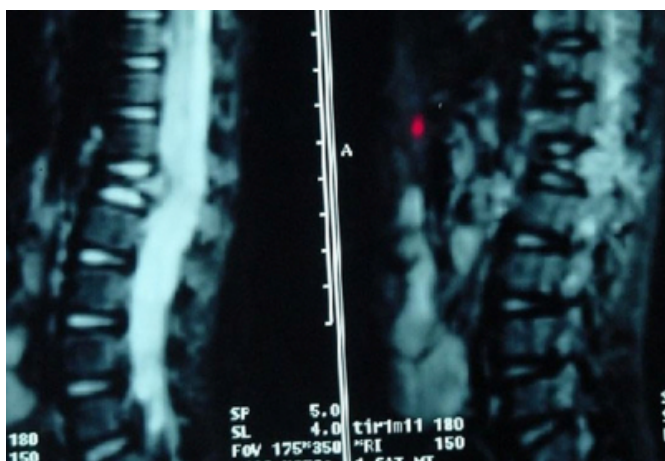Figure 3: Child in Dorsolumbar corset



And planned to followed up child with repeat MR after 3 months. Child is comfortable with brace his pain has completely subsided. He has no other constitutional symptoms and his milestones are normal. Repeat MR shows posterior bulge into canal has cleared, and there is no further collapse or collection.

### Figure 4

Figure 4: Follow up MRI shows posterior bulge into canal has cleared, and there is no further collapse or collection



## DISCUSSION

In 1953 Lichtenstein introduced the term Histiocytosis X, which has histiocytic infiltration of tissues as the predominant pathological process [1]. The three major conditions in this category are 1) Mild form: Eosinophilic

Granuloma. 2) Moderate form: Hand-Schüller-Christian Disease. 3) Severe form: Letterer-Siwe Disease. A clear distinction among these three entities is not always possible on clinico-radiological manifestations

Eosinophilic Granuloma first described by Jaffe and Lichtenstein in 1944, is certainly benign, resembling more an inflammatory process than neoplasm. An infectious cause, perhaps viral, is given some credence as a result of the self-limiting nature of the process in certain individuals and therapeutic effect of antibiotics and steroids. Some supporting data are available on metabolic and genetic factors and immunodeficiency as pathogenetic mechanisms, but in general such evidence is meagre.

Eosinophilic Granuloma is characterized by Single or multiple skeletal lesions occurring predominantly in children, adolescents and young adults. It represents 70% of the total number of causes of Histiocytosis X and is more common in men than women. Clinical manifestations include local pain, tenderness and there may be a palpable soft tissue mass <sup>4</sup>. Fever and leukocytosis may also be apparent. The common sites are the skull, mandible, ribs, spine and long bones, particularly the femur and humerus <sup>1</sup>.

Of all the skeletal manifestations of Eosinophilic Granuloma, it is the changes of the spine that have received greatest attention. Vertebral destruction can lead to a flattened vertebral body, termed “Vertebra Plana”, a finding, which is much more frequent in children than adults<sup>56</sup>. Eosinophilic Granuloma can produce bubbly, lytic, expansile lesions of both the body and posterior elements. The intervertebral disc is usually normal. The thoracic and lumbar spine involvement is more common. Rarely neurologic manifestations ensue.

The gross pathologic abnormalities of Eosinophilic Granuloma include a soft, faintly yellow, hemorrhagic lesion consisting of reticulum cells, multi-nucleated giant cells, eosinophils, lymphocytes and plasma cells <sup>158</sup>.

A single lytic defect must be differentiated from neoplastic and inflammatory lesions as well as fibrous dysplasia. Multiple lytic lesions may simulate infection, metastasis, lymphoma, leukemia, hyper-parathyroidism with brown tumors, and Gaucher's disease .

Eosinophilic Granuloma lesions may resolve spontaneously

at a rate unaffected by the mode of therapy, which include partial or complete surgical excision, radiation therapy, chemotherapy, steroids, alone or in combination<sup>1,8,9</sup>. Surgery is indicated when neurologic affection is found<sup>1,10</sup>. In rest of the patients, a typical healing response of vertebra plana is found with residual bone sclerosis and coarsening of the trabecular pattern and some times “bone within bone” appearance of interbody osseous fusion<sup>1</sup>.

The prognosis in general is related to location and extent of organ involvement. The greater the number of tissues or systems that are affected, the poorer is the prognosis, especially if the liver, lung or hemopoietic systems are involved. The prognosis is also related to the age of the patient at the time of the onset; the younger the patient, the poorer the prognosis<sup>1</sup>.

## **CORRESPONDENCE TO**

R.S. Chahal 61/4, Old Rajinder Nagar, New Delhi-110060.  
E-mail: rupinder72@hotmail.com

## **References**

1. Resnick. Orthopedics: Diagnosis of Bone and Joint Disorders. 3rd edition. 1994; volume 4; p2429-2439.
2. Bhatia S, Nesbit M Jr, Egeler RM, et al. Epidemiological study of Langerhans cell histiocytosis in children. J Pediatr 1997; 130(5): 774-784
3. Huang F, Arceci R. The histiocytoses of infancy. Semin Perinatol 1999; 23(4): 319--331.
4. Agrawal V; Nityanand S. Langerhans Cell Histiocytosis. Journal of Association of Physicians of India. Mar 2000 48; (3); p 346 - 8 ISSN: 0004- 5772
5. Floman Y; Bar-On E; Mosheiff R; Mirovsky Y; Robin GC; Ramu N. Eosinophilic Granuloma of Spine. Journal of Pediatric Orthopedics. Part B (United States). Oct 1997 6; (4); p260 - 5 ISSN: 1060 - 152X.
6. C Villas et al. Eosinophilic Granuloma of the Spine with and without Vertebral Plana ; long term follow up of six cases, Journal of Spinal Disorders, 1993 6; (3); p260 - 8.
7. Katz RL; Silva EG; DeSantos LA; Lukeman JM. Diagnosis of Eosinophilic Granuloma of Bone by Cytology, Histology and Electron microscopy of transcutaneous bone-aspiration biopsy. Journal of Bone and Joint Surgery (United States). Dec 1980; 62 (8); p1284 - 90.
8. Scarpinati M; Artico M; Artizzu S. Spinal Cord Compression by Eosinophilic Granuloma of the Cervical Spine. Neurosurgical Review (Germany). 1995 18; (3); p209 - 12 ISSN: 0344 - 5607.
9. Seimon LP; Eosinophilic Granuloma of Spine. Journal of Pediatric Orthopedics. 1981 1; (4); p371 -6.
10. Kamimura M; Kinoshita T; Itoh H; Yuzama Y; Takahashi J; Ohtsuka K. Eosinophilic Granuloma of Spine: Early Spontaneous Disappearance of Tumor detected on Magnetic Resonance Imaging. Journal of Neurosurgery (United States). Oct 2000 93; (2 suppl); p312 - 6 ISSN: 0022 - 3085.

**Author Information**

**R.S. Chahal, D.N.B(Orth)**

Department of Spine surgery, Sir Ganga Ram Hospital

**Shankar Acharya, M.S., FRCS (orth), Mch (Liverpool), FRCS (Edin), FRCS (Glass)**

Department of Spine surgery, Sir Ganga Ram Hospital