

Management of severe neonatal sepsis caused by *Bacillus cereus*: Two case reports and review of the literature

P Deindl, C Roehr, H Hammer, F Guthmann, H Proquitté, E Halle, R Wauer

Citation

P Deindl, C Roehr, H Hammer, F Guthmann, H Proquitté, E Halle, R Wauer. *Management of severe neonatal sepsis caused by Bacillus cereus: Two case reports and review of the literature*. The Internet Journal of Pediatrics and Neonatology. 2007 Volume 8 Number 2.

Abstract

Bacillus cereus is a rare but highly virulent bacterial pathogen in neonatal medicine, associated with a high mortality rate. We report on the clinical presentation of two infants, one extremely preterm and one term born neonate, who developed severe *B. cereus* infection. In both cases, only the combination of potent second line antibiotics and the removal of all central catheters led to the clinical stabilisation of the patient and to a successful eradication of the pathogen.

INTRODUCTION

Bacillus cereus (*B. cereus*) is an uncommon but aggressive and highly virulent bacterial pathogen in neonatal medicine. Systemic infections are associated with a very high mortality rate. We report on two three neonates, one an extremely low birth weight preterm infant who was critically ill with severe *Bacillus cereus* sepsis and one term neonate with signs of necrotizing enterocolitis (NEC).

CASE PRESENTATION

PATIENT I

Patient one was an extremely low birth weight female neonate born after 26+6 weeks gestation at our tertiary perinatal centre. She was the product of a non-consanguineous relationship and sibling number two of a naturally conceived twin pregnancy. Pregnancy was remarkable for severe twin-to-twin transfusion syndrome, of which she was the donor. Delivery was by Caesarean section due to progressive cardiac failure of her sibling (female, 980g, APGAR 81, 85, 910, umbilical cord pH 7.35). She had severe circulatory failure, a grade 4 intraventricular haemorrhage (IVH) and died shortly after birth. The patient presented was born in reasonably good condition: birth weight 640 g, APGAR 11, 55, 910, umbilical cord pH 7.42. She was treated with CPAP in the delivery room, arterial and venous umbilical lines were inserted and she was admitted to the neonatal intensive care unit (NICU). On admission to NICU she was intubated for progressive respiratory distress syndrome. A grade three intraventricular haemorrhage was diagnosed during the first 6 hours of life.

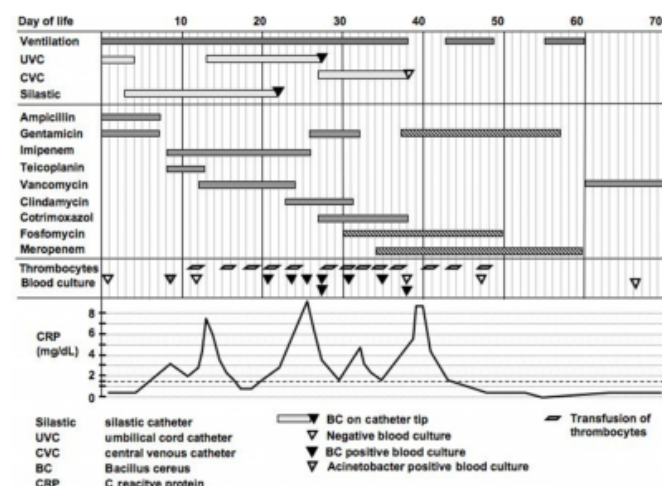
Antibiotic treatment was commenced for suspected perinatal infection (ampicillin 150mg/kg bd and gentamicin 3mg/kg loading dose, followed by 2mg/kg/d) after a central blood culture (BC) was taken. On day 8 of life *Acinetobacter wolffii* was isolated from a single BC and antibiotic therapy was changed to a combination of i.v. teicoplanin and imipenem, according to the sensitivity testing. On day 13 of life, we changed from teicoplanin to vancomycin because we suspected teicoplanin resistance. However, she continued to decline, showing the full-blown picture of neonatal sepsis. She suffered severe arterial hypotension, requiring isotonic saline volume expansion (10ml/kg/hr) and colloidal fluid (Biseco® 20ml/kg/hr), as well as exogenous catecholamine support (noradrenaline [max. 0.3 g/kg/min] and dopamine [max. 3.9 g/kg/min]). Also, i.v. hydrocortisone (20 mg/qm² BSA tds from day 14 to 36 of life) was given for suspected secondary adrenal insufficiency. She required deep sedation with continuous infusion of fentanyl and midazolam. A persisting patent ductus arteriosus (PDA) caused haemodynamic re-circulation and intestinal hypoperfusion and hypomobility. Oral feeds had to be omitted and full parenteral nutrition was given from day 10 to 28 of life. She developed an excessive capillary leak syndrome (max. body weight 1700g on day 19 of life). Venous access was a problem so the umbilical vein had to be re-cannulated on day 13 of life (Vygon®, Ecouen, France) and was only changed to a central femoral venous catheter (Arrow®, Reading, USA) on day 27 of life. Persistent thrombocytopenia (minimum thrombocytes 4 x 10-9/l) made recurrent platelet transfusions (13 transfusions of 20 ml/kg/d) necessary. The

PDA was surgically ligated under running platelet transfusion on day 35 of life.

Bacillus cereus was first isolated on day 21 of life. The first isolate was regarded as a BC contamination, however consecutive BCs were also positive for *B. cereus*, and the antibiotic regime was consequently extended by clindamycin on day 23 of life, according to the microbiologist's advice. *B. cereus* remained present up to day 38 of life, despite a variety of combinations of antibiotics, tailored according to the specific sensitivity testing through our microbiology laboratory. Finally, meropenem was chosen according to the literature presented below. However, it was only after a further extension of our therapy, with a combination of meropenem, gentamicin and fosfomycin and the removal of the central venous catheter on day 38 of life that led to the final stabilization of our patient. Specific antibiotic therapy was ended on day 60 of life after a total of 38 days of treatment. Details of the antibiotic therapy are presented in Figure 1. After that her platelets remained within normal values, catecholamine therapy could be weaned, her weight was reduced to slightly above birth weight with diuretic therapy and oral feeds with hydrolysed milk (Alfa Ré®, Nestle Germany) were successfully reintroduced.

Figure 1

Figure 1: Overview of clinical management, blood cultures, transfusions



The subsequent clinical course was characterised by a post-haemorrhagic hydrocephalus for which she required the installation of a ventricular drain with a pressure controlled valve (day 55 of life) which was changed to a ventriculo-peritoneal shunt (day 85 of life). She further required laser therapy on both eyes for high grade retinopathy of prematurity. The patient was transferred to our peripheral

ward for further care on day 88 of life. She was finally discharged on day 132 of life. She remained in satisfactory condition and is under regular paediatric, ophthalmologic and neuro-developmental follow up.

PATIENT II

A term neonate with congenital diaphragmatic hernia (gestational age 37+4 weeks, birth weight 2315g, initial Apgar-score: 71, thereafter electively ventilated and sedated) who had corrective surgery for a large left-sided diaphragmatic defect on day two of life. He received dopamine as systemic pressure support via a silastic long line and was treated peri-operatively with antibiotic therapy (ampicillin and gentamicin). Postoperatively he was remarkably well, dopamine was discontinued on day 6 of life and the antibiotics were stopped on day 8 of life. He became ill on day 10 of life with temperature instability, occult blood in his stools and a raised CRP (max. 2.7 mg/dl). The abdominal radiograph showed no signs of NEC. He was kept nil-by-mouth and triple antibiotic therapy with cefotaxime, gentamicin and metronidazole was started. Two days into therapy, *B. cereus* was detected in two consecutive peripheral BCs obtained prior to starting treatment. The central line catheter was immediately removed. He remained on the above antibiotic regimen, by which we successfully eradicated *B. cereus* and managed to fully stabilize the patient and recommence oral feeds. The antibiotics were continued up to day 17 of life, and there were no further episodes of infection.

DISCUSSION

B. cereus is a ubiquitous bacterium of the family Bacillaceae. It is motile, aerobic or facultatively anaerobic, spore-forming, gram-positive or gram-variable, and is found in soil, dust, air and water (1). This opportunistic organism is a common cause of food poisoning and mainly causes systemic infections in immuno-compromised patients or those with indwelling foreign bodies such as catheters or shunts (2). There are only few reports of severe and often fatal infections in neonates with *B. cereus* over the last years, indicating that this bacterium is an uncommon but potentially serious pathogen. In neonates, *B. cereus* can lead to systemic infections with bacteraemia, sepsis and endocarditis as well as localised infections of the central nervous system, respiratory tract, eye, wounds and soft tissue (1,2,3,4,5,6,7,8,9,10). According to a recent series of 21 neonates with *B. cereus* infections, mortality is as high as 80% for all neonates with a birth weight of less than 1000g

(6). The pathogenesis of this particularly virulent bacillus species in this special patient group is not entirely understood. Several bacterial toxins, such as phospholipase, proteases and haemolysins are known and considered as the reason for the severe damage of infected tissues (10).

We believe that due to a lack of awareness of the toxicity of this organism in neonatal medicine, an initial isolation of this relatively harmless food pathogen may mistakenly be overlooked and considered as a blood culture contamination, as occurred with our index case (6). In both our patients, the clinical course replicates previous reports of severe septic infections with *Bacillus cereus* in neonates (3, 5, 6, 7, 8, 9, 11). With regard to our index patient, serologic markers of infection declined after each change of antibiotics, but this was always only a transient effect. Despite the broad susceptibility for first line antibiotics of the present pathogen, antibiotic treatment remained ineffective, whilst the central catheter remained in situ. For patient one, it was only the change to a combination of potent second line antibiotics and the removal of all central lines that led to the successful eradication of the pathogen. With this initial experience we immediately removed the central line in patient two, which led to a complete recovery, before serious complications other than transient intestinal bleeding occurred.

Other authors have published their clinical experience with *B. cereus* in neonates. In these reports, a broad variation of first and second line antibiotics was used with varying success. Based on data from Hillard et al., survival seemed more likely if meropenem was included in the therapy, which is why we included meropenem in to our antibiotic regime (6). In conclusion, we wish to heighten clinicians' awareness of the possibility of *B. cereus* infection in sick neonates and to stress the importance of prompt treatment

and the removal of all central catheters to facilitate eradication.

CORRESPONDENCE TO

Department of Neonatology Charité Universitätsmedizin
Berlin Campus Mitte Charitéplatz 1 10117 Berlin Germany
Phone: +49 30 450 516064 Fax: +49 30 450 516921 Email:
philipp.deindl@charite.de

References

1. Sliman R, Rehm S, Shlaes DM. Serious infections caused by *Bacillus* species. *Medicine (Baltimore)* 1987, 66: 218-223.
2. Gaur AH, Shenep JL. The expanding spectrum of disease caused by *Bacillus cereus*. *Pediatr Infect Dis J* 2001, 20: 533-534.
3. Chu WP, Que TL, Lee WK, Wong SN. Meningoencephalitis caused by *Bacillus cereus* in a neonate. *Hong Kong Med J* 2001, 7: 89-92.
4. Drobniewski FA. *Bacillus cereus* and related species. *Clin Microbiol Rev* 1993, 6: 324-338.
5. Gray J, George RH, Durbin GM, Ewer AK, Hocking MD, Morgan ME. An outbreak of *Bacillus cereus* respiratory tract infections on a neonatal unit due to contaminated ventilator circuits. *J Hosp Infect* 1999, 41: 19-22.
6. Hilliard NJ, Schelonka RL, Waites KB. *Bacillus cereus* bacteremia in a preterm neonate. *J Clin Microbiol* 2003, 41: 3441-3444.
7. Jevon GP, Dunne WM, Jr., Hicks MJ, Langston C. *Bacillus cereus* pneumonia in premature neonates: a report of two cases. *Pediatr Infect Dis J* 1993, 12: 251-253.
8. Patrick CC, Langston C, Baker CJ. *Bacillus* species infections in neonates. *Rev Infect Dis* 1989, 11: 612-615.
9. Tokieda K, Morikawa Y, Maeyama K, Mori K, Ikeda K. Clinical manifestations of *Bacillus cereus* meningitis in newborn infants. *J Paediatr Child Health* 1999, 35: 582-584.
10. Turnbull PC, Jorgensen K, Kramer JM, Gilbert RJ, Parry JM. Severe clinical conditions associated with *Bacillus cereus* and the apparent involvement of exotoxins. *J Clin Pathol* 1979, 32: 289-293.
11. Van Der Zwet WC, Parlevliet GA, Savelkoul PH, Stoof J, Kaiser AM, Van Furth AM, et al. Outbreak of *Bacillus cereus* infections in a neonatal intensive care unit traced to balloons used in manual ventilation. *J Clin Microbiol* 2000, 38: 4131-4136.

Author Information

Philipp Deindl, MD

Department of Neonatology, Charité Universitätsmedizin Berlin

Charles-Christoph Roehr, MD

Department of Neonatology, Charité Universitätsmedizin Berlin

Hannes Hammer, MD

Department of Neonatology, Charité Universitätsmedizin Berlin

Florian Guthmann, MD

Department of Neonatology, Charité Universitätsmedizin Berlin

Hans Proquitté, MD

Department of Neonatology, Charité Universitätsmedizin Berlin

Elke Halle, MD

Institute of Microbiology, Charité Universitätsmedizin Berlin

Roland Wauer, MD

Department of Neonatology, Charité Universitätsmedizin Berlin