

Maxillary Permanent Tooth In The Nasal Cavity. Report Of Two Cases With Different Etiopathogenesis, Management And Review Of The Literature.

R Kumar, . Kumar

Citation

R Kumar, . Kumar. *Maxillary Permanent Tooth In The Nasal Cavity. Report Of Two Cases With Different Etiopathogenesis, Management And Review Of The Literature..* The Internet Journal of Dental Science. 2009 Volume 9 Number 1.

Abstract

The presence of tooth in the nasal cavity is a rare and unnatural phenomenon. Literature suggests that supernumerary teeth, ectopic eruption, trauma, cysts, rhinogenic or odontogenic maxillary infections, cleft of the lip or palate, genetics and presence of a third tooth bud may be potential predisposing factors for the tooth to occur in the nasal cavity. We report two cases of teeth involving the nasal cavity but with different etiology. The etiopathogenesis, complications, diagnosis and management for this condition are discussed.

INTRODUCTION

It is very unnatural and rare for a tooth to be present in the nasal cavity. Approximately 50 cases of a nasal tooth have been reported so far in the literature (1). The etiology of nasal tooth is unclear. Theories explaining it include developmental disturbances, infections, genetic factors, trauma, crowding of dentition, cysts, persistent deciduous teeth or exceptionally dense bone (2). The clinical manifestations are varied, however the intranasal tooth may also be completely asymptomatic and may only be noted on routine clinical or radiographic examination. The diagnosis of nasal tooth is made on the basis of clinical and radiographic findings. Computed tomographic scanning is helpful in diagnosing and treatment planning of intra nasal tooth apart from plain radiographs of the facial region (3). The differential diagnosis should include foreign bodies in the nasal cavity, rhinoliths, bony sequestra, neoplasms and exsostosis (2). The treatment involves surgical removal of the symptomatic intra nasal tooth. Asymptomatic tooth should preferably be removed or at least followed radiographically.

CASE 1

A 20 year old female patient was referred to the Department of Oral and Maxillofacial Surgery, Vishnu Dental College and Hospital, Bhimavaram, A.P. India. for diagnosis and management of a radiopaque lesion in the left nasal cavity noted during routine dental radiographic examination. The

patient was asymptomatic at the time of examination but gave a history of chronic left nasal congestion. She denied any history of trauma or swelling. No significant medical history was noted. On intra oral examination retained deciduous upper left canine was noted. A white mass resembling a tooth could be clearly visualized in the floor of the left nasal cavity away from the ostium (fig – 1). Radiographs included maxillary occlusal view as well as orthopantomogram (fig – 2 and 3) which revealed a radiopaque mass resembling a tooth (permanent canine).

Figure 1

Figure 1 : Extra oral photograph showing a white mass in the left nasal cavity resembling a tooth.

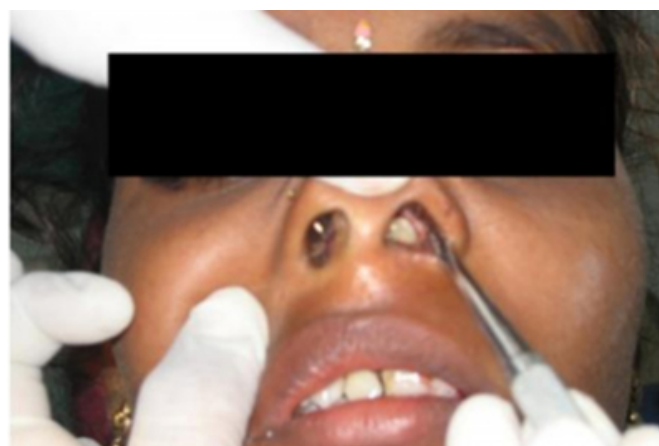

Figure 2

Figure 2 : Maxillary occlusal radiograph reveals a left permanent canine tooth (black arrow) at the apex of the root of the left central incisor.

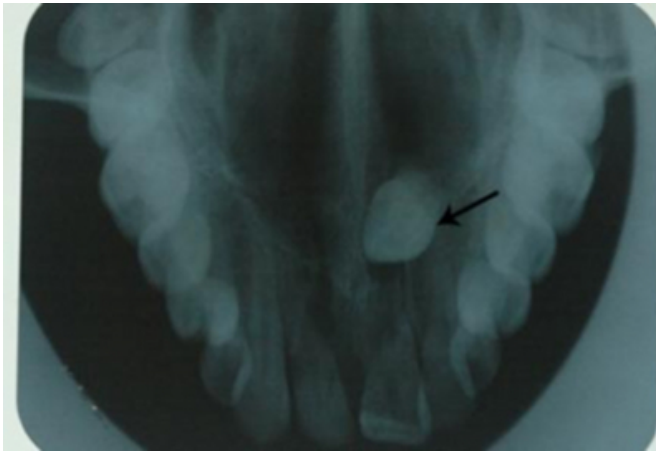
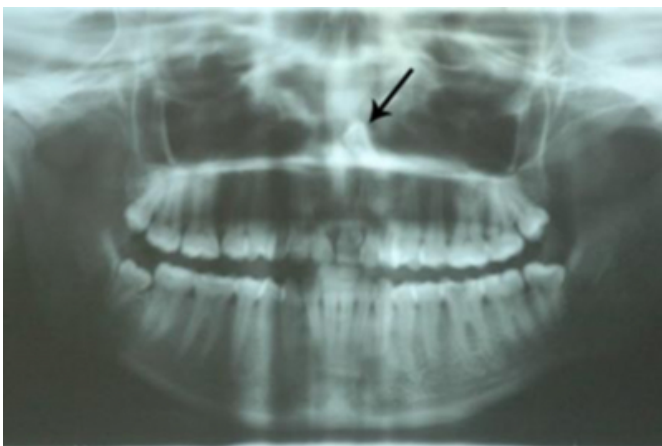


Figure 3

Figure – 3 : Pre operative orthopantomogram showing maxillary left canine (black arrow).



The patient was further questioned about the ectopic eruption of the tooth into the nasal cavity. She admitted having knowledge of its presence since 3 years when it was diagnosed by another dentist. The ectopically erupted permanent maxillary left canine (fig – 4) was surgically removed by an Oral and Maxillofacial surgeon via the trans nasal approach from the left nasal cavity as is evident from the post operative orthopantomogram (fig – 5). Under local anaesthesia (2% lidocaine with 1:1,00,000 adrenalin) and strict aseptic conditions the tooth in the nasal cavity was elevated with an ball end probe placed below it and retrieved using a forceps. Anterior nasal pack was placed. No intra operative complications were noted. Before being discharged the patient was advised oral medication of cap Amoxicillin 500 mg three times daily for 5 days along with

tab Diclofenac sodium 75 mg three times a day for 5 days. The patient was reviewed 3 days after discharge. The anterior nasal pack was removed and the surgical area was inspected for wound healing which was satisfactory. There were no significant complaints during the follow up period which lasted 3 years .

Figure 4

Figure – 4 : Photograph of the surgically removed ectopic left maxillary permanent canine tooth

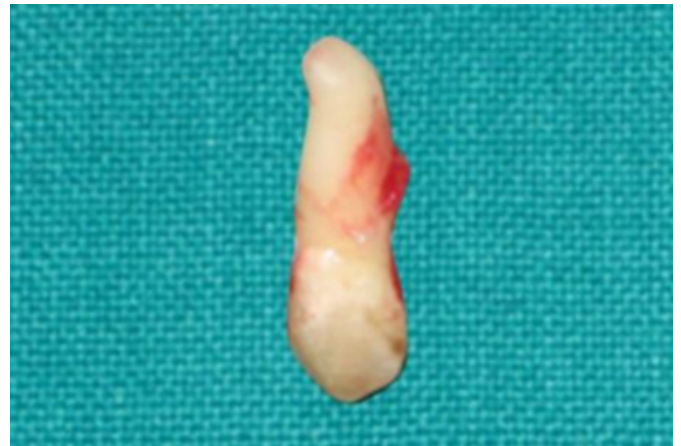
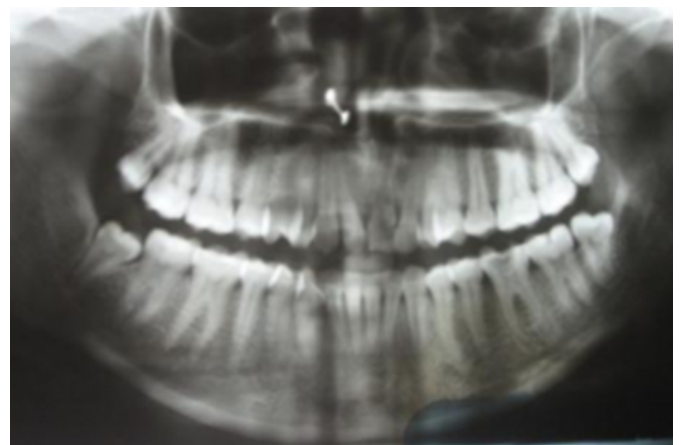
Figure 5

Figure – 5 : Post operative orthopantomogram



CASE 2

A 35 year old male patient was referred to the Department of Oral and Maxillofacial Surgery, Vishnu Dental College and Hospital, Bhimavaram, A.P. India from another centre regarding his missing left maxillary central incisor. The patient had a history of trauma to the facial region two months earlier. His medical history was not significant but he complained that he could not breath freely from his left nostril and also has a sensation of foreign body lodged in the nostril. On intra oral examination there was a missing left

maxillary central incisor . On examination of the left nostril , a tooth like structure could be clearly visualized (fig – 6). Lateral skull radiograph (fig – 7) demonstrated a radiopaque lesion that did not appear to be related anatomically but resembled a tooth like structure. The tooth (fig – 8) was removed surgically via trans nasal approach by an Oral and Maxillofacial surgeon. Under local anaesthesia (2% lidocaine with 1:1,00,000 adrenalin) and strict aseptic conditions the tooth in the nasal cavity was elevated with an ball end probe placed below it and retrieved using a forceps. Anterior nasal pack was placed. No intra operative complications were noted. Before being discharged the patient was advised oral medication of cap Amoxicillin 500 mg three times daily for 5 days along with tab Diclofenac sodium 75 mg three times a day for 5 days. The patient was reviewed 3 days after discharge. The anterior nasal pack was removed and the surgical area was inspected for wound healing which was satisfactory. The patient had a follow up period of 3 years during which he had no further complaints.

Figure 6

Figure – 6 : Extra oral photograph showing a white mass in the left nostril resembling a tooth

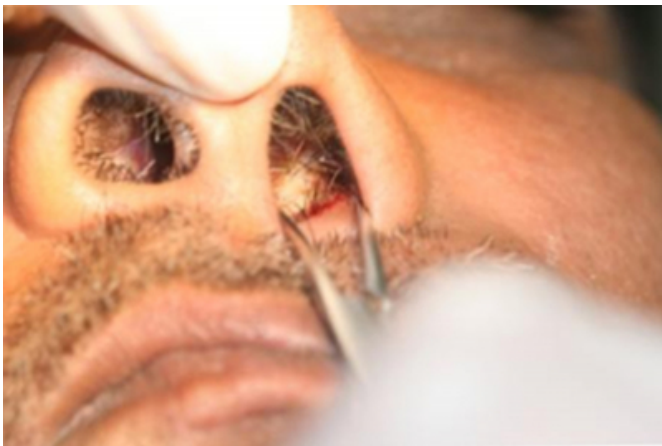

Figure 7

Figure – 7 : Lateral skull radiograph which reveals the intruded maxillary left central incisor (black arrow)

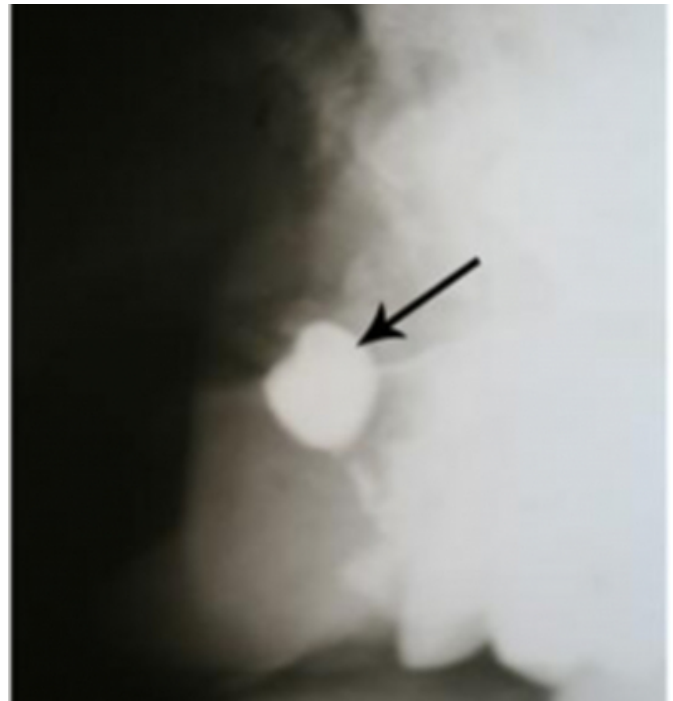
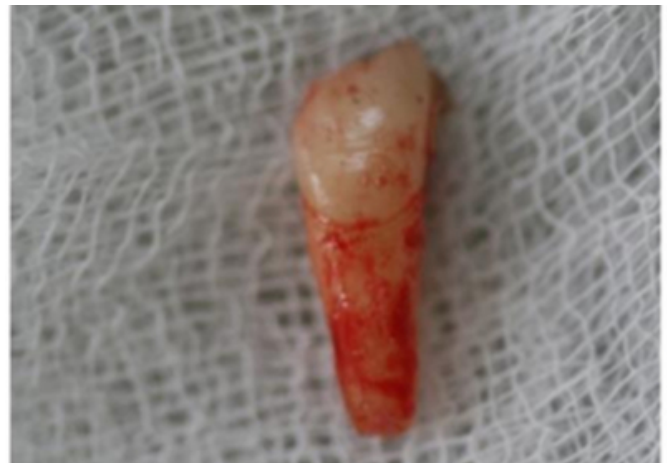
Figure 8

Figure – 8 : Photograph of the intruded left maxillary central incisor which was surgically removed



DISCUSSION

Intra nasal tooth is an unnatural phenomenon and rare. It was originally described in 1897 (4). Smith .et.al in 1979 identified 27 cases of well documented intra nasal teeth (2). In 2008 Y.K Gupta and N. Shah have reviewed over 50 cases of teeth occurring in the nasal cavity (1). The etiology of intra nasal teeth is unclear and controversial. Theories explaining it include developmental disturbances such as

cleft of the lip and palate, teeth displaced by trauma or cysts, maxillary infections either odontogenic or rhinogenic, genetic factors, obstruction to eruption secondary to crowding of the dentition, persistent deciduous teeth, exceptionally dense bone, supernumerary and ectopic teeth (2). Presence of a third tooth bud has also been implicated as one of the predisposing factors for the development of a nasal tooth (5).

The two cases which we have presented there is significant difference in the etiopathogenesis leading to the tooth in the nasal cavity. In case 1 the patient did not have a history of trauma or infection except that she suffered from chronic congestion of her left nostril. She was also aware of the fact that there was an ectopically erupted tooth in her left nasal cavity. Ectopic teeth are estimated to occur in 1 % of the general population (4). The presence of teeth have been reported in ovaries, testes, anterior mediastinum and pre sacral regions (1). In the maxillofacial region teeth have been found in the nose (2), maxillary sinus (6), mandibular condyle (5), coronoid process (7), chin, skin (8), orbit and even in patients with cleft of lip and palate (1). The cause of ectopic teeth is varied. Obstruction at the time of tooth eruption has been thought to predispose to ectopic growth. This obstruction may occur in conditions such as crowded dentition, persisting deciduous teeth, (our patient had retained deciduous upper left canine) or in exceptionally dense bone (9). Smith et al. in 1979 reported single as well as multiple ectopic teeth and described no predilection towards the right or the left nasal cavity (2).

In case 2 it was obvious that the patient had a history of trauma to the facial region which lead to the intrusion of the left maxillary permanent incisor into the nasal cavity. Intrusive luxation is one of the five different types of luxation injuries which comprises 15 – 61 % of dental traumas to the permanent dentition (10). It is represented by displacement of the tooth deeper into the alveolar bone and is usually accompanied by comminution or fracture of the alveolar socket, and the direction of dislocation follows the axis of the tooth. With increasing age the frequency and pattern of injury change. In the permanent dentition the number of intrusive luxation injuries is considerably reduced and is usually seen in the younger individuals (related to the resilience of the alveolar bone at this stage) (10), which is in contrast taking into consideration the age of our patient. Luna A.H.B et.al (11) and Martin B.S (12) have reported traumatic intrusion of the maxillary permanent incisor into

the nasal cavity in patients who were younger than 12 years of age.

The diagnosis of intranasal tooth is made on the basis of clinical and radiographic findings. Clinically, intranasal tooth would present as a hard white mass and is usually surrounded by granulation tissue and debris (2). Radiographic examination including caldwells, waters, lateral view of the skull, panoramic radiographs may be helpful in confirming the diagnosis because the intranasal tooth may appear as a non specific radiopaque lesion in or near the nasal cavity (13). Albert C et al. are of the view that the computed tomographic findings of tooth equivalent attenuation and a centrally located cavity are highly discriminating features that help to confirm the diagnosis (3).

The differential diagnosis of nasal teeth should include radiopaque foreign body, rhinolith (calculus present in the nasal cavity) , inflammatory lesions due to syphilis, tuberculosis or fungal infection with calcification, benign tumours, haemangioma, osteoma, calcified polyps, enchondroma and dermoid and malignant tumours such as chondrosarcoma and osteosarcoma (2,14).

The intranasal tooth may present with a variety of symptoms or they may be completely asymptomatic. Symptoms include nasal congestion (15) (evident in case 1), unilateral nasal obstruction (15) (evident in case 2), chronic nasal discharge (8) , crusting of the nasal mucosa (16) , localized ulceration (17) , nasal pain and epistaxis (18,8) , nasal septal abscess (19), nasal and oral fistula (2,5) , osteomyelitis of the maxilla (17,20) , facial pain and head ache (6) , cacosmia (21), and septal perforation (18). Thorali (22) in 2002 stressed the importance of first correct clinical and radiological examination so that the various complications can be prevented.

The treatment of intranasal tooth is early surgical removal when diagnosed (as was done in our cases) because of the potential morbidity. Some authors (2,9) are of the view that asymptomatic patients can be observed with close radiographic follow up while others (4,6,15) recommend extraction of asymptomatic teeth their argument being that asymptomatic patients may become symptomatic with time. There is also a potential for more serious sequelae (eg; deep fascial space abscess) because the nasal tooth lies in the area of danger triangle of the mid face. Murthy et al. in 1988 recommended that the best time to remove these teeth is

when the roots of the permanent teeth have completely formed so that possible injury to their development can be avoided (7).

The surgical procedures include a trans nasal or trans palatal approach (15), however if the tooth is associated with osteomyelitis, intra oral fistulae or septal deviation, then concomitant surgical procedures such as debridement, septoplasty (21) or septorhinoplasty (7) may be necessary. Endoscopic extraction of intranasal tooth has been advocated and recommended by some authors (15,23). Even though it offers good illumination, clear visualization, precise dissection with preservation of neighboring structures (24,25) this technique requires specific instrumentation and training (26).

CONCLUSION

Two cases of maxillary teeth involving the nasal cavity are reported which were surgically extracted via the trans nasal approach without any intra operative or post operative complications. The authors recommend early surgical removal of the nasal tooth when diagnosed to prevent potential morbidity.

References

1. Gupta YK, Shah N . Intranasal tooth as a complication of cleft lip and alveolus in a four year old child : case report and literature review. *International Journal of Paediatric Dentistry* . 2008 ; 11 (3) : 221- 4.
2. Smith RA, Gordan NC, Deluchi SF . Intranasal teeth : report of two cases and review of the literature. *Oral Surg Oral Med Oral Pathol* . 1979 ; 47 (2) : 120 - 2.
3. Albert C, Jon KH, Sho JC, Chin YS . Nasal teeth : report of three cases. *Am J Neuroradiol* . 2002 ; 23 : 671 - 3.
4. Moreano EH, Zich DK, Goree JC, Graham SM . Nasal tooth. *American Journal of Otolaryngology* . 1998 ; 19 (2) : 124 - 6.
5. Thawly SE, Ferriere KA . Supernumerary nasal tooth. *Laryngoscope* . 1977 ; 87 : 1770 - 3.
6. Spencer MG, Couldery MG . Nasal tooth. *J Laryngol Otol* . 1985 ; 99 : 1147 - 50.
7. Murthy PS, Hazarika P, Hebbar GK . Supernumerary nasal teeth. *Ear Nose Throat J* . 1988 ; 67 : 127 - 9.
8. Hiranandani LW, Melgiri RD . Supernumerary tooth in the floor of the nose. *J Laryngol* . 1968 ; 82 : 845 - 8.
9. Carver DD, Peterson S, Owens T . Intranasal tooth. *Oral Surg Oral Med Oral Pathol Oral Radiol Endod* . 1990 ; 70 : 804 - 5.
10. Andreason FM, Andreason JO . Luxation Injuries. Text book and colour atlas of traumatic injuries to the teeth. 3rd Ed. Copenhagen : Munksguard ; 1994 .
11. Luna AHB, Moreira RWF, Demoraes M . Traumatic intrusion of maxillary permanent incisors into the nasal cavity : report of a case. *Dental Traumatology* . 2008 ; 24 : 244 - 7.
12. Martin BS . Traumatic intrusion of maxillary permanent incisors into the nasal cavity associated with a seizure disorder : report of a case. *Dental Traumatology* . 2003 ; 19 : 286 - 8.
13. Pracy IPM, Williams HOL, Montgomery PQ . Nasal teeth. *J Laryngol Otol* . 1992 ; 106 : 366 - 7.
14. Alexandrakis G, Hubbell RN, Aitken PA . Nasolacrimal duct obstruction secondary to ectopic teeth. *Ophthalmol* . 2000 ; 107 : 189 - 92.
15. Lee FP . Endoscopic extraction of an intra nasal tooth : a review of 13 cases. *Laryngoscope* . 2001 ; 111 : 1027 - 31.
16. Chopra SS, Joshi MR . Mesiodens erupted in the nasal cavity. *Oral Surg Oral Med Oral Pathol* . 1969 ; 28 : 856 - 8.
17. Rege SR, Shal KI, Marfatia PT . Osteomyelitis of the maxilla with extrusion of teeth in the floor of the nose requiring extraction. *J Laryngol Otol* . 1970 ; 84 : 533 - 5.
18. Nastri AL, Smith AC . The nasal tooth : case report. *Aust Dent J* . 1996 ; 41 : 176 - 7.
19. Martinson FD, Cockshott WP . Ectopic nasal dentition. *Clin Radiol* . 1972 ; 23 : 451 - 4.
20. Dayal PK, Dewan SK, Bihani VK, Dave CJ . Eruption of a tooth into the nasal cavity due to osteomyelitis. *J Laryngol Otol* . 1981 ; 95 : 509 - 12.
21. Wood GD, Glas CPS, Mackenzie I . A dento nasal deformity. *Oral Surg Oral Med Oral Pathol* . 1987 ; 63 : 656 - 7.
22. Thorali . Delayed removal of a fully intruded primary incisor through the nasal cavity : a case report. *Dental Traumatology* . 2002 ; 18 (4) : 227 - 30.
23. Kim DH, Kim JM, Chae SW, Hwang SJ, Lee SH, Lee HM . Endoscopic removal of an intra nasal ectopic tooth. *International Journal of Paediatric Otorhinolaryngology* . 2003 ; 67 (1) : 79 - 81.
24. Traulis MJ, Kaban LB . Endoscopic vertical ramus osteotomy : early clinical results. *J Oral Maxillofac Surg* . 2004 ; 64 : 824 - 8.
25. Tumer C, Eset AE, Atabek A . Ectopic impacted mandibular third molar in the sub condylar region associated with a dentigerous cyst : a case report. *Quintessence Int* . 2002 ; 33 : 231 - 3.
26. Salmeron JI, DelAmo A, Plasencia J, Pujal R, Vila CN . Ectopic third molar in the condylar region. *Int J Oral Maxillofac Surg* . 2008 ; 37 : 398 - 400.

Author Information

Raichoor Anil Kumar

Dept of OMFS, Vishnu Dental College and Hospital

. P. Siva Kumar

Dept of OMFS, Vishnu Dental College and Hospital