

Proliferating Trichilemmal Cyst Of The Arm

P Sharma, D Sarma

Citation

P Sharma, D Sarma. *Proliferating Trichilemmal Cyst Of The Arm*. The Internet Journal of Dermatology. 2005 Volume 4 Number 2.

Abstract

Benign proliferating trichilemmal tumor (PTT) is typically seen in middle aged or elderly patients, with a strong predilection for women and is usually situated in scalp. We are reporting such a tumor located on the arm of a 51-year-old woman and briefly reviewing the literature.

CASE REPORT

A 51-year-old woman presented with a 1-cm nodule on the left arm. Microscopic examination (Figures 1 and 2) revealed a well-circumscribed, partly cystic mass. The cystic areas were filled with trichilemmal-type keratin. Cords and lobules of squamoid cells are seen at the periphery of the cyst and filling part of the cyst lumen. The cells were cytologically benign. There were no increased mitoses or cellular pleomorphism. There was no invasion into surrounding dermal tissue.

Figure 1

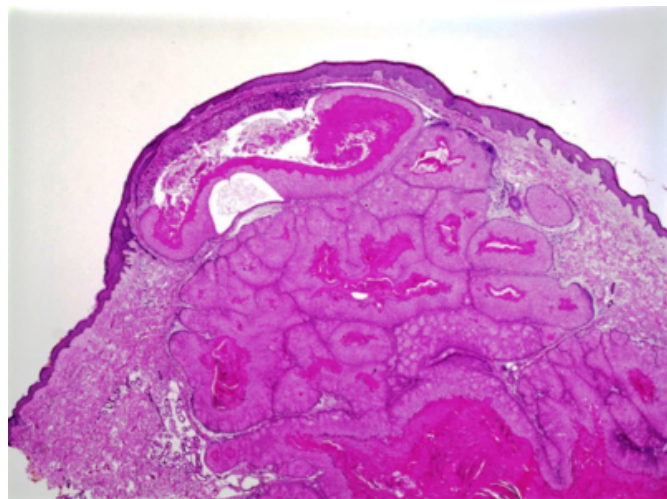
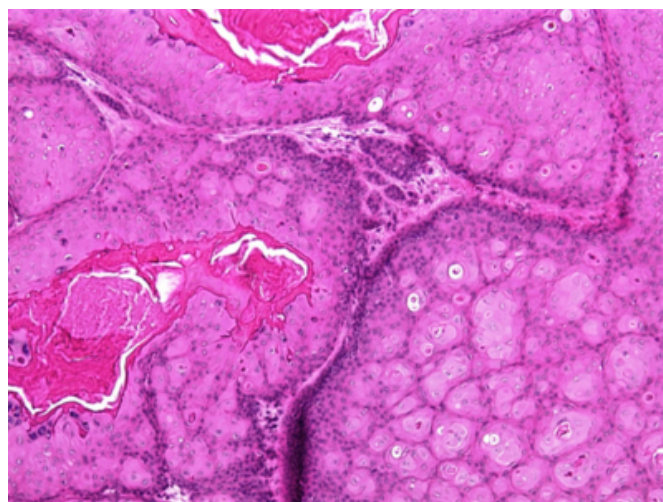


Figure 2



DISCUSSION

Proliferating trichilemmal cyst, commonly known as proliferating pilar tumor (PPT) is a benign adnexal tumor of skin related to the isthmus of hair follicle. PPT has predilection for women and most commonly occurs on the scalp during fourth to eight decade of life. Its occurrence at other sites, including rare reports of cases arising in arm, has been documented (^{1,2,3,4}). The tumor may clinically and histologically resemble squamous cell carcinoma (⁵). Sharp circumscription, lack of epidermal connection, low mitotic activity, and presence of trichilemmal keratinization favor a benign interpretation.

A rare malignant variant of PPT with local invasion and metastasis has been described (⁶). In an effort to correlate histologic features with tumor behavior Ye et al classified the PPT cases into three morphologic groups, benign (BPPT), low malignant PPT (LMPTT) and high malignant

PPT (HMPTT) (7). Sharp circumscription of the lesion separates benign tumors from the other two categories. Low malignant PPT closely resembles BPPT, except that it is irregularly shaped and shows buds of neoplastic cells in surrounding stroma. High malignant PPT loses the circumscribed architecture and shows severe nuclear and cellular atypia. The tumor in latter category has high potential for regional recurrence and metastasis. DNA aneuploidy and high proliferative activity have been seen in some malignant PPT (8, 9).

Although malignant PTT is rare, a diagnosis of benign PTT on curettage or piecemeal specimen should be avoided because the architecture of the tumor at low power is the major diagnostic clue to the benign nature of the lesion. Fragmented biopsy sample may also be misinterpreted as a squamous cell carcinoma.

CORRESPONDENCE TO

Deba P. Sarma, MD Department of Pathology Creighton University Medical Center Omaha, NE 68131 Telephone: 402-449-4951 E-mail:debasarma@creighton.edu

References

1. Ramesh V, Iyengar B. Proliferating trichilemmal cysts over the vulva. *Cutis*. 1990;45(3):187-9.
2. Yamaguchi J, Irimajiri T, Ohara K. Proliferating trichilemmal cyst arising in the arm of a young woman. *Dermatology*. 1994;189(1):90-2.
3. Gray Y, Tibbetts LM. Pathologic quiz case. A nodule on the back. Pathologic diagnosis: proliferating trichilemmal tumor. *Arch Pathol Lab Med*. 2000;124(8):1237-8.
4. Ikegami T, Kameyama M, Orikasa H, Yamazaki K. Trichilemmal cyst in the pulp of the index finger: a case report. *Hand Surg*. 2003;8(2):253-5.
5. Brownstein MH, Arluk DJ. Proliferating trichilemmal cyst: a simulant of squamous cell carcinoma. *Cancer*. 1981;48(5):1207-14.
6. Amaral AL, Nascimento AG, Goellner JR. Proliferating pilar (trichilemmal) cyst. Report of two cases, one with carcinomatous transformation and one with distant metastases. *Arch Pathol Lab Med*. 1984;108(10):808-10.
7. Ye J, Nappi O, Swanson PE, Patterson JW, Wick MR. Proliferating pilar tumors: a clinicopathologic study of 76 cases with a proposal for definition of benign and malignant variants. *Am J Clin Pathol*. 2004;122(4):566-74.
8. Ruttly GN, Richman PI, Laing JH. Malignant change in trichilemmal cysts: a study of cell proliferation and DNA content. *Histopathology*. 1992;21(5):465-8.
9. Herrero J, Monteagudo C, Ruiz A, Llombart-Bosch A. Malignant proliferating trichilemmal tumours: an histopathological and immunohistochemical study of three cases with DNA ploidy and morphometric evaluation. *Histopathology*. 1998;33(6):542-6.

Author Information

Poonam Sharma, M.D.

Department of Pathology, Creighton University Medical Center

Deba P. Sarma, M.D.

Department of Pathology, Creighton University Medical Center