

# Intraabdominal Ruptured Hydatid Cyst In A Pregnant Woman During First Trimester

S R, N M, A S, M AR, S A, M M, M M, S F

## Citation

S R, N M, A S, M AR, S A, M M, M M, S F. *Intraabdominal Ruptured Hydatid Cyst In A Pregnant Woman During First Trimester*. The Internet Journal of Surgery. 2009 Volume 25 Number 2.

## Abstract

Hydatid disease, also known as echinococcosis or hydatidosis, is a parasitic infection caused by the larval stage of two species of the tapeworms (echinococcus). Hydatosis is endemic in the Mediterranean region. Patients with hydatosis are almost asymptomatic and the liver is the organ most frequently involved. Because of infrequent and masked symptoms in pregnancy, misdiagnosis may happen when a pregnant patient comes with abdominal pain and may lead to critical situations. One of the dangerous complications is anaphylactic shock which may cause death. In this case, we present an 11 weeks pregnant patient who was admitted with abdominal pain followed by anaphylactic shock and treated with emergent laparotomy. So, in conclusion, it is important to consider the hydatid cyst as one of the important differential diagnoses of abdominal pain during pregnancy in endemic regions.

## INTRODUCTION

Hydatid disease, also known as echinococcosis or hydatidosis, is a parasitic infection caused by the larval stage of two species of tapeworms (Echinococcus): *E. granulosus* (cystic hydatid disease) and *E. multilocularis* (alveolar hydatid disease). The former is endemic in several areas, mostly in sheep-raising communities such as South America, Mediterranean countries, Russian Federation, Middle East, and Central Asia (1). Hydatid disease may develop in almost all parts of the body. The overall incidence of organ involvement is greatest in liver (50%-77%) and lungs (8.5%-43%) (2). Patients with hydatid disease are mostly asymptomatic (3), but perforation into the abdominal cavity may result in dangerous complications causing anaphylaxis and sudden death (4). Pregnancy could induce hydatid symptoms which may be attributable to decreased cell-mediated immunity during gestation (5). There is no standardized recommended treatment. Because of the teratogenic potency of chemotherapy such as mebendazole or albendazole (6,7) surgical treatment is the choice. We present a primigravid patient with acute abdomen followed by anaphylactic shock, which pointed out rupture of hydatid cyst as one of the important differential diagnoses of abdominal pain in pregnancy and the necessity of its surgical treatment.

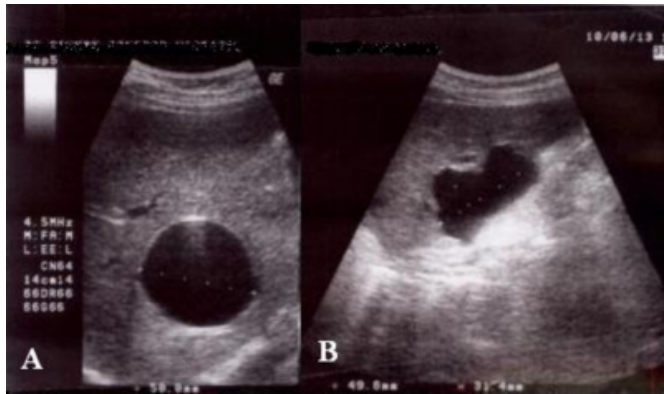
## CASE REPORT

A 24-year-old female, 11 weeks pregnant, was admitted in the emergency department with right lower quadrant (RLQ) and right flank pain for more than ten hours. The pain had started suddenly, worsened progressively and was accompanied by nausea and two episodes of non-biliary vomiting. The patient mentioned close contact with dogs and sheep in recent months. There was no history of trauma, diarrhea, urinary dysuria and fever accompanying the abdominal pain. She complained of fatigue and weakness for one week. Physical examinations revealed severe RLQ tenderness, and mild supra-pubic and right costo-vertebral-angle tenderness with stable vital sign. No palpable mass was detected on abdominal examination. Hematological investigation was normal, but there was moderate bacteriuria with 20-25 white blood cells detected in urine analysis. An ultrasound examination revealed two simple cysts, located in the anterior region of both liver lobes, and one multi-cystic septated cyst in the right lobe just beneath the diaphragm (Figure 1). A live fetus with normal heart rate and activity with a gestational age of 11 weeks and 4 days was detected in the uterus. Nearly 150cc of free liquid in Morrison's pouch and in the pelvic cavity was also reported. Although there was no change in the hemoglobin level, three hours after admission the systolic blood pressure dropped below 90 mmHg and some features of anaphylaxis such as tachycardia, peripheral vasodilation, altered mental status,

and skin hot flash were seen. Hydration and other required medication was rapidly administered and because of persistent progressive pain accompanying the above findings, the patient was transferred to the operating room for emergent laparotomy.

### **Figure 1**

Figure 1: Ultrasound scan showing an intact cyst within the anterior aspect of the liver (A) and a ruptured cyst beneath the diaphragm (B).

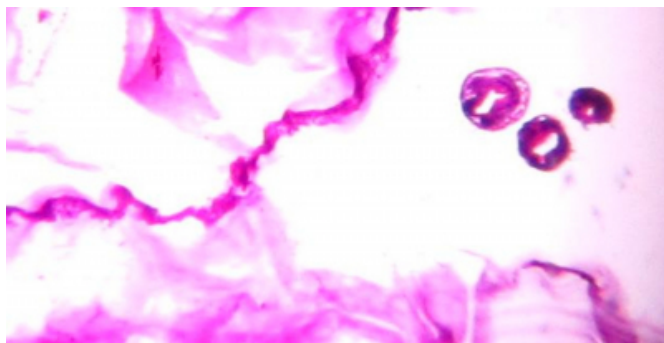


### **SURGICAL TECHNIQUE**

Under general anesthesia the abdominal wall was opened via midline incision and yellowish liquid with white debris was seen in the paracolic and pelvic regions. After cutting the triangular and coronary ligament, the liver was mobilized and a large perforated cyst in segment 7 of the liver was found, consistent with the diagnosis of hydatidosis. The perforated cyst bed was washed with hypertonic saline 20%. For a small intact cyst at the anterior side of the right lobe, aspiration and hypertonic saline injection was done. After un-roofing the cyst, the bed was also washed and omentoplasty was done. Another intact cyst (anterior side of left lobe) was completely resected. Finally the abdominopelvic cavity was totally washed.

### **Figure 2**

Figure 2: Microscopic evaluation of the cyst (H&E, x400)



### **POST OPERATION FOLLOW-UP**

An immediate ultrasonography after surgery confirmed a live fetus with normal heart rate and activity. Pathological examination as well as serologic assay confirmed hydatidosis (Figure 2). During hospitalization there was no biliary leakage and the drain was removed. Four days after surgery the patient was discharged with antibiotics and albendazole. After 3 month of follow-up, both patient and fetus are healthy and asymptomatic

### **DISCUSSION**

The perforation of a hydatid cyst into the peritoneal cavity may cause mild abdominal pain which may be masked with normal pregnancy symptoms but it could lead to fatal complications like anaphylaxis and sudden death (4). The perforation rate of hepatic hydatidosis into abdominal cavity is approximately 3.2% and this condition should be treated by emergent surgery (8). Abdominal pain is the prominent symptom in perforated hydatid cyst, but the signs and symptoms are not always severe (9) and this may cause mistakes by physicians. Nausea, jaundice and macular eruption are the most common symptoms. A preoperative diagnosis is made in half of the patients (10). A definitive preoperative diagnosis is often difficult without histologic examination. The Casoni intradermal and complement fixation tests are not specific. Immunological assays are now being used for detection of specific antibodies, circulating antigen and immune complexes. However, there is no test that is highly sensitive and specific, particularly for cystic hydatid disease (11). ELISA using crude hydatid cyst fluid has high sensitivity but low specificity. Purified antigen or other techniques (immunoblot analysis, detection of Ig4 antibodies, immunoelectrophoresis, etc.) are used, the specificity improves, but the sensitivity gets worse. Therefore it is suggested that at least two methods are combined in the serological diagnosis of cystic echinococcosis. In our patient, because of required emergent surgery and lack of high index of suspicion of echinococcosis, the ELISA test was not done and we had to do a diagnostic laparotomy as supported by Saglam's report. (12).

The clinical presentation and infrequency of hydatid cyst perforation has been considered partially responsible for misdiagnosis by surgeons (13), but some patients may be misdiagnosed because of no abdominal pain (14). Actually, the main symptom in our case was RLQ tenderness. It may be caused by some conditions during pregnancy such as appendicitis, ectopic pregnancy, and ovarian torsion. It is

important to consider diagnosis of other rare diseases in pregnant patients with abdominal pain based on clinical and paraclinic data. Misdiagnosis of ruptured hydatid cyst may increase in pregnancy; therefore, the main purpose of this report firstly was to highlight the possibility of such a diagnosis in pregnant patients with acute abdominal pain and secondly we showed the main role of an emergent operation in these patients.

Albendazole is among the category C of drugs approved for use in pregnancy. The physician may administer the drug if convinced that the benefit for the patient outweighs the potential harm to the fetus. Albendazole may be more safely administered if the organogenesis of the fetus is completed (15).

## **CONCLUSIONS**

We pointed out rupture of hydatid cyst as one of the important differential diagnoses in abdominal pain during pregnancy and the necessity of its surgical treatment. Public health measures should be adopted to eradicate infected animals and dogs in order to break the cycle of transmission.

## **ACKNOWLEDGMENT**

The authors are thankful to Dr Amir H. Davarpanah Jazi and Dr Hamidreza Shemshaki (Isfahan University of Medical Sciences) who helped us in editing this report. The authors also thank Mr Hasan Ajam who facilitated data collection.

## **References**

1. Lewis J WJr, Koss N, Kerstein MD: A review of echinococcal disease. *Ann Surg*; 1975; 181: 390-6.
2. Kammerer WS: Echinococcosis affecting the central nervous system. *Semin Neurol*; 1993; 13: 144-7.
3. Sayek I, Onat D: Diagnosis and treatment of uncomplicated hydatid cyst of the liver. *World J Surg*; 2001; 25: 21-7.
4. Dericci H, Tansung T, Reyhan E, Bozdog AD, Nazli O: Acute intraperitoneal rupture of hydatid cyst. *World J Surg*; 2006; 30: 1879-83.
5. Kain KC, Keystone JS: Recurrent hydatid disease during pregnancy. *Am J Obstet Gynecol*; 1988; 159: 1216-1217.
6. Wen H, New RRC, Craig PS: Diagnosis and treatment of human hydatidosis. *Br J Clin Pharm*; 1993; 35: 565-74.
7. Morris DL, Dyke PW, Mariner S, et al.: Albendazole: objective evidence of response in human hydatid disease. *JAMA*; 1985; 253: 2053-7.
8. Placer C, Martin R, Sanchez E, Soleto E: Rupture of abdominal hydatid cysts. *Br J Surg*; 1998; 75: 157-61.
9. Ozturk G, Aydinli B, Yildigam MI, Basoglu M, Atamanalp SS, Polat KY, Alper F, Guvendi B, Akcay MN, Oren D: Posttraumatic free intraperitoneal rupture of liver cystic echinococcosis: a case series and review of literature. *Am J Surg*; 2007; 194: 313-6.
10. Booz MY: The value of plain film findings in hydatid disease of bone. *Clin Radiol*; 1993; 47: 265-8.
11. Siracusano A, Buttari B, Delunardo F, et al.: Critical points in the immunodiagnosis of cystic echinococcosis in humans. *Parasitologia*; 2004; 46: 401-3.
12. Saglam A: Laparoscopic treatment of liver hydatid cysts. *Surg Laparosc Endosc*; 1996; 6: 16-21.
13. Patel SS, But AA: Inadvertent rupture of echinococcal cyst: case report and review of literature. *Am J Med Sci*; 2004; 327: 268-71.
14. Dirican A, Unal B, Ozgor D, Piskin T, Aydin C, Sumer F, Kayaalp C: Perforated hepatic hydatid cyst into the peritoneum with mild symptoms. *Case Rep Gastroenterol*; 2008; 2: 439-43.
15. Pallua K, Putz G, Mitterschiffthaler G, Brezinka C, Biebl M, Paal P: Management of hepatic echinococcosis in pregnancy. *Int J Gynaecol Obstet*; 2010; 109(2): 162.

**Author Information**

**Sobhani R**

Assistant Professor of Surgery, Gonabad University of Medical Sciences

**Noori Daluei M**

Assistant Professor of Surgery, Gonabad University of Medical Sciences

**AlSaeidi S**

Resident of Internal Medicine, Isfahan University of Medical Sciences

**Mahmoudabadi AR**

Assistant Professor of Radiology, Gonabad University of Medical Sciences

**Sadeghi A**

Assistant Professor of Pathology, Gonabad University of Medical Sciences

**Movahedi M**

Assistant Professor of Obstetrics and Gynecology, Isfahan University of Medical Sciences

**Mahmoudieh M**

Assistant Professor of Surgery, Isfahan University of Medical Sciences

**Sobhani F**

General Practitioner, Gonabad University of Medical Sciences