

Reinforced Distal Hypostadiac Urethroplasty with Nesbit's and Byar's Flaps

R Singh., S Dalal.

Citation

R Singh., S Dalal.. *Reinforced Distal Hypostadiac Urethroplasty with Nesbit's and Byar's Flaps*. The Internet Journal of Urology. 2009 Volume 6 Number 2.

Abstract

To evaluate the role of Nesbit's and Byar's type of soft tissues reinforcement interposition flaps (STRIFs) in prevention of urethro-cutaneous fistulas (UCFs) in distal Snodgrass TIP urethroplasties. Between 2003-2005, 28 distal hypospadiacs, ranging from 8 to 14 years of age, without chordee, underwent Snodgrass TIP urethroplasties. The reconstructed neo-urethras were reinforced with preputial dartos fascial flaps, harvested by way of de-epithelialization. The de-epithelialized dorsal prepuce was either button holed (n=14, Nesbit' type of STRIFs) or divided in to two equals halves (n=14, Byar's type of STRIFs) to be ventralized and tucked under the glans wings distally to provide a complete cover to the neo-urethras. Total of four patients, two from each group, developed single, micro-sized coronal urethro-cutaneous fistula three of which healed spontaneously within a period of 6 weeks, and one required purse string closure after 3 months. At one year follow up, all the patients were asymptomatic with good functional and cosmetic out come.

INTRODUCTION

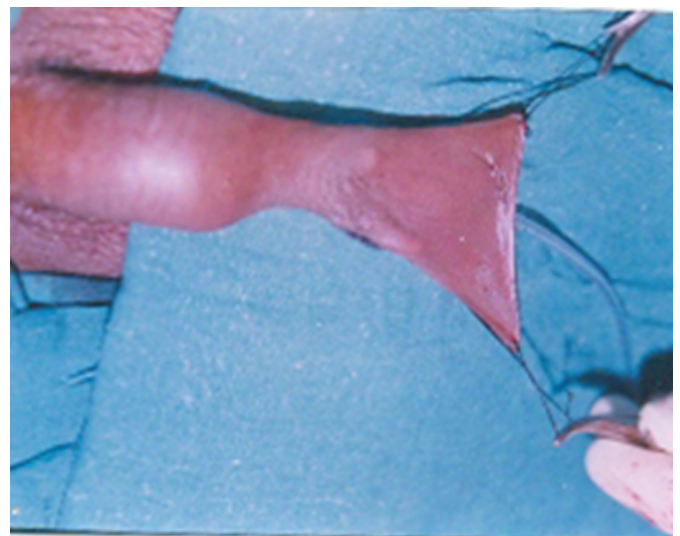
Hypospadiac surgery has evolved with more than 150 procedures for surgical correction of single anomaly. The tubularised incised plate (TIP) urethroplasty or Snodgrass procedure has gained worldwide acceptance for distal hypospadias repair due to its low complication rate and technical simplicity. Urethro-cutaneous fistulas (UCFs) formation is the commonest post-operative complication which is encountered following any of the techniques of the hypospadiac urethroplasty even in the hands of expert hypospadiologists. Etiology of UCFs is multifactorial. Different soft tissue reinforcement interposition flaps (STRIFs) have been described in literature to prevent fistulization in primary and re-do hypospadiac urethroplasties.¹

PATIENTS AND METHODS

Between 2003-2005, 28 boys aged between 8 to 14 years presenting with distal hypospadias without chordee underwent Snodgrass TIP urethroplasties. Reinforcement of the neo-urethral tubes (neo-urethras) was done either with Nesbit's (n=14) or with Byar's (n=14) type of STRIFs. The redundant prepuce was anchored with stay sutures (Fig. 1)

Figure 1

Fig. 1 Redundant prepuce



and was infiltrated on either side with 1:200,000 adrenaline solution to facilitate hemostasis and removal of it's outer and inner skins (misnomered as de-epithelialization). The prepuce was stabilized with fingers and thumb of one hand, and the de-epithelialization was carried out with the other hand using a pair of sharp scissors. After de-epithelialization of both surfaces of the preputial hood, a highly vascular, wide and thick dartos fascial flap (Fig.2) was created dorsally, which was then ventralized to reinforce the neo-

urethra either by it's mid line button holing i.e. Nesbit's type (Fig. 3) or by it's midline vertical division i.e. Byar's type (Fig. 4).

Figure 2

Fig. 2 Preputial dartos fascial flap.

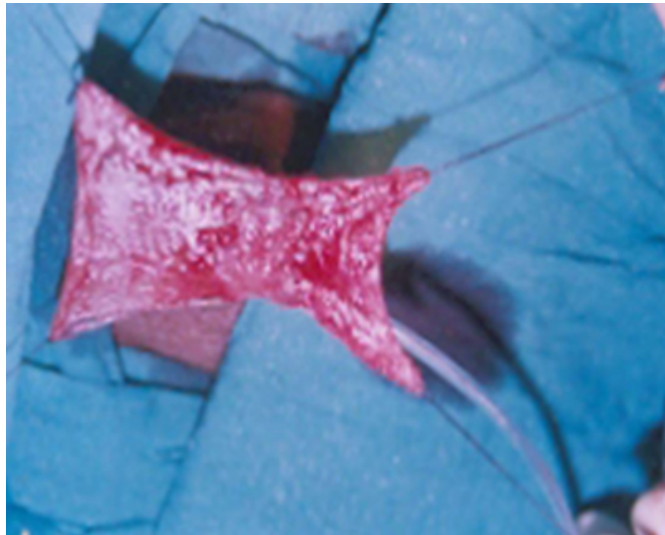


Figure 3

Fig. 3 Midline button holing (Nesbit's type)

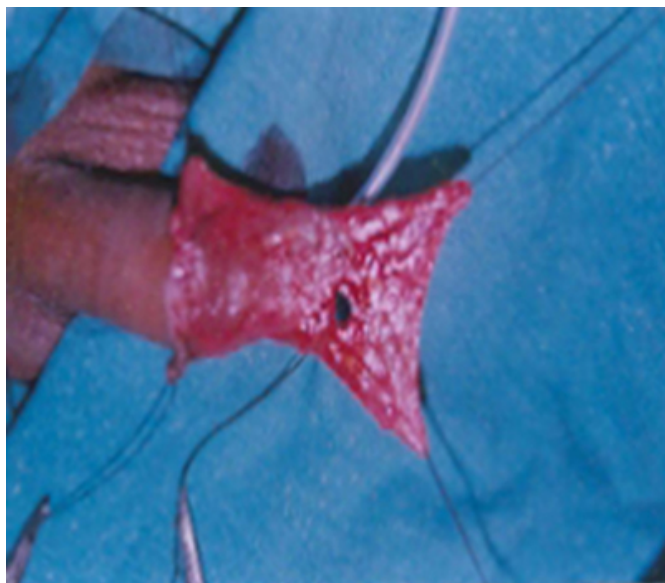
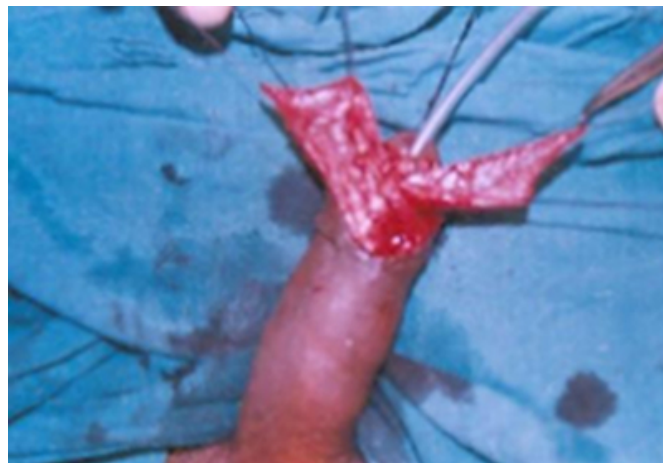


Figure 4

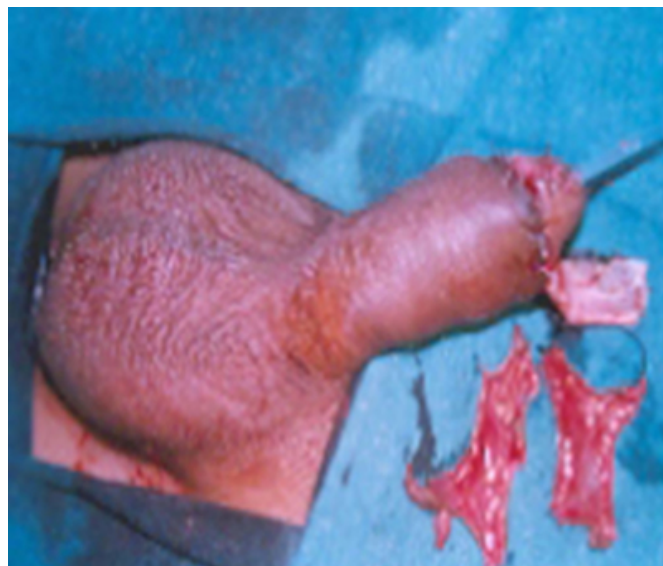Fig. 4 Midline division (Byar's type) and Ventralization



The ventralized soft tissue reinforcement interposition flap (STRIF) was sutured to cover whole of the neo-urethra starting from underneath the glans wings distally and up to the native urethra proximally using few 6-0 vicryl tucking sutures. Excess of the flap was excised to avoid unnecessary reposition of too much of the dartos fascial flap underneath the glans wings so as to get rid of the glans closure under tension and it's drum stick appearance. Penile skin was sutured all-round the corona to give a circumcised look (Fig. 5).

Figure 5

Fig. 5 Final closure having circumcised look



All the patients were catheterized with number 10 infant feeding tube which was removed on 14th postoperative day. Intravenous antibiotic i.e. Cefotaxime and Amikacin were given to all the babies for initial three days followed by

dispersible cefexime tablets for further one week.

RESULTS

Four patients had formation of micro-sized, eccentrically placed coronal urethro-cutaneous fistulas (UCFs), out of which three healed spontaneously 6 weeks after the removal of urethral tube. In one patient operative intervention was required in form of purse string closure without catheterization as a day care procedure. None of the patient developed dehiscence of suture line, stenosis or stricture. At 6 weeks follow-up, all patients of Nesbit's flaps were healthy while one patient of Byar's type flap had micro-UCF, which required subsequent surgical closure. At one year follow-up results of both types of flaps were comparable and all patients had good functional and cosmetic results.

DISCUSSION

Simple hypospadiac urethroplasties without the interposition of STRIFs have higher incidence of multiple, macro-sized and mid line neo-urethral-superimposed UCFs. Such unsupported UCFs superimposed on thin walled neo-urethras with deficient peri-fistular soft tissues remain either of the same size or may even increase in size and also are more prone to early epithelialization, thus necessitating subsequent surgical closures. In reinforced-hypospadiac urethroplasties, the UCFs associated morbidity has decreased in terms of singular, micro-sized and eccentrically placed UCFs, thus helping in their spontaneous closures as the oblique tracts find difficulties in their epithelialization. The subsequent closure of the UCFs in well supported thick walled neo-urethras is also made easy because of the presence of the previously banked soft tissues, which facilitate their safe dissection and multilayered closure. Further, the harvesting of such highly vascular STRIFs having axial pattern of the vascularity (superficial external pudendal vessels) is an additional utility of the otherwise redundant prepuce, which invariably is discarded in most of the distal hypospadiacs unless a preputial re-construction is contemplated.

Developing interest in the understanding of the morbid anatomy and pathology of hypospadias, expertization in different surgical techniques, strict compliance of the basic principles of plastic surgery and gentle tissue handling with fine atraumatic instruments is essential to decrease complications rate in hypospadias surgery. Super-added reinforcement of hypospadiac urethroplasties by different STRIFs like preputial dartos flap,^{2,5} penile dartos flap,⁶ peno-

preputial dartos flap,⁷ scrotal dartos flap,⁸ corpus spongiosum flap⁹ and tunica vaginalis flap^{4,10,11} have markedly reduced fistulas and re-fistulas associated morbidities that were prevalent in the past. In this study we have compared the results of preputial dartos flaps of Nesbit's or Byar's type and results of both techniques were comparable at one year follow-up. These STRIFs could be classified as: random flaps (triangular soft tissue², D Smith⁶ and corpus spongiosum⁹ flaps) or axial flaps (tunica vaginalis^{4,10,11}, Belman's⁵, Nesbit's type and Byar's type flaps) depending on their pattern of the vascularity. The reinforcing flaps should be sutured without tension and be carefully placed all around the re-constructed neo-urethras and uniformly sandwiched between the underlying neo-urethras and the overlying covering skin. STRIFs provide: eccentric suture line closures; mechanical barrier to the leakage of urine; additional vascularity and neo-angiogenesis for better healing; biological drain for edema fluid absorption; filling of dead spaces to prevent seroma or hematoma formation. In addition abundant peri-fistular soft tissues in the vicinity of the UCFs produce oblique leaking tracts favouring spontaneous healing or subsequent multi-layered closures.⁴

CONCLUSION

Reinforcement of the neo-urethra by preputial flaps of Nesbit's or Byar's type prevents fistula-associated morbidities in distal Snodgrass TIP urethroplasties and use of such STRIFs is highly recommended for all hypospadiac urethroplasties.

References

1. Singh RB, Dalal S, Pavithran NM, Sharma BD. Soft tissue reinforcement interposition flaps (STRIFs) in hypospadias repair. *Ind J Plast Surg* 2007; 40(2): 170-77.
2. Singh RB, Pavithran NM. Partially de-epithelialized preputial flap (triangular soft tissue flap): an aid to prevent coronal urethrocuteaneous fistulae. *Pediatr Surg Int* 2003; 19: 551-3.
3. Churchill BM, Savage JGV, Khoury AE, Mc Lorie GA. The dartos flap as an adjunct in preventing urethrocuteaneous fistulas in repeat hypospadias surgery. *J Urol* 1996; 156: 2047-9.
4. Singh RB, Pavithran NM. Tunica vaginalis interposition flap in the closure of massive disruption of the neourethral tube (macro urethrocuteaneous fistulae). *Pediatr Surg Int* 2004; 20: 464-6.
5. Belman AB. De-epithelialized skin flap coverage in hypospadias repair. *J Urol* 1998; 140:1273-6.
6. Smith D. A de-epithelialized overlap flap technique in the repair of hypospadias. *Br J Plast Surg* 1973; 26:106-14.
7. Retik AB, Mandell J, Bauer SB, Atala A. Meatal based hypospadias repair with the use of a dorsal subcutaneous flap to prevent urethrocuteaneous fistula. *J Urol* 1994; 152:1229-31.
8. Motiwala HG. Dartos flap: an aid to urethral

reconstruction. Br J Urol 1993; 72:260-2.

9. Yerkes EB, Adams MC, Miller DA, Pope JC 4th, Rink RC, Brock JW 3RD . Y - to - 1 wrap: use of the distal spongiosum for hypospadias repair. J Urol 2000; 163:1536-8.

10. Snow BW, Cartwright PC, Unger K. Tunica vaginalis

blanket wrap to prevent urethrocutaneous fistula: an 8-year experience. J Urol 1995; 153:472-3.

11. Kirkali Z. Tunica vaginalis: an aid in hypospadias surgery. Br J Urol 1990; 65: 530-2.

12. Snodgrass W. Tubularized incised plate urethroplasty for distal hypospadias. J Urol 1994; 151: 464-5.

Author Information

R.B. Singh., MS,MCh.

Senior Professor & Head Department of Plastic Surgery and Hypospadias & VVFs Clinic, Pt. B.D. Sharma Postgraduate Institute of Medical Sciences

S. Dalal., MS

Associate Professor Department of Surgery, Pt. B.D. Sharma Postgraduate Institute of Medical Sciences