

Traumatic Abdominal Wall Hernia: Open And Laparoscopic Approaches To Repair

H Tiong, J So, W Cheah

Citation

H Tiong, J So, W Cheah. *Traumatic Abdominal Wall Hernia: Open And Laparoscopic Approaches To Repair*. The Internet Journal of Surgery. 2006 Volume 10 Number 2.

Abstract

INTRODUCTION

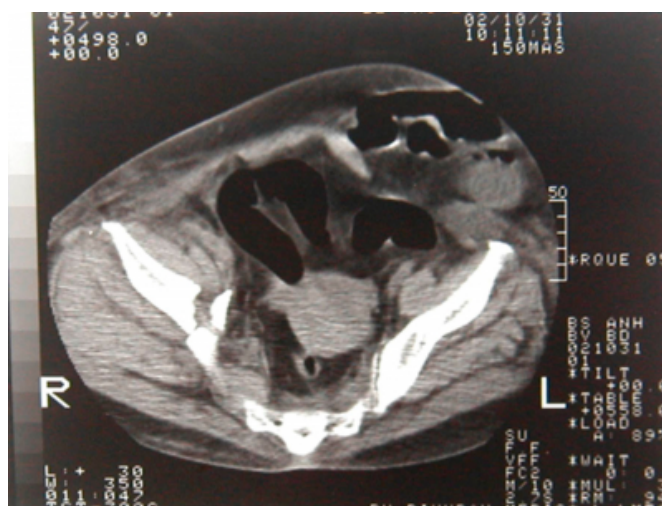
Traumatic abdominal wall hernia is an uncommon injury despite the high prevalence of blunt abdominal trauma. Traumatic abdominal hernia was first described by Selby in 1906 and to date, fewer than 60 cases have been reported [1]. Factors that need to be considered are the different patterns of abdominal muscular wall disruption, its association with significant intraabdominal injury, and the timing and types of surgical repair. We report 2 cases of traumatic abdominal wall hernia, using two different surgical approaches, and discuss various methods of optimal management.

CASE REPORT 1

A 54-year-old woman fell from a five storey building whilst trying to climb down a water pipe outside the building to escape a fire in the building. She had landed on her right side and sustained fractures to her right 6th to 9th ribs, a right haemothorax, and fractures to her right iliac wing and pubic rami. She also had bruising and a tender swelling over her left abdominal iliac fossa, contralateral to where she had fallen on. She was obese and her abdomen was moderately distended; bowel sounds were present. As she remained cardiovascularly stable, a computer tomographic (CT) scan of the abdomen and pelvis was performed. This revealed a defect in the left lower abdominal wall with protrusion of intestinal loops into the subcutaneous fat plane (Figure 1). This was associated with small bowel distension as a result of partial intestinal obstruction from the hernia. No solid organ injury was detected but some free fluid was present within the pelvis.

Figure 1

Figure 1: Abdominal CT scan showing disruption of the lateral abdominal wall and herniation of intestinal loops.

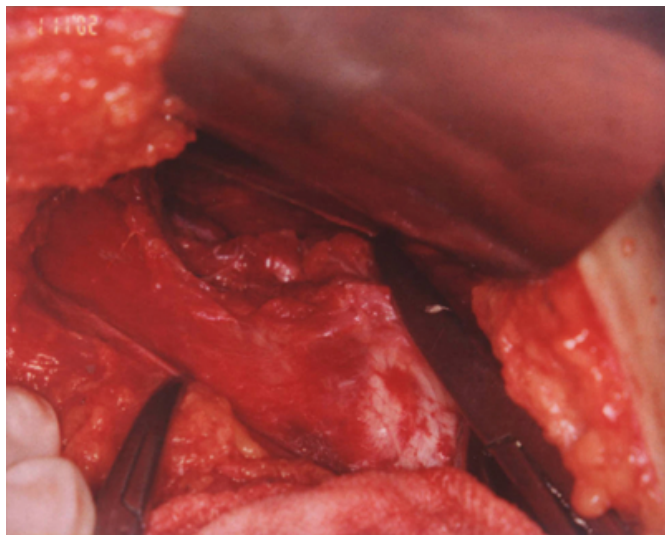


An exploratory laparotomy was performed through a midline incision. At laparotomy, a traumatic hernia was present. To define the edges of the defect, the subcutaneous tissue of the anterior abdominal wall was dissected off the anterior rectus sheath and fascial layer to reveal a 20 cm linear tear running longitudinally along the direction of the fibers of the left external oblique aponeurosis and to a lesser extent, the rectus sheath (Figure 2). There was an 8 cm wide gap on the aponeurotic side with underlying muscle disruption and a 6 cm tear in the peritoneum. Small bowel loops were trapped within the defect, but these could be easily reduced. Following reduction, the peritoneal defect was repaired with a continuous 2/0 Vicryl (Ethicon, Johnson & Johnson) suture. The fascial defect was then repaired primarily using 1/0 prolene (Ethicon, Johnson & Johnson) continuous suture to the external oblique aponeurosis. Closed suction drains were inserted into the muscular and subcutaneous planes. The other associated findings were a 4 cm serosal tear in the

sigmoid colon that was repaired and a small stable haematoma arising from the pelvic fracture.

Figure 2

Figure 2: Photograph showing the defect in the external oblique aponeurosis with underlying muscle disruption and contusion. The artery forceps indicate the edges of the defect.



Post-operatively, the patient recovered without any complications. Her orthopaedic injuries were managed non-operatively.

CASE REPORT 2

A 30-year-old construction worker was admitted to hospital following a fall from a height of 30 feet. He sustained a penetrating injury from a 2 cm thick metallic rod to the left chest wall with the entry point over the left deltopectoral region 2 cm below the clavicle, as he landed on the left side of his body. His airway was patent, there was no injury to the neck, and air entry to both lungs was equal with no pneumothorax or haemothorax on the chest X-Ray. He was haemodynamically stable and examination of his abdomen revealed bruising and a 3 cm tender swelling over the right iliac fossa without any laceration to the skin. The rest of the abdomen was soft and non-tender. All pulses were present in the left upper limb and neurological examination was normal. Thoracic, abdominal and pelvic CT scan showed penetration of the metallic rod through the left axilla but it lay external to the ribs and chest cavity, with the tip of the rod embedded in the subcutaneous plane. In the abdomen, there was a defect in the abdominal wall fascia over the right iliac fossa, with herniation of small intestine into the subcutaneous tissue. No solid organ injury was demonstrated but there was a small amount of free fluid around the liver.

As there was no evidence of serious underlying intra-abdominal injury, a diagnostic laparoscopy was performed via a 10 mm umbilical port and a 5 mm port in the left iliac fossa to determine the nature of the traumatic hernia and the free peritoneal fluid, and also to identify any missed injury to organs within the peritoneal cavity. A 5cm defect in the right external oblique aponeurosis was identified and this would have allowed a laparoscopic-assisted or directed repair by placing a small skin incision directly over the hernia site. The herniated small bowel loop was viable and easily reduced.

However, in view of the relative urgency of exploring the shoulder wound and removing the metal foreign body, it was planned to repair the hernia in a semi-elective setting the following day. The metal rod was removed without any complication. The next day, the hernia was repaired by suturing the peritoneum with an absorbable continuous suture and by suturing the external oblique aponeurosis with a non-absorbable continuous suture. Post-operatively, he recovered and was well.

DISCUSSION

The criteria for traumatic abdominal wall hernia, as defined by both Cain and Damschen include immediate appearance of the hernia through disrupted muscle and fascia after blunt abdominal trauma, and failure of the injury to penetrate the skin [2, 3]. The pathophysiology, as proposed by Gauchi, involves the application of a blunt force to the abdomen over an area large enough to prevent penetration of the skin; the tangential forces resulting in a pressure-induced disruption of the abdominal wall muscles and fascia, allowing subcutaneous herniation of abdominal viscera through the defect [4]. The skin is more elastic than the underlying structures and therefore remains intact. Clinically, the physical findings include subcutaneous swelling, bruising and ecchymosis of the abdominal wall [5]. There is often tenderness with associated edema that prevents accurate palpation of the fascial edges. CT scan provides the definitive diagnostic tool and differential diagnoses include hematoma of the rectus sheath, a pre-existing abdominal wall hernia and an abdominal wall tumor. The location of the defect is often poorly correlated with the site of impact, and is usually found at anatomically weak points in the lower abdomen, lateral to the rectus sheath and the inguinal region. In a review of 28 cases, 23 occurred in the lower quadrants, with just over half on the left lower quadrant [3]. Both of the cases reported above are consistent with this finding. Furthermore, the cases illustrate the point that a

sudden rise in intraabdominal pressure during impact caused a contralateral or contre-coup injury of the abdomen that resulted in a splitting of the fibres, in both cases, of the external oblique aponeurosis.

It is also important to note that traumatic abdominal wall hernia can be associated with significant intraabdominal injuries in up to 60% of cases [4]. Focal herniae with a small defect due to direct injury from bicycle handle bar impacts have a lower incidence of associated injuries compared with diffuse impact from pressure and shear injuries of road traffic accidents (10% vs. 60%) [4]. CT scan can be useful, in addition to diagnosing the hernia, for evaluating intraabdominal solid organ injury. It is, however, not reliable in cases where hollow viscus injury or mesenteric tears are suspected. Hence, early surgical exploration has been advocated to avoid complications due to undiagnosed intra-abdominal injuries or incarceration of bowel loops. A sufficient exposure of the abdominal cavity is best achieved with a midline laparotomy to detect and manage associated injuries. However, a large fascial defect in the lateral abdominal quadrants may be inaccessible from a midline incision for optimal debridement of devitalized and contaminated tissue and to adequately expose the fascial defect edges for repair. Therefore an incision overlying the muscular defect has been advocated to accurately repair the hernia [8]. In the first case report, instead of extending the incision laterally, the defect was exposed by dissecting the subcutaneous fat off the abdominal wall, which provided adequate room for hernia repair.

To achieve both the aims of intraabdominal injury evaluation and adequate exposure for hernia repair, laparoscopy can be used, as illustrated in the second case report. The use of laparoscopy in the trauma setting has previously been evaluated as a safe method for assessing patients with both blunt and penetrating abdominal trauma, thus reducing the number of negative or non-therapeutic laparotomies [9]. This is particularly suitable in patients who are haemodynamically stable and with equivocal CT scans, as in the second patient above. In addition to preventing negative laparotomies, it also facilitates the accurate positioning of the skin incision for the repair of the traumatic hernia, allowing a limited incision rather than an unnecessary large incision. Moreover, by using the laparoscopy to rule out any significant intraabdominal injury or strangulated bowel, the traumatic hernia can be repaired in a semi-elective setting if there are other injuries that need to be dealt with more urgently. In the first case report, laparoscopy was not used

due to the presence of bowel obstruction.

Repair of the traumatic hernia should be performed by careful primary approximation of the defect edges, using strong, non-absorbable sutures, as most case reports indicate [3,4,5,6,7]. The use of prosthetic mesh can be applied to large defects arising from denuded or unhealthy tissue or in other instances, where repair has been delayed and the fascial edges have retracted [8]. However, mesh repair is contraindicated in the presence of hollow viscus injury and a contaminated abdomen because of the high risk of mesh infection. The mesh can also be used to reinforce a sutured repair when applied as an onlay graft, lying over the external oblique aponeurosis. However, the recurrence rate for such repairs, whether sutured or mesh repair, is not known.

In conclusion, hernia resulting from blunt abdominal trauma should be suspected in a patient with tender, localized swellings of the abdominal wall. An abdominal CT scan can detect the hernia and any associated intra-abdominal injury. Patients in a stable condition can undergo laparoscopy for diagnostic surveillance as well as to direct an incision over the defect for primary repair.

CORRESPONDENCE TO

Dr. Ho Yee Tiong
Department of Surgery
National University Hospital
5 Lower Kent Ridge Road
Singapore 119074

References

1. Selby CD. Direct abdominal hernia of traumatic origin. *JAMA* 1906;47:1485.
2. Cain A. Traumatic Hernia. *Br J Surg* 1964;51:549.
3. Damschen DD, Landercasper J, Cogbill TH, Stolee RT. Acute traumatic abdominal hernia: case reports. *J Trauma* 1994;36:273-276.
4. Gauchi GA, Orgill DP. Autopenetrating hernia: a novel form of traumatic abdominal wall hernia - case report and review of the literature. *J Trauma* 1996; 41(6):1064-1066.
5. Kilic N, Blakan E, Kristioglu I, Guney N, Dogruyol H. Abdominal wall ruptured by blunt trauma in a child. *Eur J Surg* 2000;166:265-266.
6. Sahdev P, Garramone RR, Desani B, Ferris V, Welch JP. Traumatic abdominal hernia: report of three cases and review of the literature. *Am J Emerg Med* 1992;10:237-241.
7. Chanvitan A. Traumatic abdominal wall hernia: A case Report. *J Med Assoc Thai* 1986;69:341.
8. Drago SP, Nuzzo M, Grassi GB. Traumatic Ventral Hernia: Report of a Case, with Special Reference to Surgical Treatment. *Surgery Today* 1999;29:1111-1114.
9. Smith RS, Fry WR, Morabito DJ, Koehler RH, Organ CH JR. Therapeutic laparoscopy in trauma. *Am J Surg* 1995;170(6):632-636

Author Information

H. Y. Tiong, M.R.C.S.

Department of Surgery, National University Hospital

J. B. Y. So, F.R.C.S.

Department of Surgery, National University Hospital

W. K. Cheah, F.R.A.C.S.

Department of Surgery, National University Hospital