

Synovial Sarcoma On The Anterior Abdominal Wall

I Ozaydin, A Aslaner

Citation

I Ozaydin, A Aslaner. *Synovial Sarcoma On The Anterior Abdominal Wall*. The Internet Journal of Surgery. 2004 Volume 7 Number 1.

Abstract

Synovial sarcoma is a malignant mesenchymal neoplasm which commonly occurs in the extremities of adults. We report a 18-years-old man with synovial sarcoma in the lateral aspect of his anterior abdominal wall. The tumor was treated with total excision and 50Gy of irradiation. Histopathologic examination of the excised tumor revealed a biphasic synovial sarcoma. There was no evidence of local recurrence or distant metastasis of the tumor at follow-up examination 36 months postoperatively.

INTRODUCTION

Synovial sarcoma is a malignant mesenchymal neoplasm which commonly occurs in middle-aged patients (₁). There have been only a few reported cases of synovial sarcoma occurring in infants (_{1,2,3}). We present a rare case of synovial sarcoma on the anterior abdominal wall of a 18-years-old man.

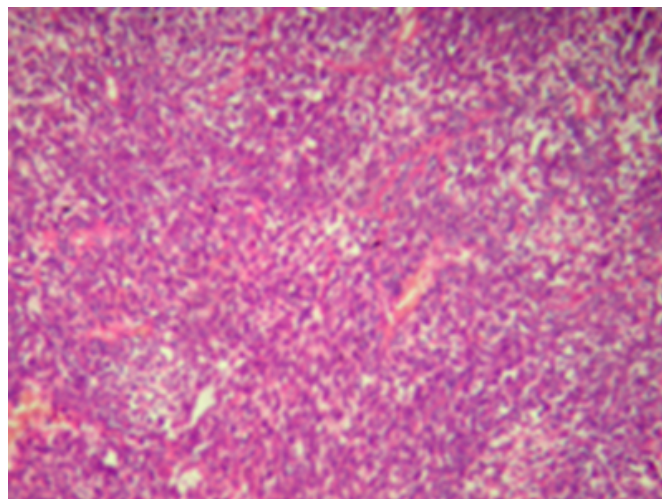
CASE REPORT

A 18-years-old previously healthy man presented with a one-month history of swelling in his right abdominal wall. Physical examination revealed a swelling in the anterolateral aspect of the abdominal wall. A mass 1.0x1.5cm in dimensions had been palpated at that time. Plain radiographs of the abdomen were normal. Magnetic resonance (MR) imaging revealed a soft tissue mass attached to the ankle joint, with low signal intensity on T1-weighted images and high signal intensity on T-2 weighted images. Laboratory data showed no abnormalities. The patient subsequently underwent a total excision of the mass. At surgery, the mass was found to originate from the abdominal wall. A part of the abdominal wall was excised along with the mass.

Grossly, a cross section of the mass, measuring 1.5 cm in diameter, was tan to yellow in color, soft and fragile. Histologically, the tumor predominantly consisted of crowded spindle cells in a wavy or short fascicular pattern. In addition, a multiple pseudoglandular formation lined by flattened epithelioid cells was observed (Fig. 1).

Figure 1

Figure 1: A photomicrograph of biphasic synovial sarcoma shows the spindle and epithelial cell components (hematoxylin and eosin stain, original magnification X200).



The pseudoglands contained amorphous eosinophilic secretions, which stained positively in Periodic Acid Schiff stain. Occasional mitotic figures were seen in the spindle cell elements (2-3 per 10 high power fields).

Immunohistochemical study showed the spindle cells to be positive for vimentin, but the epithelial cells were negative. Keratin, CAM5.2 and epithelial membrane antigen were positive in the epithelial cells, but negative in the spindle cells. Both cell types were negative for desmin. A pathologic diagnosis of biphasic synovial sarcoma was made. The patient was postoperatively given 50 Gy of local irradiation. Since the patient's parents rejected adjuvant chemotherapy, the patient did not receive further treatment. There was no evidence of local recurrence or metastasis 36 months

postoperatively.

DISCUSSION

Synovial sarcoma is a malignant mesenchymal tumor which occurs in close association with joint capsules, tendon sheaths, bursae and fascial structures. It is generally accepted that synovial sarcoma is derived from primitive mesenchymal cells, not synovial cells. Synovial sarcomas predominantly occur in the extremities, head, neck, and trunk. They frequently arise in the 2nd to 5th decades (1). However, synovial sarcomas are extremely rarely encountered in pediatric patients under 2 years of age. In a series of Enzinger and Weiss, there were a 1-year-old child and a 2-year-old child among the 345 patients studied (1). A series by Lee et al. in 1974 included a 20-month-old infant (2). A series by Schmidt et al. in 1991 included a 14-month-old infant (3). Pack and Ariel in 1950 (4), Tillotson et al. in 1951 (5), and Israels et al. in 1984 (6) described exceptional cases of synovial sarcoma in newborns. To our knowledge, there have been fewer than 20 patients under 2 years of age with synovial sarcoma reported in the English literature. Synovial sarcomas in pediatric patients are commonly located in the lower extremity (6,7). Synovial sarcoma should also be included in the differential diagnosis of a malignant neoplasm in the extremities of infants.

Rhabdomyosarcomas and primitive neuroectodermal tumors (PNET) are the most common sarcomas found in the soft tissues of childhood. The present case should be differentiated from these tumors. Immunohistochemically, rhabdomyosarcomas usually express myogenic markers including desmin (1), but the present case was negative for desmin. PNETs are histologically consist of crowded small round cells arranged in sheets, and spindle cells are rarely observed in the tumors (1). In addition, PNETs lack an epithelial component (1).

Synovial sarcomas are histologically divided into monophasic and biphasic types. Monophasic synovial sarcomas predominantly consist of spindle cells resembling fibrosarcoma. Biphasic synovial sarcomas are typically composed of the spindle cell and epithelial cell elements. The present case showed a biphasic pattern, the coexistence of spindle cells in a wavy pattern, and the pseudoglandular formation. In both subtypes, positive immunoreactivity for epithelial markers including keratin, epithelial membrane antigen and CAM 5.2 is demonstrable, more intensely in the epithelial cell component than in the spindle cell component (1). The histological features of synovial sarcoma in children

are reported to be similar those in adults (2,3). Schmidt et al. reported that there was no differences between histologic subtype and prognosis.

In recent years, the specific chromosomal aberration in synovial sarcoma has been reported. The translocation t(X;18)(p11.2; q11.2) is believed to play a causative role in the development of synovial sarcoma (8). This translocation is found in more than 90% of synovial sarcomas. The molecular diagnosis in synovial sarcoma is currently important, as well as immunohistochemical study, especially in cases in which histological diagnosis is difficult.

The multimodality treatment approach has improved the prognosis of children with synovial sarcomas. More preferable prognosis of synovial sarcomas in childhood has been reported than that in adulthood (3). Schmidt et al. reported that the survival rate at 7 years was 73 % (3). Pappo et al. in 1994 described the overall 5-year survival rate in pediatric patients with synovial sarcoma to be 65 % (7). They believe that tumor invasiveness, histologic grade and tumor size significantly correlate with the survival period.

In summary, a rare case of biphasic synovial sarcoma in a 18-years-old boy was presented. Synovial sarcoma enters the differential diagnosis of a malignant lesion in puberty.

In conclusion, in cases of anterior abdominal wall masses, it is important to consider the possibility of a malign tumour; synovial sarcoma.

CORRESPONDENCE TO

Ismet OZAYDIN , MD General Surgery Department Duzce Medical Faculty Abant izzet baysal University Konuralp Duzce Turkey Fax:+90-380-5414105 Tel: +90-380-5414107 e-mail: iozaydin59@yahoo.com

References

1. Enzinger FM, Weiss SW. Synovial sarcoma, Rhabdomyosarcoma, Primitive neuroectodermal tumors and related lesions. 1995. Mosby Year-Book, St. Louis, 757-786, 539-577, 929-963. Soft tissue tumors.
2. Lee SM, Hajdu SI, Exelby PR. Synovial sarcoma in children. Surg. Gynecol. Obstet. 1974 138:701-4.
3. Schmidt D, Thum P, Harms D, Treuner J. Synovial sarcoma in children and adolescents. A report from the Kiel Pediatric Tumor Registry. Cancer 1991 67:1667-2.
4. Pack GT, Ariel IM. Synovial sarcoma (malignant synovioma). A report of 60 cases. Surgery 1950. 28:1047-84.
5. Tillotson JF, McDonald JR, Janes JM. Synovial sarcoma. J. Bone Joint Surg 1951 33A:459-73.
6. Israels SJ, Chan HL, Daneman A, Weitzman SS. Synovial sarcoma in childhood. Am. J. Roentgenol 1984 142:803-6.
7. Pappo AS, Fostanesi J, Luo X, Rao BN, Parham DM,

Hurwitz C et al. Synovial sarcoma in children and adolescents: The St Jude Children's Research Hospital experience. Clin. Oncol 1994 12:2360-6.

8. Fligman I, Lonardo F, Jhanwar SC, Gerald WL, Woodruff J, Ladanyi M. Molecular diagnosis of synovial sarcoma and characterization of a variant SYT-SSX2 fusion transcript. Am. J. Pathol. 1995 147:1592-9.

Author Information

Ismet Ozaydin, M.D.

Assistant Professor, General Surgery Department, Duzce Medical Faculty, Abant Izzet Baysal University

Arif Aslaner, M.D.

Assistant, General Surgery Department, Duzce Medical Faculty, Abant Izzet Baysal University