

Hemoperitoneum From A Leaking Pseudoaneurysm Of The Left Gastric Artery Secondary To A Pancreatic Pseudocyst: A Case Report

A Chendrasekhar, D Perri, P Erachshaw, A Rao

Citation

A Chendrasekhar, D Perri, P Erachshaw, A Rao. *Hemoperitoneum From A Leaking Pseudoaneurysm Of The Left Gastric Artery Secondary To A Pancreatic Pseudocyst: A Case Report*. The Internet Journal of Surgery. 2006 Volume 9 Number 2.

Abstract

Pseudoaneurysms as complications of pancreatic pseudocysts/pancreatitis are rare and potentially lethal (1,2). Pseudoaneurysms of the left gastric artery due to this pathophysiology are extremely rare. Bleeding from pseudoaneurysms has been reported as gastro-intestinal bleeding (1,2). The clinical presentation of bleeding pseudoaneurysm as hemoperitoneum is also extremely rare. We report the case of a leaking left gastric pseudoaneurysm associated with a pancreatic pseudocyst which presented clinically with hypotension and hemoperitoneum.

CASE REPORT

A 61 year old male presented initially with a large pancreatic pseudocyst (7cm X 7cm X 5cm) located posterior to the stomach in the lesser sac. The patient had a history of alcohol induced pancreatitis. The pseudocyst was symptomatic, presenting with epigastric pain, early satiety and nausea. The patient also had an extensive past medical history which included Type 2 diabetes, hypertension, hypercholesterolemia and chronic obstructive pulmonary disease (COPD) due to a 50 pack year smoking history.

The pseudocyst was managed by attempted endoscopic cyst-gastrostomy followed by successful surgical cyst-gastrotomy. Approximately 2 weeks after this surgery, the patient presented with hypotension (systolic BP=70) and maroon colored blood draining from the midline abdominal wound. The patient was taken to the ICU and resuscitated with subsequent stabilization. A CT angiogram (Figures 1,2) was performed revealing a leaking left gastric artery pseudoaneurysm. The patient was then taken to the angiography suite where coil embolization of the pseudoaneurysm was successfully performed (Figure 3,4).

Figure 1

Figure 1: CT scan of left gastric artery pseudoaneurysm

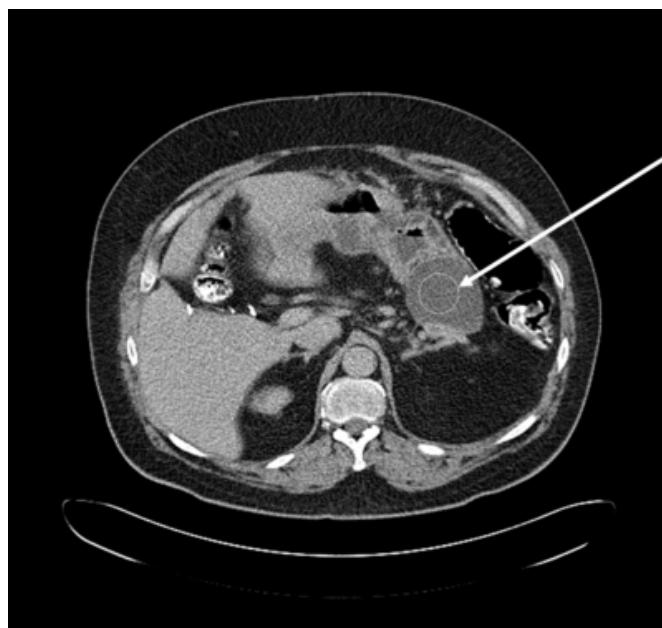

Figure 2

Figure 2: CT scan of left gastric artery pseudoaneurysm

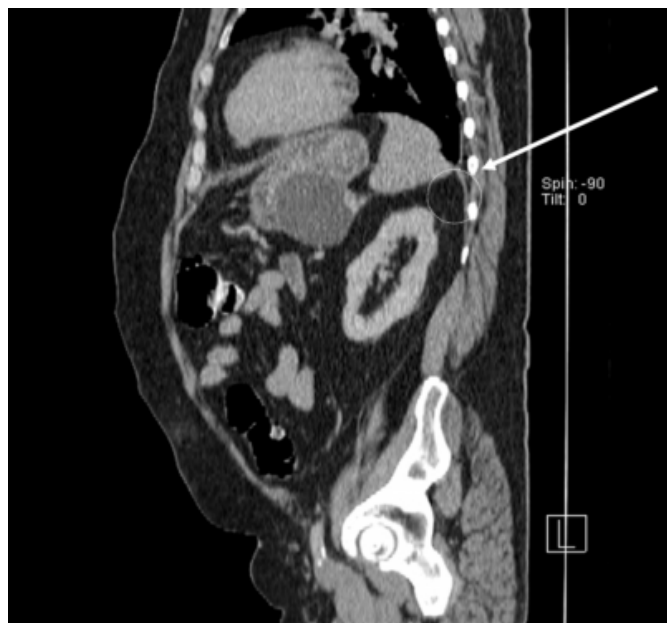

Figure 3

Figure 3: Angiographic embolization of left gastric artery pseudoaneurysm

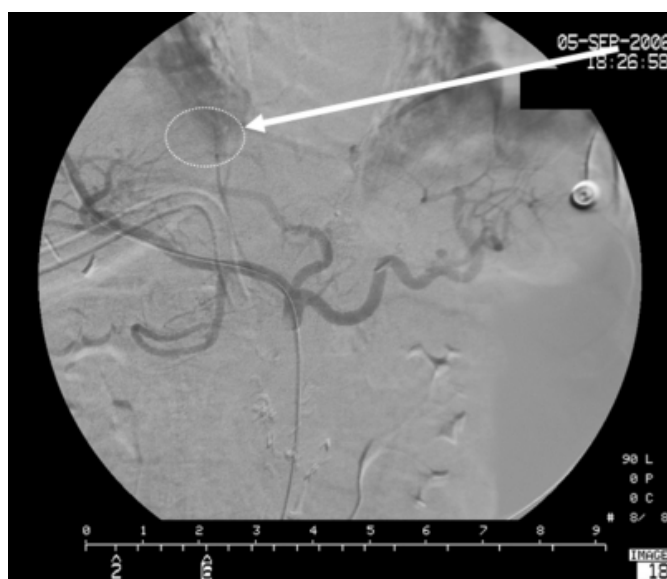
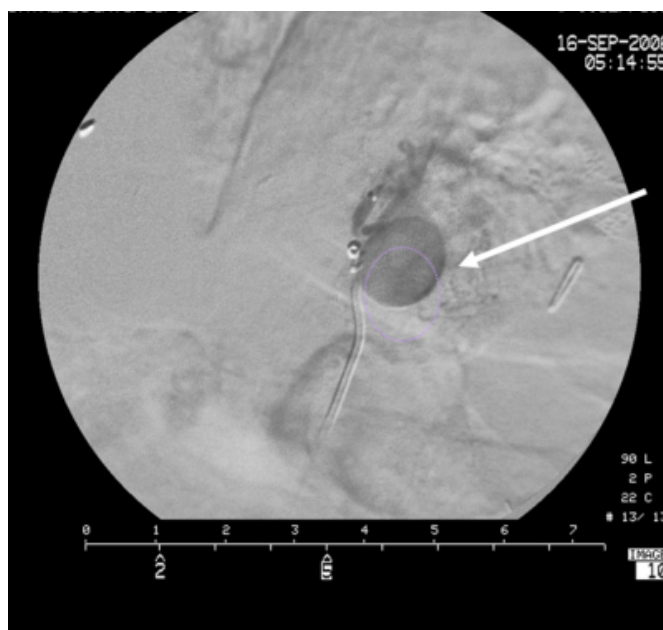


Figure 4

Figure 4: Angiographic embolization of left gastric artery pseudoaneurysm



DISCUSSION

Bleeding pseudoaneurysms in patients with pancreatitis are rare yet lethal complications of pancreatitis (^{1,2}). Three main mechanisms are theorized to account for pseudoaneurysms related to pancreatitis. The first is severe inflammation and enzymatic autodigestion of pancreatic or peripancreatic arteries producing arterial disruption with pseudoaneurysm formation. Second, an established pseudocyst eroding into a visceral artery, thereby converting the pseudocyst into a large pseudoaneurysm. Third, a pseudocyst eroding into the bowel wall with bleeding from the mucosal surface (^{2,9}). In our case, the patient seemed to have a variant of the second mechanism with erosion of the pancreatic pseudocyst into the left gastric artery causing a pseudoaneurysm. The pseudoaneurysm leaked out into the peritoneal cavity (clinically presenting as a Hemoperitoneum) as opposed to leaking into the pseudocyst (which would clinically present as a gastro-intestinal bleed).

The mortality rates related this complication can be as high as 40% depending on the patient's clinical status, size of the pseudoaneurysm, site and characteristics of the bleeding lesion as well as the surgical or angiographic procedure used to control the bleeding (^{1,2}). Left gastric artery pseudoaneurysms such as our case are extremely rare.

Therapeutic options include Angiographic embolization, and surgical ligation of the pseudoaneurysm with or without

pancreatic resection. Some authors have touted the surgical options as better due to the fact that embolization alone fails to address the underlying disease (diseased pancreas). They have also stated that's subsequent surgery is usually indicated^(2,6,7,8). However, multiple studies have documented the efficacy of angiographic embolization in the management of the bleeding pseudoaneurysms related to pancreatitis^(2,3,4,5).

CT angiography using a dynamic bolus is useful and a relatively non-invasive approach for the detection of pseudoaneurysms^(2,7,10). We used this approach to diagnose the presence of the leaking left gastric artery pseudoaneurysm (Figures 1,2).

Contrast angiography also provides improved diagnostic accuracy for detecting pseudoaneurysms^(1,2,3) while also providing for interventional therapeutic option of micro coil embolization⁽²⁾. The reported success of embolization is 79-100%. The reported mortality rate after embolization is 12-33% in patients with acute or chronic pancreatitis^(2,3,4,7). After successful angiographic micro coil embolization, (figure 3,4). Our patient has recovered from the bleeding episode and is currently undergoing rehabilitation therapy.

In conclusion, we report a case of hemoperitoneum resulting from a leaking left gastric artery pseudoaneurysm secondary to pancreatitis. This patient was promptly diagnosed and successfully treated with angiographic micro coil embolization.

References

1. BALACHANDRA, S., SIRIWARDENA, AK: Systemic Appraisal of the Management of the Major Vascular Complications of Pancreatitis. *Am J. Surg.* 2005, 190: 489-495
2. HSU JT, YEH CN, HUNG CF, et al: Management and Outcome of Bleeding Pseudoaneurysm Associated with Chronic Pancreatitis. *BMC Gastroenterology* 2006, 6:3
3. GAMBIEZ LP, ERNST OJ, MERLIER OA, et al: Arterial Embolization for Bleeding Pseudocysts Complicating Chronic Pancreatitis. *ARCH Surg* 1997, 132: 1016-1021
4. BEATTIE GC, HARDMAN JG, REDHEAD D, et al: Evidence for a Central Role for Selective Mesenteric Angiography in the Management of the Major Vascular Complications of Pancreatitis. *Am J. Surg.* 2003, 185: 96-102
5. BERGERT H, HINTERSEHER I, KERSTING S, et al: Management and Outcome of Hemorrhage Due to Arterial Pseudoaneurysms in Pancreatitis. *Surgery* 2005, 137: 323-328
6. BRESLER L, BOISSEL P, GROSDIDIER J: Major Hemorrhage from Pseudocysts and Pseudoaneurysms Caused by Chronic Pancreatitis: Surgical Therapy. *World J. Surg* 1991, 15: 649-653
7. DE PERROT M, BERNEY T, BUHLER L, et al: Management of Bleeding Pseudoaneurysms in Patients with Pancreatitis. *Br J Surg* 1999, 86: 29-32
8. REBER PU, PATEL AG, BAER HU, et al: Acute Hemorrhage in Chronic Pancreatitis: Diagnosis and Treatment Options Including Supraselective Micro-Coil Embolization. *Pancreas* 1999, 18: 399-402
9. YEO CJ, BASTIDAS JA, LYNCH-NYHAN A, et al: The Natural History of Pancreatic Pseudocysts documented by Complicated Tomography. *Surg Gynecol OBSTET* 1990, 170: 411-417
10. BALTHAZAR EJ, FISHER LA: Hemorrhagic Complications of Pancreatitis: Radiologic Evaluation with Emphasis on Ct Imaging. *Pancreatology* 2001, 1:306-313

Hemoperitoneum From A Leaking Pseudoaneurysm Of The Left Gastric Artery Secondary To A Pancreatic Pseudocyst: A Case Report

Author Information

Akella Chendrasekhar, MD, FACS

Department of Surgery, Wyckoff Heights Medical Center

Daniel Perri, DO

Department of Surgery, Wyckoff Heights Medical Center

Percy Erachshaw, DO

Department of Surgery, Wyckoff Heights Medical Center

Addagada C. Rao, MD, FACS

Department of Surgery, Wyckoff Heights Medical Center