

An Atypical Case of Carcinoma of the Rectum

D Belekar, V Dewoolkar, A Desai, J Anam, M Parab

Citation

D Belekar, V Dewoolkar, A Desai, J Anam, M Parab. *An Atypical Case of Carcinoma of the Rectum*. The Internet Journal of Surgery. 2008 Volume 20 Number 1.

Abstract

Rectal cancer is a very common cancer of the gastrointestinal tract in the Western world. It has a moderate incidence in India and its incidence is increasing in the last decade. It has varied presentations and mostly presents with bleeding per rectum or with altered bowel habits. Around 10% of cases present with atypical presentations. We present such an atypical case where the rectal malignancy presented as an ovarian mass in a known case of endometriosis.

CASE HISTORY

A 45-year-old Muslim housewife came with difficulty in passing urine and stools since 2 months on daily basis. Initially, she started having increased frequency of micturition, every half an hour. There was no history of dysuria/pyuria/lithuria/hematuria or retention of urine.

The patient was passing hard stools in small quantities, usually mixed with mucus, but without blood. She had tenesmus and associated dull aching pain in the left iliac fossa, which used to increase with laxatives and to decrease with defecation. She had no vomiting or distension of the abdomen.

Two years back, she complained of having polymenorrhea, for which she underwent dilatation and curettage followed by total abdominal hysterectomy with right salphingo-oophorectomy and partial excision of a left-sided chocolate cyst. Histopathology report of that confirmed the presence of endometriosis. Postoperatively, she had an uneventful recovery except for minor wound infection. She had no major medical illness in the past. She has two children, both full-term normal deliveries. She had no family history of cancer. She eats mixed diet, with regular consumption of red meat.

On examination, the patient's vital parameters were within normal limits (WNL). She had marked pallor and she was obese. On per-abdomen examination, the abdomen was soft and a Pfannenstiel scar of previous surgery was seen. On per vaginal examination (PV), a fixed mass on the posterior portion of the vault was noted. On per rectal examination (PR), the rectal mucosa was free and the mass was

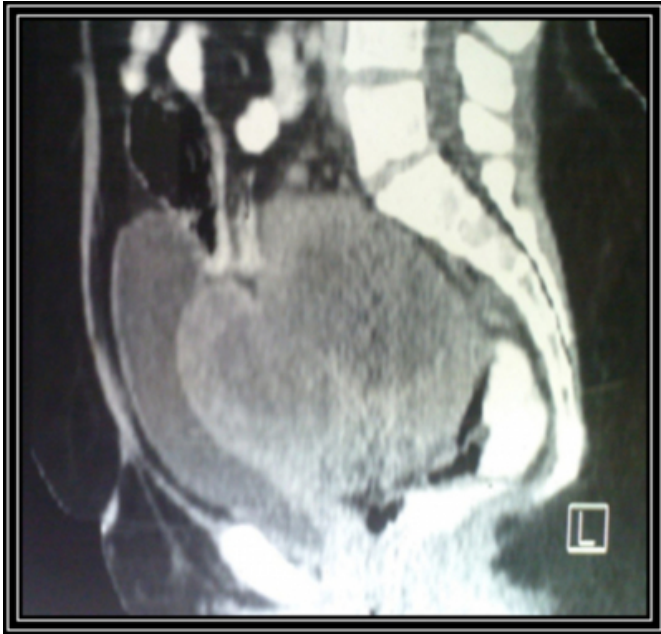
impinging on the upper portion.

Her hemoglobin on admission was 6.8g%. A transfusion of two units of packed red cells was given pre-operatively and her pre-operative hemoglobin reached 9.2g%. Her total WBC count was 12,600/cmm, and her LFT, RFT and BS were WNL. Her CA-125 levels were 14.1 IU/L (WNL). Ultrasonography revealed a mass of 9 x 8 x 8cm within the pelvis with heterogeneous echoes and cystic components seen in it. The left ovary was visualized but could not be differentiated from the lesion. The lesion had normal vascularity and it indented the urinary bladder, suggesting broad ligament fibroid or left ovarian mass or retroperitoneal sarcoma.

CT scan showed a large well-defined peripherally enhancing mass of 11.3 x 9.3 x 10 cm in the pelvis, posterior to the urinary bladder, above the vaginal vault, superiorly up to the sacral promontory. The possibility of a left ovarian neoplasm was suggested. A thickening of the adjacent portion of rectum and sigmoid colon with sub-centimeter satellite nodules on the bladder was noted.

Figure 1

Figure 1: CT scan showing the pelvic growth

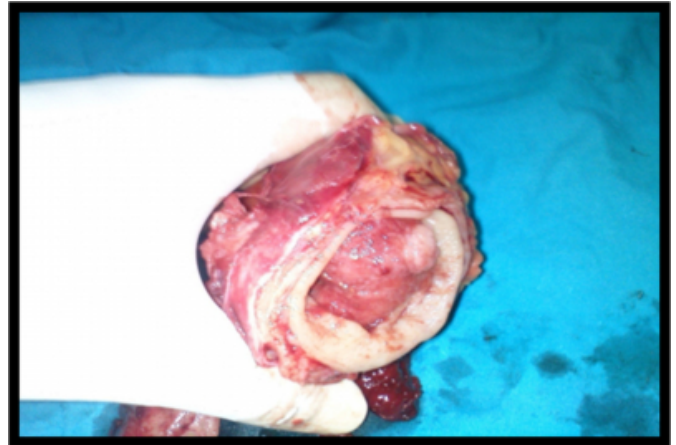

The patient was subjected to exploratory laparotomy with pelvic mass excision and rectosigmoid anastomosis with colostomy. DJ stenting of left ureter was done prior to surgery. There was a mass of about 10 x 11 x 9cm, occupying almost the entire pelvic cavity, pushing the urinary bladder to the right side. The mass involved the rectum and the sigmoid colon, with no plane of cleavage between them. The polypoidal growth of about 3 x 2cm in the proximal rectum was removed along with the rest of the tumor. Lymph nodes posterior to the rectum were sent for histopathology. The distal part of the rectum was anastomosed with the sigmoid colon. A defunctioning transverse loop colostomy was done and matured after 48 hours.

On gross examination, the specimen of rectosigmoid colon measured 10.5cm in length. The external surface showed congestion. On opening, a polypoid growth came out from the rectal end measuring 2.5 x 2 x 2cm. Cut section showed grayish-white mucoid infiltrating up to the serosa. Further well-circumscribed nodular masses measured 12 x 8 x 4cm, 7 x 6 x 3cm and 5 x 7 x 2cm. On cut section, they were solid and cystic. The cysts contained yellowish mucoid material.

Figure 2

Figure 2: Specimen of rectum showing the rectal polyp



On histopathology, the polypoid rectal mass revealed well-differentiated mucin secreting adenocarcinoma (G1) infiltrating through the muscularis up to the serosa (T3). A lot of extracellular mucin was present in the rectal wall. Lymphovascular emboli and perineural invasion were also present. Both proximal and distal margins were free. Reactive lymph nodes were present. The Fallopian tubes were adherent to the mass.

DISCUSSION

Rectal carcinoma is one of the most frequently diagnosed gastro-intestinal malignancies of the western world. In India, rectal carcinoma is estimated to be the third most common digestive cancer after carcinoma of the esophagus and stomach in men and the fourth most common cancer after esophageal, stomach and gallbladder cancer in women.

Incidence of rectal cancer in India is considered moderate to low (4-5/100,000) as compared to Western population (12-14/100,000). The projected incidence in India was 17,445 cases per year in 2001 and has been increasing since.

Adenocarcinomas (98%) comprise most rectal cancers. Other rare rectal cancers include carcinoid (0.1%), lymphoma (1.3%), and sarcoma (0.3%). The incidence of colorectal malignancy is slightly higher in males than in females. The incidence peaks in the seventh decade; however, cases have been reported in young children.

CARCINOMA OF THE RECTUM: TYPICAL SYMPTOMS

Bleeding [5]: This is the most common symptom of rectal cancer and occurs in 60% of patients.

Change in bowel habits: Present in 43% of patients. The

patients may have hypokalemia. Large tumors can cause obstructive symptoms. Tumors located low in the rectum can cause a feeling of incomplete evacuation and tenesmus.

CARCINOMA OF THE RECTUM: ATYPICAL PRESENTATIONS

Partial large-bowel obstruction may cause colicky abdominal pain and bloating and is present in 20% of cases. Back pain is usually a late sign caused by a tumor invading or compressing nerve trunks. Urinary symptoms may occur if the tumor is invading or compressing the bladder or prostate. Pelvic pain: This late symptom usually indicates nerve trunk involvement and is present in 5% of cases. Other presentations include emergencies such as peritonitis from perforation (3%) or jaundice.

SURGICAL TREATMENT: This is the mainstay of management of rectal carcinoma. The various modalities used are [3,4]:

- Trans-anal excision
- Trans-anal endoscopic microsurgery
- Low anterior resection
- Colo-anal anastomosis (anterior resection)
- Abdomino-perineal resection

In our patient, an anterior resection of the rectal growth with colo-rectal anastomosis was done. Although radical resection of rectum is the mainstay of therapy, surgery alone has high recurrence rates. The local recurrence rate for surgery alone is 30-50%. Rectal adenocarcinomas are sensitive to ionizing radiation. Radiation therapy can be delivered preoperatively, intraoperatively or postoperatively with or without chemotherapy [1,2].

Our patient was started on a chemotherapeutic (FOLFOX) regimen: Oxaliplatin IV 85mg/m² [D1]; IV calcium leucovorin 300mg/m² [D1]; IV 5FU 400mg/m² bolus [D1] followed by 2400mg/m² as a 48-hour infusion. The patient will be subjected to radiotherapy after completion of chemotherapy.

FOLLOW-UP: The following follow-up plan is recommended for the patient:

- Clinical examination every 3 months for 2 years. Then every 6 months for 5 years.
- Serum Carcino-embryonic Antigen (CEA) levels: baseline; then every 3 months for 2 years; then every 6 monthly for 5 years.
- Colonoscopy- within 1 year of resection or 6 months if not performed pre-operatively.
- CT scan (abdomen and pelvis): annually for 3 years in stage III patients with high risk of recurrence.
- The serum CEA level in our patient, done post-operatively, was 1.8ng/ml, which was within normal limits.

CONCLUSION

Rectal carcinoma usually presents with bleeding per rectum or with alteration in bowel habits. In our patient, the presentation was like that of a pelvic adnexal mass, probably a recurrent ovarian tumor in a known case of endometriosis. The presence of a rectal polyp was detected on the operation table and resection was performed. Histopathology confirmed malignancy of the rectum with adnexal involvement, but margins of resection were clear. Postoperatively, a chemotherapy (FOLFOX) regime was instituted for the patient. Patient and relatives were educated about colostomy care. The colostomy was functioning without any complications. Two months later, her colostomy was closed extra-peritoneally and now the patient is doing well at follow-up after six months.

References

1. Clinical trial. The evaluation of low dose pre-operative X-ray therapy in the management of operable rectal cancer; results of a randomly controlled trial. *Br J Surg* 1984; 71:21-5.
2. Fisher B, Wolmark N, Rockette H, et al. Postoperative adjuvant chemotherapy or radiation therapy for rectal cancer: results from NSABP protocol R-01. *J Natl Cancer Inst* 1988; 80:21-9.
3. Ruo L, Guillem JG. Major 20th-century advancements in the management of rectal cancer. *Dis Colon Rectum* 1999; 42:563-78.
4. Shelton AA, Wong WD. Colorectal cancer. In: Cameron JL, ed. *Current Surgical Therapy*. 6th ed. St. Louis, MO: Mosby; 1998.
5. Gordon PH. Malignant neoplasms of the rectum. In: Gordon PH, Nivatvongs S, eds. *Principles and Practice of Surgery for the Colon*. 2nd ed. St. Louis, MO: Quality Medical Publishing; 1999.

Author Information

Dnyanesh M. Belekhar, MBBS, MS, FCPS, MNAMS, FMAS, FAIS
Associate Professor, Surgery

V.V. Dewoolkar, MBBS, MS
Dean and Professor of Surgery

Amit A. Desai, MBBS, MS, DNB
Senior Postgraduate Registrar, Surgery

Jay R. Anam, MBBS
Surgery Registrar

Mrunal B. Parab, MBBS
Surgery Resident