

Would The Stem Cell Research Find A Solution To Quadriplegic Patients?

M Takrouri

Citation

M Takrouri. *Would The Stem Cell Research Find A Solution To Quadriplegic Patients?*. The Internet Journal of Health. 2004 Volume 4 Number 1.

Abstract

Background: Long-term culture of embryonic human stem cells (ES Cell), raised the issue of its clinical application, in regeneration of any type of body cells especially neuronal, muscular, pancreatic, cardiac and blood cells.

Case study: A case of chronic quadriplegia is presented, seeking answers regarding possibilities of stem cell therapy.

Discussion: The stem-cell therapy remains within the experimental arena for the foreseeable future. Few studies employing neural stem, in animals, cell grafts have shown convincingly that behavioral recovery can be achieved. Little is known regarding quality control of cultured cells and their safety following transplantation. No patient was treated by stem cell regeneration yet. After solving the ethical issues, and spending huge-money on researches, then it is possible to find right recipe for treatment of similar condition.

INTRODUCTION

Recently, United Kingdom's scientists took the lead in therapeutic cloning by acquiring a license to undertake "somatic cell nuclear transfer" in "Centre of scientists for Life" in Newcastle upon Tyne [1]. This will allow the scientists to use leftover spare embryo from in vitro fertilization (IVF). The chief executive of this centre responded to this occasion by saying:

"This is considered the most innovative cutting edges endeavors to come out from Britain in the last ten years. We cannot underestimate the importance of staying ahead in highly competitive field, which may provide immense long-term benefits for people worldwide."

This is a landmark on the debate among researchers, governments, and societies lobbying groups (with and against) regarding embryonic stem cell's research.

Embryonic stem cells (ES Cells) derived from embryos is hoped to be used to find a cure for certain chronic -now incurables diseases- are touching on forbidden boundaries of abortion. It is hoped that ES Cells would be used to make any cell type in the body, so they can replace cells that have been lost as a result of disease or injury [2]. In the United States of America the debate for such researches is mostly lead by famous personalities [3,4]. Christopher Reeve was a

strong advocate for a breakthrough in the science. He was quoted to have said:

"So many of our dreams at first seem impossible, then they seem improbable, and then when we summon the will, they soon become inevitable." [5].

He has left his appeal and group to lobby for this cause. He developed (Christopher Reeve Paralysis Foundation [CRPF])[6]. He had lived nine years after the horseback riding accident that left him paralyzed from the neck down. Many would continue to work to find treatments and a cure for paralysis. Anyway there is much opposition to that view [7].

The debate focuses firstly on the ethical issue of destroying the first stage of human life of forming embryo, which mounts to abortion, in the presence of possible alternative: adult stem cells [8], and secondly on the high cost needed to perform meaningful research on that field. While the debate continues the possible role of such line of research that may explore new horizons in therapy is not certain [9]. This paper discusses the case of less affluent boy who sustained quadriplegia after a road traffic accident and questions if such cure is possible? Is stem cell research the ultimate hope?

THE CASE

THE STORY OF LIFE AFTER ACCIDENT

A six years old male child was admitted to the surgical intensive care unit (SICU) at King Khalid University Hospital in Riyadh City in 1995 after a road traffic accident. He was traveling with his father in a car. He was seated in the front seat without seat belt. The accident happen when the father tried to avoid collision with another vehicle coming from the left side, but he was halted vigorously, by been trapped between (the car and the high side lane edge) as he described. The child was thrown to the front window. His head hit the front panel and sustained extreme flexion of the neck and lost consciousness. The father was safe.

On arrival to the emergency room he was unconscious, not breathing and in state of collapse due to cardiac arrest. Pupils were fixed dilated and no reflexes. He had a hematoma on the right side and back of the skull (parieto-occipital hematoma). He was intubated with caution, resuscitated and his cardiovascular system resumed activity. A total body computerized scan (CT) scan was performed and the patient was moved to surgical SICU for further treatment, artificial ventilation and skull traction.

The initial total body scans demonstrated the injuries sustained. It was as follow:

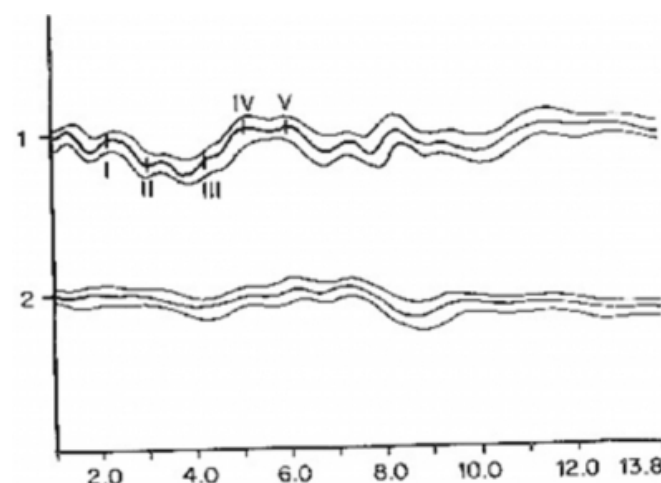
1. Fracture of facial bones.
2. Generalized brain edema; (swollen brain tissue and increased brain tissue water).
3. Large "right side (parietal) scalp" hematoma.
4. Fracture of the posterior element of cervical vertebrae (C) The first and the second
5. A focal flexion deformity at C2-C3 was indicating extreme neck flexion injury.
6. In the middle of the chest cavity around the heart and big vessels extensive internal hemorrhage
7. Multiple bilateral area of lungs consolidation shadows most probably due to contusion.
8. The stomach and intestine were paralyzed and showed dilatation and absence of movement (ileus).
9. The liver and kidneys and bladder were normal.

On day 3 after the accident; the patient started to recover, showing spontaneous eye opening, but he was not following command of nurses and doctor. This demonstrated slight recovery from the initial brain injury. (He had brisk superior reflexes and up-going planter reflexes). The management continued with ventilation and stomach tube feeding.

On day 13 a tracheotomy (opening a hole in the windpipe and inserting artificial tube) was done, by that time the patient had spontaneous eye opening, no response and seems unconscious. He showed no respiratory effort on testing, and spinal withdrawal reflexes in left lower limb. This indicates the presence of major nervous system defects. Fig 1,2,3 explain this finding by absence of peripheral connection to central nervous system.

Figure 1

Figure 1: The tracing of central recordings of evoked potential as recorded from this patient demonstrating the integrity of central nervous system.

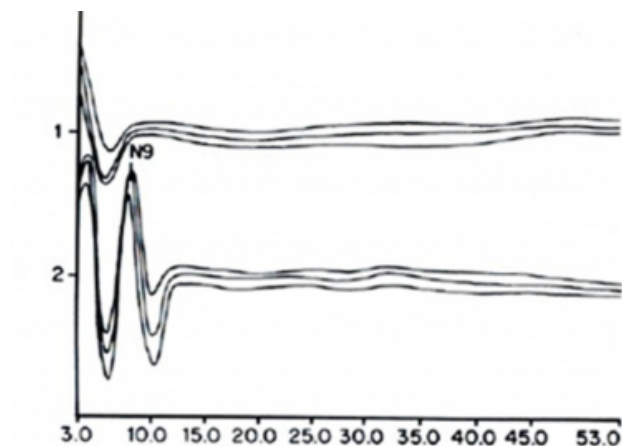


[Axis X is Channels (Trace 1&2). Axis Y is the Latency in milliseconds (ms).

BAEP tracing showing I,II,II,IV & V waves indicating the integrity of the nervous system centrally: Trace 1; C2-A1. Scale 1uV filter 100-1500 Hz. Range 0.41 uV. Latency - 0.05 ± 0.17 uV. Trace 2; C2 A2 Scale 1uV filter 100-1500 Hz. Range 0.41 uV Latency - 0.04 ± 0.13 uV.]

Figure 2

Figure 2: The tracing of median nerve of the arm after evoking a stimulus. It is showing the absence of cortical potential indicating loss of the connection between peripheral and central nervous system



[Axis X is Channels (Trace 1&2). Axis Y is the Latency in milliseconds (ms).

Median N SSEP tracing showing the absence of cortical potential indicating loss of integrity of the connection between peripheral and central nervous system: Trace 1; Fpz-C3 Scale 2.0 uV filter 30-300 Hz. Range 1.41 uV. Latency 1.3 ± 0.42 uV. Trace 2; Fpz-C4 Scale 2.0 uV filter 30-300 Hz. Range 1.34 uV. Latency 1.32 ± 0.32 uV.]

Figure 3

Figure 3: Lateral radiography neck of the patient shortly after admission showing dislocation and subluxation of cervical 2-3

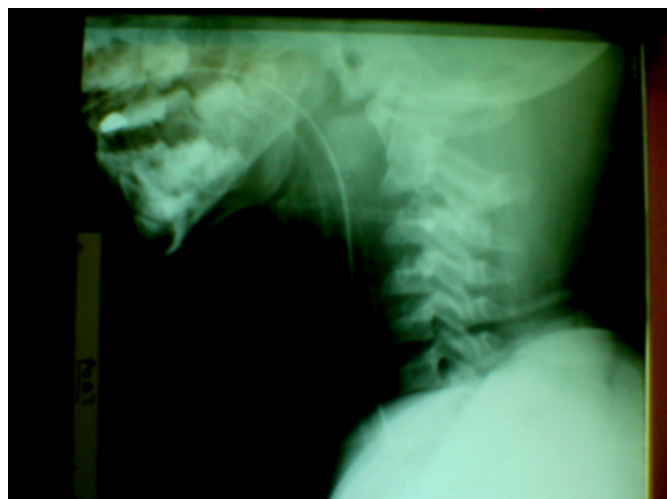
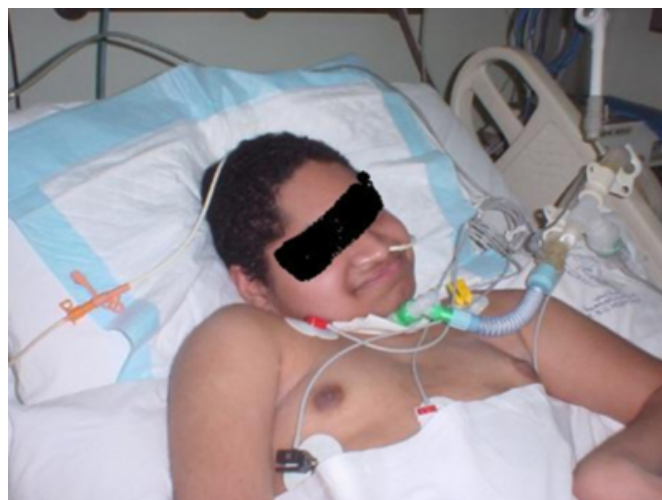
Figure 4

Figure 4: patient on Jan. 15 th 2005 in his hospital bed



On day 17 cervical fixation and stabilization (at spinal vertebrae C2-C3 the site of dislocation Fig 2) was done by the neurosurgeon. During operation the spinal cord was observed and found to be grossly disrupted.

On day 77 the patient was able to show grimaces of the face recognizing his family, smiling, or crying but paralyzed from the neck downward (quadriplegia).

On day 100 the patient showed no improvement regarding limb movement, except spinal reflexes expressed as withdrawal movement of limbs due to coarse movement of shoulder in response to painful stimuli but no arms movements.

On day 120, the first Evoked Potential studies were done. This was obtained by recording the nervous responses to visual (rapid light flickers), auditory (Repeated pulses of sounds applied to the ears) and sensory and motor nerves stimulation of the organs (EYES EARS MUSCLES and PEREPHERAL SENSATION) to elicit the integrity of nervous system connections.

On day 140, the second Evoked Potentials studies were repeated.

On both occasions, evoked potentials demonstrated complete absence of sensory and motor activities in the limbs but not in the head.

Electrical neuronal studies of the phrenic nerve, which make diaphragm do the rhythmic breathing, showed no activity (most probably due to death of nerve cells. This study removed the hope of inserting phrenic nerve stimulator to

create endogenous breathing effort helped by electrical pacing.

Now even after nine years no changes of his paralysis condition.[Fig 4]. He is completely dependent on machine breathing. He does not move any limb and his muscles wasted and his limbs are deformed due to muscle contractures. He is on rehabilitation management of physiotherapy. There are no bedsores and he spent 14 days, during these years, on antibiotics.

DISCUSSION

THE EXTENT OF THE LESION IN THIS CASE

Somatosensory evoked potentials (SSEP) are obtained during peripheral nerve stimulation, surface recordings are made over the scalp overlying the parietal cortex, cervical or lumbar cord and plexus area, and they are very helpful in the assessment of nervous lesion affecting the plexus or dorsal column pathways [11]

They have been used to detect subclinical lesion in Multiple sclerosis and during scoliosis surgery. They have prognostic value in post-traumatic and post-anoxic coma [11,13]. It was used also during operative surgery to predict peripheral nerve injuries or cerebral function during cardiac surgery [14,15,16], or central injuries during neurosurgical resuscitation and operative procedures [17,18,19].

In intensive care evoked potentials were done to predict the permanent vegetative states in brain and spine injuries [20].

The experience gained in using SSEP in operative surgery and anesthesia made it possible to use it to diagnose the presence nerve integrity or injury, in adult and children. The present case, SSEP provided an objective proof of lesion which was anticipated from the history, the clinical course and the finding during surgery. The patient however recovered consciousness, and some coarse movement of the shoulder, and limbs retraction in response to painful stimuli as what was described as spinal reflexes expression [21].

This patient is now in his 14th year of age. No changes in his condition no even the slightest improvement such situation is attributed to total separation of the cord and subsequent nerve atrophy.

THE DREAM

The new development of bio-medicine, made it possible to culture neural stem cells, from the central nervous system (CNS) of mammalian species at many stages of development

[2]. Either embryonic, fetal or adult, these cells have great capacity for self-renewal and can proliferate in the laboratory in response to influence of “mitogenic growth factors” or following genetic modification with “immortalizing oncogenes” [8,10]. Neural stem cells are multipotent since their differentiation will give rise to the principal cellular phenotypes comprising the mature Central Nervous System (CNS): neurons, astrocytes and oligodendrocytes [2,8,9,10].

Neural stem cells can be derived from more primitive embryonic stem (ES) cells cultured from the blastocyst [2,10]. ES cells are considered to be pluripotent [2,6,7,8,9,10]. Since they can give rise to the full cellular spectrum and will, therefore, contribute to all three of the embryonic germ layers: endoderm, mesoderm and ectoderm. However, pluripotent cells have also been derived from germ cells and teratocarcinomas (embryonal carcinomas) and may also give rise to the multiple cellular phenotypes contributing to the CNS. In a recent development, ES cells have also been isolated and grown from human blastocysts, thus raising the possibility of growing autologous stem cells when combined with nuclear transfer technology [8,9].

There is now an emerging recognition that the adult mammalian brain, including that of primates and humans, harbors stem cell populations suggesting the existence of a previously unrecognized neural plasticity to the mature CNS, and thereby raising the possibility of promoting endogenous neural reconstruction [8,9,10]. Such reports have fuelled expectations for the clinical exploitation of neural stem cells in cell replacement or recruitment strategies for the treatment of a variety of human neurological conditions including Parkinson's disease, Huntington's disease, multiple sclerosis, ischemic brain injury and spinal injury. Owing to their migratory capacity within the CNS, neural stem cells may also find potential clinical application as cellular vectors for widespread gene delivery and the expression of therapeutic proteins. In this regard, they may be eminently suitable for the correction of genetically-determined CNS disorders and in the management of certain tumors responsive to cytokines. Since large numbers of stem cells can be generated efficiently in culture, they may obviate some of the technical and ethical limitations associated with the use of fresh (primary) embryonic neural tissue in current transplantation strategies [8,9,10].

While considerable recent progress has been made in terms of developing new techniques allowing for the long-term

culture of human stem cells, the successful clinical application of these cells is presently limited by our understanding of both:

i) the intrinsic and extrinsic regulators of stem cell proliferation and ii) the factors controlling cell lineage determination and differentiation [2,8,9,10]. Although such cells may also provide accessible model systems for studying neural development, progress in the field has been further limited by the lack of suitable markers needed for the identification and selection of cells within proliferating heterogeneous populations of precursor cells [10]. There is a further need to distinguish between the committed fate (defined during normal development) and the potential specification (implying flexibility of fate through manipulation of its environment) of stem cells undergoing differentiation [2,10].

With these challenges lying ahead, the stem-cell therapy is likely to remain within the experimental arena for the foreseeable future. In this regard, few (if any) of the in vivo studies employing neural stem cell grafts have shown convincingly that behavioral recovery can be achieved in the various model paradigms [2]. Moreover, issues relating to the quality control of cultured cells and their safety following transplantation have only begun to be addressed [8,9].

THE POSSIBILITIES

This report represents a documented quadriplegia with no hope of recovery due to evident section of the spinal cord and no apparent recovery of the cut cord (which is clinically expected). It even demonstrates worse trauma than that affected the late Christopher Reeve who demonstrated some improvement in his movement in response to physiotherapy [6]. It was reported that he even was able to breath for short spells on his own. The patient described in this paper did not show any movement or ability to breath without machine. The phrenic nerve - which is the nerve supplying the Diaphragm and allowing the rhythmic contraction of spontaneous respiration – was subjected to nerve conduction studies, which indicated degeneration of that nerve. This would cast gloomy future even with the advances of the technologies since regeneration of nervous tissue should follow the previous nervous connections preserved from the initial trauma. Disruption of the continuity may lead to uncertain results.

The technology of stem cell repair is in its infancy and even when all facts would appear then true hope would be worthy of supporting this evolving technology.

It is summarized in these three statements:

1. The ability of stem cells to both self-renew and differentiate into many different cell types enables these versatile cells to generate and repair tissues and organs.
2. Neural stem cells may have the possibility that they could be used to replace neurons that have been damaged or lost -- perhaps as a result of injury such as trauma or stroke, or through neurodegenerative disorders such as Parkinson's disease. These stem cells can give rise to neurons and their supporting cells (glia) and it is hoped that something akin to neural stem cells in the adult human brain could be stimulated to generate replacement neurons [2,8,9,10].
3. In general, nerve cells in the central and peripheral nervous systems of mammals (including humans) are surrounded by satellite cells that play various roles in neural function. In the central nervous system, these satellite cells are called "neuroglial cells" (glial cells), and they constitute approximately one-half of the volume of the human brain and greatly outnumber neurons in the brain [2].

References

1. Newcastle Scientists get stem cell licence 11/08/2004. Application for a licence to undertake research involving somatic cell nuclear transfer 10/05/2004: Centre for Life - News & Press Releases.htm
2. Rakic P. Neurobiology: On Human Neural Stem Cells. Nature 2004 427:685
3. Flashing S. J. Thinking about Christopher Reeve and the legacy we leave. The Center for Bioethics and Human Dignity 2004
4. Superman' star Christopher Reeve dead at 52. Paralyzed actor was advocate for spinal cord research. CNN_com - 'Superman' star Christopher Reeve dead at 52 - Oct 11, 2004.htm. Last accessed Feb. 10th 2005
5. Reeve C. We must. we can we will [CRPF] <http://www.paralysis.org.news> Last accessed Feb 14th 2005
6. CRPF <http://www.paralysis.org>
7. Cook M. No doubting Reeve's courage but question his convictions. The Age <http://www.theage.com.au/articles/2004/10/13/1097607294194.html?onwclick=true>
8. Josefson D. Adult stem cells may be redefinable (news) BMJ 1999;18:282
9. Ostenfeld T, Svendsen CN. Recent advances in stem cell neurobiology. Adv. Tech. Stand. Neurosurg. 2003; 28:3-89
10. Kim H.T., Kim I.S., Lim S.E., Lee I.S., ark K.I. Gene and cell replacement via neural stem cells. Yonsei Medical Journal 2004, 24 Suppl 32-6
11. Modarres H. EEG and Evoked potentials. Medicine. The

medicine group Juornals Ltd 1996 p24-25.

12. Spiolhlz N.I, Benjamin M.V, Engler G., Ransoff J. Somatosensory evoked potential and clinical outcome in spinal cord injury. p217 in Popp A.J., Borke R.S., Nelson L.R., Kimelberg H.K. (eds) Neural trauma Raven Press, new Yourk 1997.

13. Hickey C, Gugino L.D., Aglio L.S., Mark j.B., Son S.L., Maddi R. Intraoperative somatosensory evoked potential monitoring predicts peripheral nerve injury during cardiac surgery. *Anesthesiology* 1993;78 (1):29-35.

14. Robeyka I.M., coles J.g., wilson G.j., Watanabe T., Taylor M.J., Adler S.f., Mickle D.A., Romaschin A.dD., Ujc H, Burrows F. A, et al. The effect of low-flow cardiopulmonary bypass on cerebral function: an experimental and clinical study. *Ann Thorac surg* 1987;43(4):391-6.

15. Henriksen L., Barry D.I., Rygg I.H., Skovsted P. Cerebral blood flow during early cardiopulmonary bypass in man. Effect of procaine in cardioplegic solutions. *Thorac Cardiovasc Surg* 1986;34(2):116-23.

16. Lam A.M., Manninen P.H., Ferguson G.G. Nantau W. Monitoring electrophysiologic function during carotid

endartrectomy: a comparision of somatosensory evoked potentials and conventional electroencephalogram.. *Anesthesiology* 1991;75(1):15-21.

17. Buchthal A., Belopavolovic M. Somatosensory evoked potentials in cerebral aneurysm surgery. *Eur J Anaesthesiol* 1992;9(6):493-7.

18. Ducey J.P., Lamiell J.M., Gueller G.E. Cerebral electrophysiologic effects of resuscitation with hypertonic saline-dextran after hemorrhage. *Crit Care Med* 1990;18(7):744-9.

19. Manninen P., Paterson S., Lam A.M., Gelb A.w., Nantau W.E. Evoked potential monitoring during posterior fossa aneurysm surgery: a comparison of two modalities. *Can J Anaesth* 1994;41(2):92-7.

20. The Multi-Society Task Force on PVS (Two parts). Medical aspects of the persistent vegetative state. *N Engl J Med* 1994;330(21):1499-508.

21. Bakhamees H. S., El-Dawlatly A.A., Kabiraj M.U., Al-Shwaikhat J.M., Takrouri M.S.M. Evoked potentials in high cervical spine injury- A case report. *M.E.J.Anesth* 1998; 14, 6:451-458

Author Information

Mohamad S. M. Takroui, MB. Ch B. FACA (I).

Professor of Anesthesia, Consultant anesthesiologist, Medical College, King Saud University, King Khalid University Hospital